

Ameliorated effect of green tea extract on cadmium toxicity in liver and kidney of rats

Batool Ibrahim Hussain

Basic Medical Science Department College of Nursing Babylon University
batoolibrahim@yahoo.com

Nadia Hameed AL-Taee

Horticulture and Garden Engineering Department College of Agriculture Al-Qasim
Green University

Nadiahameed@yahoo.com

Abstract :

In the present study , the effect of green tea extract (GTE) on cadmium induced toxicity was studied in albino rats. Four groups of rats were used in this study: group I (control group) fed daily with diets for all time of experiment, group II (Cd – group) received daily 6ppm of cadmium chloride ,group III(GTE + Cd) rats were given daily the cadmium as in group II in adding the GTE at concentration 0.02 gm/kg, group IV(GTE group) received daily 0.02 gm / kg of GTE. Cadmium and GTE were given orally to the rats with diets daily for ten days .

The animals of different groups were weighted after the end of treatment , then all animals were scarified , liver and kidney were excised immediately, weighted by sensitive digital balance and histological preparation would be done to examine the pathological changes by hematoxylin and Eosin staining. Liver index and kidney index would be calculated for comparison them among all groups of this study .

The result of this study demonstrates that Cd has a cytotoxic effects on liver and kidney cells of rats and GTE consumption can effectively reduce the injury of the cells in these tissues .

Key words: Cadmium, Green tea extract, Liver, Kidney

الخلاصة:

هدفت الدراسة الحالية الى معرفة تأثير مستخلص الشاي الأخضر على سمية الكاديوم في الفئران البيض استخدمت أربعة مجاميع من الفئران: المجموعة الاولى (مجموعة السيطرة) تتناول طعامها يوميا طيلة فترة التجربة، المجموعة الثانية (مجموعة الكاديوم) أعطيت 6 ppm من كلوريد الكاديوم ، المجموعة الثالثة (مستخلص الشاي الأخضر + الكاديوم) في هذه المجموعة أعطيت الفئران الكاديوم كما في المجموعة الثانية بالإضافة الى مستخلص الشاي الأخضر بتركيز 0.02gm/kg يوميا ، المجموعة الرابعة أعطيت 0.02gm/kg من مستخلص الشاي الأخضر يوميا. الكاديوم ومستخلص الشاي الأخضر أعطي للفئران عن طريق الفم مع غذائها يوميا لمدة عشرة أيام. بعد انتهاء المعاملة ، جميع الحيوانات وزنت ثم شربت و تم استئصال الكبد والكلية حالا ووزنهم باستخدام الميزان الحساس وأجريت التحضيرات النسجية لفحص التغيرات المرضية باستخدام صبغة الايوسين والهيماتوكسيلين. تم حساب مؤشر الكبد والكلية لغرض مقارنتها بين المجاميع الأربعة لهذه الدراسة .

أوضحت نتائج الدراسة ان للكاديوم تأثيرات سامة على خلايا الكبد والكلية لدى الفئران وان تناول الشاي الأخضر يمكنه وبشكل فعال تقليل الضرر الحاصل في خلايا تلك الانسجة.

الكلمات المفتاحية: الكاديوم، مستخلص الشاي الأخضر، الكبد، الكلية .

Introduction :

Cadmium (Cd) belongs to the group of highly toxic heavy metals, it represents a serious health hazard because it can be absorbed via alimentary tract , penetrates through placenta during pregnancy, and damages membranes and DNA (Kan&Meijer,2007). It causes desquamation of the intestinal mucosa resulting in bloody diarrhea, vomiting (Nordberg,2009) and wide range of biochemical and physiological dysfunction (Bernard *et al.*,1990).

The target organs of Cd toxicity in human after long-term exposure are the kidney and liver (WHO,1992). Cd absorption into the circulation is rapidly taken up by the liver where it is bound to metallothionein (MT) which is then slowly released back into circulation. The Cd - MT complex is freely filtered at the glomerulus and reabsorbed by the proximal tubule (Johri *et al.*,2010). The mechanism which has been proposed to explain the heavy metal-induced toxicity is the disturbance in antioxidant level by generation of reactive oxygen species (ROS) (Gurer and Ercal,2000).

Herbal medicine derived from plant extracts are being increasingly utilized to treat many clinical diseases due to the protective effects of natural antioxidants against chemically induced toxicities (Feri and Higdon, 2003). Tea leaves produce organic compounds that may be involved in the defense of plants against invading pathogens, these metabolites known as polyphenols (Friedman, 2007) which include: catechin, epicatechin, epigallocatechin, theanine and caffeine (Wang and Goodman, 1999). Green tea extract (GTE) was used to promote relaxation (Chuet *et al.*, 1997), decrease blood pressure (Kim *et al.*, 2009a) and protect from lung cancer (Lee *et al.*, 2010). Crespy and Williamson (2004) reported that GTE displays antioxidant and free radical scavenger properties. So we used GTE to investigate the effect of GTE on Cd toxicity in the rats.

Materials and methods

- preparation of green tea extract (GTE) and cadmium chloride (CdCl₂) solution .

Green tea (kindly supplied by Lipton tea company, Inc Englewood cliffs, NJ) was reconstituted in deionized water at concentration 0.02 gm / kg by dissolving the dried leaves of green tea in the warm water at temperature 60 °C for 3 minutes (David, 1999) and the salt of CdCl₂ was prepared at (6 ppm) concentration (Buchet *et al.*, 1980).

- Animal treatment

Sixteen healthy albino rats with weight (235-250g) were isolated in a relatively controlled environment at a temperature of about 25 °C in an animal house. The duration of experiment was 10 days. The rats were randomly divided into 4 groups (4 rats each) as follows: Group I (control group) fed daily with diets for all time of experiment. Group II (Cd – group) received daily 6ppm of cadmium chloride orally by syringe with normal feeding. Group III (GTE + Cd), rats were given daily the cadmium as in group II in addition to the GTE at concentration 0.02 gm / kg orally by syringe. (David, 1999). Group IV (GTE group) received daily 0.02 gm / kg of GTE orally by syringe with normal feeding.

The animals of different groups were weighed after the end of treatment and all animals were sacrificed, immediately livers and kidneys were excised, weighed by using sensitive digital balance, and collected each one alone and fixed in 10 % neutral buffered formalin, dehydrated in ascending grades of ethanol alcohols, cleared in xylol, blocking, cutting at 5µm thickness and stained by haematoxyline – Eosin (H&E) stain (Presnell & Schreiber, 1997) then the specimens were examined by light microscope.

Liver index: liver weight/final body weight x100 and kidney index: kidney weight/final body weight x100 were calculated for comparison between all groups of this study.

Statistical analysis: Complete Randomised Design (CRD) was applied and followed by LSD test to detect differences between groups. A level of $p < 0.05$ was considered statistically significant. (Glantz, 2005)

Results :

Liver sections from the control group rats showed normal hepatic lobules. They formed of hepatocytes radiating from central vein to the periphery of the lobules. Blood sinusoids were situated between cords of liver cells (Fig. 1a). While, liver lobules of cadmium treated rats showed severe and advanced fatty changes, hepatocellular necrosis and inflammatory cellular infiltration was also seen between degenerated hepatocytes (Fig. 1b). The liver of (GTE + Cd) group showed marked improvement in its histological

structure in comparison to the group treated with cadmium alone and represented by the followed : mild hydropic changes and steatosis , but no necrosis , no lymphatic cells infiltration , proliferation of Kupffer cells and binucleated cells that indicate to proliferation and regeneration of hepatic cells (Fig.1e) . No detectable pathological changes showed in the liver of group treated with GTE alone (Fig. 1f) .

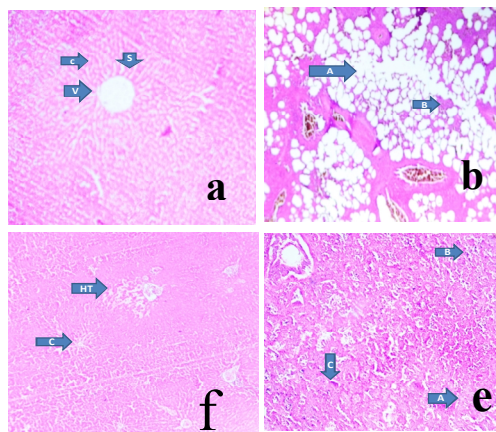


Fig.(1):(a) shows a photomicrograph of a section in the liver of control rat showing normal hepatic lobule formed of central vein (v) and hepatic cells cord (c) around it , separated by hepatic sinusoids(S) X100 . (b) Shows photomicrograph of a section in the liver of cadmium treated rat showing severe fatty changes (A).

The remaining liver tissue shows necrosis with mild lymphocytic infiltration (B) X40 . (e) shows a photomicrograph of a section in liver of (green tea extract + cadmium) treated rat showing mild change compared to the animals given cadmium only. There is no necrosis but mild hydropic changes and steatosis (A), with proliferation of Kupffer cells(B) and regeneration of hepatic cells reflected as binucleated cells(C). There no lymphocytic infiltration x100 . (f) shows a photomicrograph of a section in liver of green tea extract treated rat showing no histopathological changes, central vein(C) , hepatic triad (HT)X40. (H&E stain)

Kidney sections from the control group rats reveal normal histological features , showing glomeruli with lobulated tuft , eosinophilic proximal convoluted tubules and basophilic distal convoluted tubules , (Fig .2 A) . The kidney of albino rats intoxicated with cadmium showed a wide spread of coagulative necrosis which involved both tubules and glomeruli and no nuclei could be identified (Fig.2B) . In the kidney of (GTE + Cd)group ,there is ahydropic change in glomeruli and renal tubules, but the nuclei of the cells in both can be identified , (Fig.2C) . There is no changes in the glomeruli, collecting tubules of medulla but there is very mild change in the renal tubules of the cortex in the kidney of albino rats which treated with GTE only , (Fig. 2E)

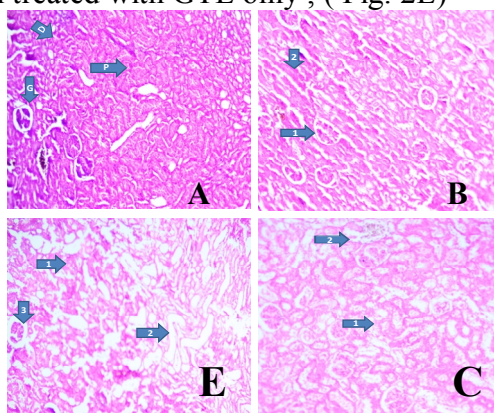


Fig .(2):(A) shows a photomicrograph of a section in the kidney of control rat reveal its normal histological features, showing glomeruli (G) with lobulated tuft, and eosinophilic proximal convoluted tubules (P) and basophilic distal convoluted tubules (D).(B) Shows photomicrograph in the kidney of cadmium treated rat showing wide-spread coagulative necrosis : The pattern of cells death is characteristic of coagulative necrosis in which the dead cells appear as just eosinophilic shadows or ghosts of cells without nuclei. The necrosis involved both tubules and glomeruli: arrow (1) indicate s a necrotic glomerulus , arrow (2) indicates a necrotic tubule; in both no nuclei could be identified .(C) Shows a photomicrograph of a section in kidney of (green tea extract + cadmium) treated rat showing hydropic changes in the renal tubules reflected as vaculation of the cells with increased eosinophilia of the cytoplasm (arrow 1), the glomeruli show the same changes, in both, the nuclei of the cells can be identified (arrow 2). (E) Shows a photomicrograph of a section in kidney of green tea extract treated rat showing very mild change involving the cortex only, these change consist of mild hydropic changes in the renal tubules of the cortex (arrow 1) the collecting tubules of the medulla show no changes (arrow 2) : the glomeruli show no changes (arrow3).(E&H stain X40)

As shown in Fig . (3) , the kidney index , which is the percent of kidney weight at final body weight , was not significantly different among the experimental groups , In contrast, relative liver weight was increased significantly ($p < 0.05$) by cadmium treatment , and GTE consumption with Cd would be diminished significantly ($p < 0.05$) the increase in liver weight which induced by cadmium and there is no significant difference in liver weight between control and GTE group , Fig.(4).

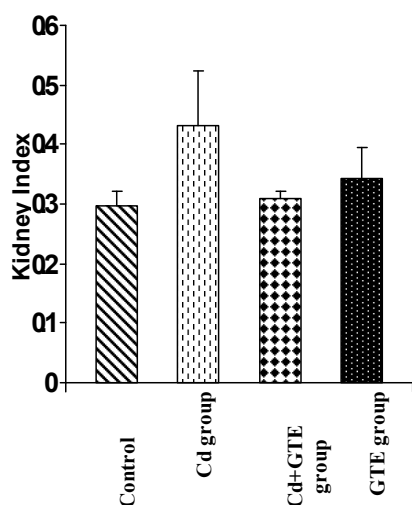


Fig. (3): Mean relative Kidney weight in rats of all groups in this study (Mean±S.E).

Non significant difference

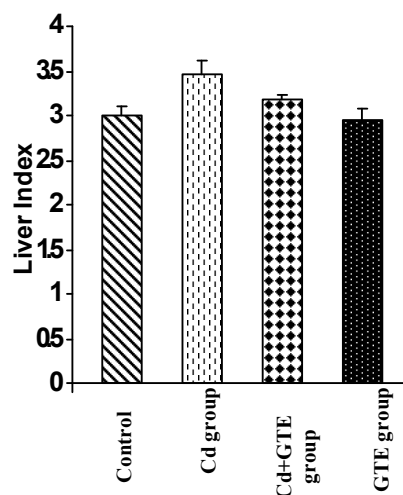


Fig. (4): Mean relative liver weight in rats of all groups in this study (Mean±S.E).

L.S.D_(0.05)=0.137

Discussion :

In the present study sever fatty changes , necrosis of hepatocytes and inflammatory cells infiltration were seen between degenerated hepatocyte in the liver section of cadmium treated group. In kidney section for the same group the histological examination revealed a wide- spread of coagulative necrosis which involved both glomeruli and tubules and the nuclei of them could not be identified . This result is consistent with previous observation showing that cadmium exposure cause albuminuria

and decline in glomerular filtration rate and eventually causing renal failure(Bernard *et al.*, 1990) . This toxic effect of cadmium is mediated by cadmium –metallothionein (Cd- MT) synthesis which induce autoantibodies to (MT) and may be interfere with Cd detoxification (Chen *et al.* , 2006) , other antibodies have also been implicated in the damage of tissue after Cd exposure (Bernard and Lauwerys , 1990) and the mechanism of Cd- MT toxicity was disturbance in antioxidant levels by generation of ROS (Gurer & Ercal , 2000) which have diverse cytotoxic effects , including DNA damage , protein oxidation and lipid peroxidation which many lead to disorganization of cell structure and function then finally induction of cell apoptosis (Rodrigo & Bosco , 2006) .

While, group treated with cadmium + green tea extract showed notable recovery effect of green tea extract against Cd – induced toxicity in the section of liver in comparison to the liver section of cadmium alone , there is a mild hydropic changes and steatosis , without necrosis , with proliferation of Kupffer cells , no inflammatory cells infiltration and binucleated cells , that represent good sign of regeneration (Baldiei *et al.* , 2006) and this result is consistent with previous observations showing that the treatment of mice with green tea caused diminishing in ethanol – induced fat droplets in the liver of these animals (Li *et al.* , 2012) and the treatment of rats with (CCl₄- induced fibrosis for liver + green tea) exhibited the hepatoprotective effect of green tea against CCl₄ – induced necrosis(Mahmoud *et al.*,2012). In the present study the section of kidney for the same group (Cd+ GTE) showed a hydropic changes in both renal tubules and glomeruli but the nuclei of them could be identified , this can be considered as improvement in the histological structure of kidney in the rats which treated with(Cd+GTE) in comparison with kidney section of animals treated with Cd only.This improvement may be due to the effective role of GTE in increasing renal antioxidant enzymes activities (Tabrizi and Mohajeri , 2012) and decreasing the apoptosis in rat kidney tissue (Itoh *et al.* , 2005) . In this study , from the photomicrograph of liver and kidney sections (Fig .1e) and (Fig .2C) respectively , it is clearly the ameliorated effect of green tea was better in liver (mild hydropic changes)than in kidney(hydropic changes) this may be due to two reasons : the first was the accumulation rate of cadmium in kidney is two or three times higher than in liver , so should have two or three times of higher MTconcentration in kidney than found inliver (Pederson & Hylland 2007) , and the second reason was the differential accumulation of green tea in tissues (Khan *et al.* , 2009) , so may be green tea accumulated in liver more than in kidney and green tea able to form complexes with cadmium ions that decrease its lipophilicity and thus its gastrointestinal absorption and these insoluble complexes would be removed from tissues by chelating agents (Patrick ,2006) . In this study , generally the ameliorative effect of green tea extract against Cd – toxicity in both liver and kidney may be due to the consumption of green tea extract was involved in specific adaptive alteration in the improvement of cellular / energy metabolism and antioxidant defense mechanism that was associated with lower lipid peroxidation in the liver and kidney of normal rats (Khan *et al.*,2007 ; Tabrizi & Mohajeri,2012) and finally decrease apoptosis in the tissue (Itoh *et al.*,2005),as well as green tea is responsible for increasing serum phospholipids which are essential membrane components and this increase may facilitate repair and regulations of various membranes after exposure to oxidative stress (Szachowicz- Petelska *et al.* , 2005)

In the present study the treatment of albino rats with green tea extract only didn't cause any pathological change in liver but in the kidney no change in glomeruli and

collecting tubules but a mild hydropic change could be seen in cortex renal tubules only. Another study showed that the supplementation of 500 mg of green tea polyphenols daily to postmenopausal osteopenic women for 24 weeks appeared to be safe particularly in terms of liver and kidney function (Shen *et al.* , 2010) .

The results of this study showed a significant increase in liver index in animals which treated with Cd . This may be due to the role of Cd in decreasing the level of antioxidant by generation of ROS (Gurer and Ercal , 2000) and by thus oxidative stress would be increased which is suggested to be associated with the proliferation and activation of stellate cells and increase collagen production in injured liver (Baroni *et al.* , 1998) . Furthermore , oxidative stress has been shown to increase collagen gene expression (Parola *et al.* , 1993) and then the body weight would be increased , and when the animals were treated with (Cd + GTE) the relative liver weight would be diminished significantly in comparison with liver weight of animals treated with Cd only . This result may be due to the role of GT in inhibition of the proliferation of activated hepatic stellate cells , down regulate the collagen content and expression of collagen (Kim *et al.* , 2009 b) and thus the relative liver weight would be decrease in this group.

It is clearly known , that green tea used with a program of reduced intake of dietary calories to help in weight loss (Westertep – Plantenga *et al.* , 2006) by reduction in serum glucose and cholesterol (Khan *et al.* , 2009) or by stimulation brown fat thermogenesis (Nagao *et al.* , 2005) , but the result of this study revealed that the treatment of albino rats with GTE only didn't reveal any significant difference in liver index in comparison with control group , this may be due to insufficient duration period of this experiment (10 days) for weight lossing .

In conclusion , this study demonstrates that Cd has a cytotoxic effects on liver and kidney cells of rats and GTE consumption can effectively reduce the injury of the cells in these tissues .

References :

- Baldiei , K. ; Mostaghni , A. and Nowroozasl , A. (2006) . Ameliorate Effects of Allium sativum on subclinical lead toxicity in goats. Pak Vetj ; 26(4) : 184-6.
- Baroni , S. ; Dambrosio , L. ; Ferretti , G . and Casini , A . (1998) . Fibrogenic effect Of oxidative stress on rat hepatic stellate cells. Hepatology; 27:720-726.
- Bernard , A. & Lauwerys , R. (1990) . Early markers of cadmium Nephrotoxicity : biological significance and predictive value. Toxicol Environ Chem ; 27 : 65-72
- Bernard , A. ; Roels , H. and Cardenas , A. (1990) . Assessment of urinary Protein 1 and transferrin as early markers of cadmium nephrotoxicity . Br J Ind Med ; 47: 559- 565.
- Buchet , J. ; Roels , H. ; Bernard , A. and Lauwerys , R. (1980) . Assessment of renal function of workers exposed to inorganic lead , cadmium or Mercury vapor. Journal of occupational medicine ; 22 : 741-750.
- Chen , L . ; Lei , L . ; Jin , T. and Nordberg , M . (2006) . Plasma Metallothionein Antibody, Urinary cadmium and renal dysfunction in a Chinese type 2 diabetic Population. Diabetes Care ; 29: 2682- 2687.
- Chu , D .C. ; Kobayashi , k. ; Juneja , R. and Yamamoto , T. (1997) . Chemistry and applications of green tea. Biochim . Biophys. Acta ; 850 : 436-448
- Crespy , V. & Williamson , G. (2004) . A review of the health effects of green tea catechins in vivo animal models . J Nutr ; 134 :3431S –40S

- David , A . (1999) . Ingestion of green tea rapidly decrease prostaglandin E₂ levels in Rectal mucosa in humans . *Cancer Epidemiology* ; 8: 709 – 713.
- Frei , B . and Higdon , J . (2003) . Antioxidant activity of tea polyphenols in vivo : evidence from animal studies . *J Nutr* . ; 133:3275 -84 .
- Friedman , M . (2007) . Overview of antibacterial , antitoxin , antiviral and antifungal activities of tea flavonoids and teas . *Mol. Nutr . Food Res.* ; 51 , 116 – 134
- Glantz, S.A. (2005). *Primer of biostatistics*. 5th ed. P. 208-310. MacGraw, USA.
- Gurer , H . and Ercal , N . (2000) . Can antioxidants be beneficial in the treatment of heavy metals poisoning ? *Free Radic Biol Med* ; 29 (10) : 927-45
- Itoh , Y.; Yasui; T . ; Okada , A . and Tozawa , k . (2005) . Examination of antioxidative effect in renal tubular cells and apoptosis by oxidative stress . *Urol. Res*;33:261-266.
- Johri , N . ; Jacquillet , G . and Unwin , R . (2010) . Heavy metal poisoning : the effect of cadmium on the kidney . *Biometals* ; 23 : 783- 792
- Kan , C.A. and Meijer , G . A . (2007) . The risk of contamination of food with toxic substances present in animal feed . *Anim feed Sci Technol* ; 133: 84 -88
- Khan , S . A . ; Arivarasu , S . and priyamvada , S . (2007) . Influence of green tea on enzymes of carbohydrate metabolism , antioxidant defense and plasma membrane in rat tissues . *Nutrition* ; 23 : 687 – 695
- Khan , S . A . ; Farooq , N . and Khan , S . (2009) . Protective effect of green tea extract on gentamicin – induced nephrotoxicity and oxidative damage in rat kidney . *Pharmacological Research* ; 59: 254-262
- Kim , T . I ; Lee , y . K . ; Park , S . G . and Hong , J . T . (2009 a) . L- theanine , an amino acid in green tea , attenuate beta – amyloid – induced cognitive dysfunction and neurotoxicity : reduction in oxidative damage and inactivation of ERK / P38 Kinase and NFKB pathways . *Free . Rad . Biol . MED* . 47 : 1601 - 1610
- Kim , H.K . ; Yang , T . and Yon Cho , H . (2009 b) . Antifibrotic effects of green tea on invitro and invivo models of liver fibrosis . *World Journal of Gastroentology* ; 15 (41) :5200-5205
- Lee , A . H . ; Liang , W . ; Hirayama , F . and Binns , W . (2010) . Association Between Green tea consumption and lung cancer risk . *Journal of Preventive Medicine and Public Health* ; 43 (4) : 366- 367
- Li , G . ; Ye . Y . ; Kang , J . and Yao , X . (2012) . L . Theanine prevents alcoholic liver injury through enhancing the antioxidant capacity of hepatocytes . *Food and Chemical Toxicology* ; 50 : 363 – 372 .
- Mahmoud, M . ; Fahmy , A . and Auf . M . (2012) . Evaluation of the hepatoprotective effect of green tea extract and selenium on CCl₄ – induced fibrosis . *e-Spen Journal* ; 7 : e 23 – e 29 .
- Nagao , T . ; Komine , Y . ; Soga , S . *et al* . (2005) . Ingestion of a tea rich in catechins leads to a reduction in body fat and malondialdehyde modified LDL in men . *Am J Clin Nutr* ; 80 (1) : 122-129
- Nordberg , G . F (2009) . Historical perspectives on cadmium toxicology . *Toxicol Appl pharmacol* ; 238 : 192 – 200
- Parola , M . ; Pinzani , M ; Casini , A . and Albano , E . (1993) . Stimulation of lipid peroxidation or 4-hydroxynonenal treatment increase procollagen alpha1(1) gene expression in human liver fat –storing cells . *Biochem Biophys Res Commun*

- ;194:1044 -1050
- Patrick , L . (2006). Heavy metals toxicity , the role of free radical damage and the use of antioxidants in the pathology and treatment the toxicity . *Altern Med Res* ; 11(2) 114-27
- Pedersen , H .C. and Hylland , K . (2007) . Metallothionein levels in willow ptarmigan (*Lagopus lagopus*) populations with different natural loads of cadmium . *Eur J Wildl Res* ; 53 : 142-152 .
- Presenell , J .K. & Schreibman , M.P. (1997) . Humason's animal tissue techniques , 5th edn., John Hopkine Univ . press . Balfimore
- Rodrigo , R . and Bosco , C . (2006) . Ploy phenols : comparative studies in human and rodent kidney . Areview . *Comp . Biochem . Physiol . Toxicol . Pharmacol.*; 142 :317 – 327
- Shen , C . ; Chyu , M . ; Pence , B . and Yeh , J . (2010) . Green tea polyphenols supplementation and Tai Chi exercise for postmenopausal osteopenic women :safety and quality of life report . *Bio Med . Center Complementary and Alternative Medicine* ; 10 : 76 .
- Szachowicz – Petelska , B . ; Dobrzynska , I . and Skrzydlewska , E . (2005) . Influence of Green tea on surface charge density and phospholipids composition of erythrocytes membrane in ethanol intoxicated rats . *Cell Biol and Toxicol.*; 21 : 61-70
- Tabrizi , B .A . and Mohajeri , D . (2012) . Phytotherapeutic effect of green tea (*Camellia sinensis*) to induced renal ischemia in rats . *World Journal of Zoology* ; 7 (4) : 279 – 284 .
- Wang , W . and Goodman , M.T. (1999) . Antioxidant property of dietary phenolic agents in human : interaction of protein binding activity . *Nutr. Res .* ; 19: 191- 202
- Westerterp – Plantenga , M . ; Diepvens , K . and Joosen , A.M. (2006) . Metabolic effect of spices , teas and caffeine . *Physiology & Behaviour* ; 89: 85 – 91.
- WHO (1992). International Programme on Chemical Safety , Environmental Health Criteria .135 ,Cadmium – environmental aspect ,Geneva .