

The Use of Peritoneal Flap in The Transabdominal Repair of Vesicovaginal Fistula

Hayder Mahdi AL-Aridy

ABSTRACT:

BACKGROUND:

Vesicovaginal fistula (VVF) represents a significant morbidity in female Urology. Although surgical success is achieved in the majority of cases, a 4 to 35% failure rate occurs when a transvesical or transvaginal approach is used.

OBJECTIVE:

The aim of the present study is to describe our experience and effectiveness of transabdominal repair of vesicovaginal fistula with peritoneal flap interposition.

PATIENTS AND METHODS:

A total of 18 patients with VVF (16 primary, 2 recurrent) were repaired transabdominally with peritoneal flap interposition at Al-Najaf teaching hospital, Iraq, during the period from March 2007 to January 2010. Approaching the bladder transperitoneally with bivalving the bladder which separated from vagina to allow tension free closure in separate layers with interposition of peritoneal flap. The outcome was classified into sealed fistula (cured) and recurrent fistula (failed) and was carried out for all patients by thorough clinical assessment 4 weeks after removal of the catheter.

RESULTS:

The mean age was (39.33 ± 10.19) years (range 25-62) and the parity ranged from 1 to 13 (mean 5.38 ± 3.46). (10) patients (55.55%) had VVF due to obstetric causes. (7) patients (38.88%) had VVF due to gynecologic causes. (1) patients (5.55%) had VVF due to iatrogenic causes. The size of the fistula ranged from 1 cm to 12 cm (mean 3.94 ± 2.65). The vesicovaginal fistula was successfully corrected in all patients at the first attempt. No significant bladder dysfunction or decrease in bladder capacity was seen after repair.

CONCLUSION:

A peritoneal flap for transabdominal repair of vesicovaginal fistula is safe and achieves excellent functional results. Although a high success rate of repair, we should focus attention on strategies of prevention.

KEY WORDS: vesicovaginal fistula, peritoneal flap, transabdominal repair

INTRODUCTION:

Vesicovaginal fistula represents a significant morbidity in female urology. Continual wetness, odour and discomfort cause serious social problems⁽¹⁾.

The true incidence of vesicovaginal fistulas is unknown but it has been estimated at 0.3% to 2%.^(2,4) Although historically and even today in developing countries the main cause is obstructed labour, in countries with developed healthcare systems 90% of cases are caused by surgical trauma after gynaecological procedures. In the remaining

10% the causal factors are irradiation, locally advanced pelvic tumours and pelvic pathologies of benign origin (e.g. inflammation, foreign bodies)⁽⁵⁾.

The first successful surgical repair of a vesicovaginal fistula is most often credited to James Marion Sims⁽⁶⁾. Despite the several reports of successful fistula repairs prior to his work, those descriptions were crude at best. It was Sims' innovation to use silver wire as suture material, avoid the use of electrocautery, and utilize postoperative bladder drainage with a urethral catheter⁽⁷⁾.

VVF may be repaired through a transvaginal or transabdominal (transvesical) approach. Each approach has merits, depending on the particular circumstances of the fistula, and excellent outcomes can be expected with both approaches⁽⁸⁾. Although

Dept of Urology, Medical College, Kufa University, Najaf, Iraq.

factors such as size, location, and need for adjunctive procedures often have an impact on the choice of approach, the most important factor is commonly the experience of the operating surgeon. Thus, there is no preferred approach for all fistulas, and the "optimal" approach to the uncomplicated postgynecologic VVF is usually the one that is most successful in the individual surgeon's hands^(9,10).

In expert hands, the results of VVF repair are equivalent using either an abdominal or vaginal approach⁽¹¹⁾. Although the surgical results are mainly related to the etiology of the fistula and the experience of the surgeon, success is achieved in 65 to 96% of cases^(12,22). The key to successful repair of VVF lies in the classic principles defined by Couvelaire in 1953, "good visualization, good dissection, good approximation of the margins and good urine drainage"⁽²³⁾.

The interposition of a healthy, well-vascularized tissue flap during VVF repair may be beneficial under certain circumstances. Tissue flaps are especially helpful in the setting of a complex fistula, such as a fistula that has recurred after a prior attempt of repair, a fistula related to previous radiotherapy, an ischemic or obstetric fistula, a large fistula, and a fistula associated with a difficult or tenuous closure because of poor tissue quality⁽⁸⁾. For those VVFs repaired transvaginally, a labial fat pad (Martius flap) or a peritoneal flap is most commonly used. From a transabdominal approach, omentum or peritoneum is often used as an interpositional flap⁽²⁴⁾.

The objective of this study is to describe our experience and to document the outcome of transabdominal VVF repair with interposed peritoneal flap in our center.

PATIENTS AND METHODS:

From March 2007 to January 2010 a total of 18 patients suffering from vesicovaginal fistula were referred to our department. This study was conducted at Al-Najaf teaching hospital, Najaf, Iraq.

Preoperative evaluation. All patients were evaluated preoperatively by history and physical examination. Biochemical tests for renal function, CXR, and abdominal US. Cystography (Figure 1) and cystoscopy were performed to determine the location, size and number of fistulous tracts.

Only for fistulas Iatrogenic there was a trial of conservative therapy done using an indwelling urethral catheter +anticholinergic drugs for 6 weeks.

Procedure of repair: The patient is placed in trendelenberg position. The abdomen is opened via

an infraumbilical midline/Pfannenstiel incision and under general /spinal anesthesia. Vulvar and vaginal cleaning was performed. The peritoneum is opened to approach the posterior surface of bladder. The bowel is gently packed with sponges before the cystostomy. After cystostomy incision, the ureteric orifices and fistula(s) were identified (Figure 2). The bladder was opened along the sagittal plane starting on the anterior wall, successively incising the superior and posterior walls until the fistulous orifice (bivalving of the bladder) was reached (Figure 3). The bladder was isolated from the vagina by blunt ±sharp dissection with care to ensure that the vesical and vaginal layers maintained good vitality. The vaginal defect was sutured with 1/0 chromic catgut sutures (Figure 4). Both ureters were catheterized using nasogastric tubes 5-8 Fr throughout the procedure to avoid their injury. We covered the vaginal suture line by nearby peritoneal flap from peritoneum covering bladder dome or lateral pelvic peritoneum, to be interposed between bladder and vagina (Figure 5). Then the bladder was closed with a 2/0 chromic catgut in continuous running fashion beginning at the base of the incision through the full muscle layers and imprecated with a second layer with interrupted sutures. The mucosal membrane with continuous 4/0 plain catgut stitches. The abdominal cavity was closed with external drainage.

A suprapubic cystostomy tube and ureteric stents were fixed at the end of the procedure. The perurethral catheter is removed after 2 weeks and the suprapubic catheter is removed after 3 weeks.

Intraoperative blood loss was insignificant and none of the patients required postoperative blood transfusion.

Postoperatively the vagina is packed with iodine soaked gauze. The vaginal pack is removed on postoperative day (1). Uninterrupted bladder drainage and avoidance of bladder spasms during the postoperative period are imperative for repair success. We recommend suprapubic tube drainage for 3 weeks postoperatively. Anticholinergic medications are also helpful in reducing number and duration of bladder spasms. Patients are advised to avoid the use of tampons

and refrain from sexual activity for 2 months postoperatively. Elective caesarean section was advised for future pregnancy.

All patients were subjected to parenteral antibiotic treatment using (cefotaxime 1g x 3 plus metronidazole 500mg x 3) started 1 hour

preoperatively and lasted 7 days postoperatively. Povidone iodine douches were applied daily for 5 days postoperatively. The ureteric stents were removed 7 days postoperatively. Oral antibiotics are continued until the catheters are removed and anticholinergics are administered as

needed. Patients are followed at 4 weeks and 6 months, and then are requested to return in need. The outcome was classified into sealed fistula (cured) and recurrent fistula (failed) and was carried out for all patients by thorough clinical assessment 4 weeks after removal of the catheter.

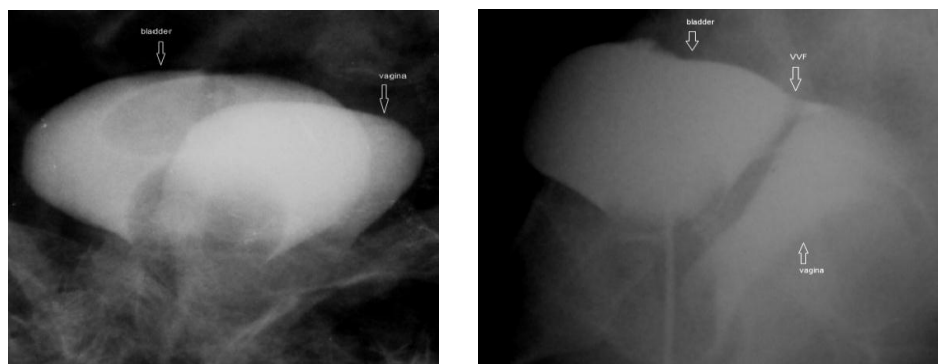


Figure 1 : Cystogram demonstrating a VVF. A, Anteroposterior view. The contrast agent is seen opacifying and outlining the vagina superimposed on the bladder. B, Lateral image demonstrates a post-hysterectomy VVF.

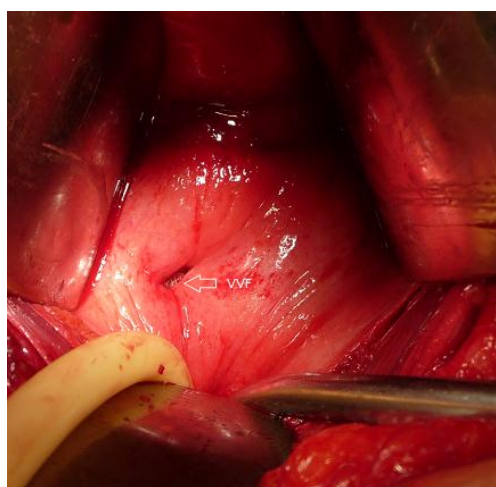


Figure 2 : Intraoperative picture shows a small VVF in a case of post-hysterectomy VVF.

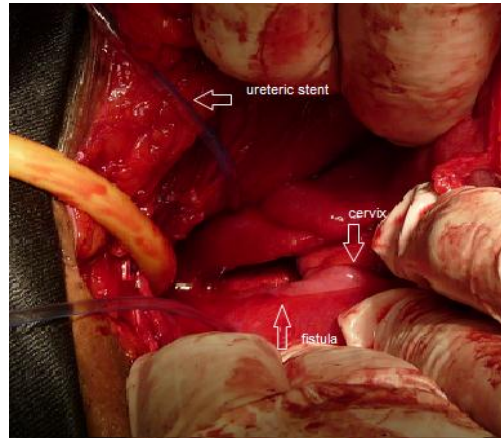


Figure 3:Intraoperative picture shows a large VVF in a case of Postobstructive Labor VVF.the ureteric stents advances through ureteric orifices.

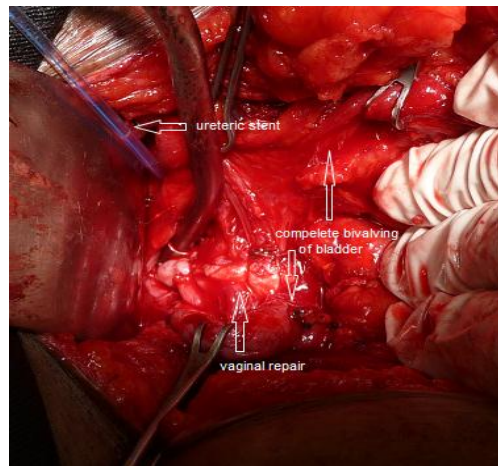


Figure 4:Intraoperative picture shows that the bladder opened in the midline to the level of fistula with repair of vaginal defect.

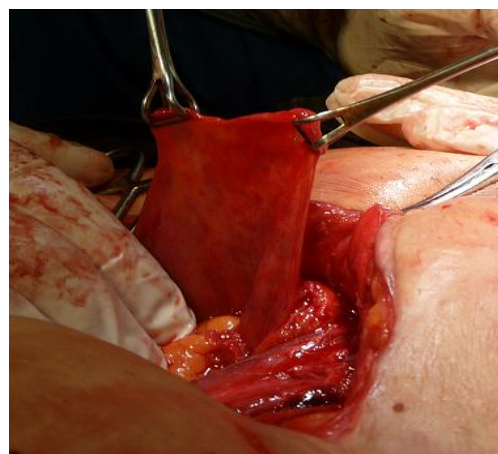


Figure 5:The peritoneal flap was harvested to be interposed in between the two suture lines.

RESULTS:

The mean age was (39.33 ± 10.19) years (range 25-62) and the parity ranged from 1 to 13 (mean 5.38 ± 3.46). (10) patients (55.55%) had VVF due to obstetric causes. (7) patients (38.88%) had VVF due to gynecologic causes. (1) patients (5.55%) had VVF due to iatrogenic causes. The size of the fistula ranged from 1 cm to 12 cm (mean 3.94 ± 2.65). Two patients failed previous repair. These postoperative fistulae occurred after abdominal hysterectomy in 7 patients, 3 patients had fistulae after a Caesarian section+hysterectomy, 2 patients had fistulae after a Caesarian section and 5 patients had VVF following manipulation of obstructed labour. One patient developed VVF following endoscopic intervention of intramural ureteric stone. Table 1, Summarizes causes of VVF.

Of the 18 patients 2 (11.11%) had undergone 1 or more previous surgical attempts at fistula repair at other centres before referral. All patients presented with urinary loss through the vagina, and the interval between the onset of leakage and final surgical correction ranged from 8 weeks to 9 years (mean 17.61 ± 31.67 months). One case had vesical calculus (2 x 3.5 cm). In all cases the operation was delayed for at least 2-3 months between diagnosis and repair of the fistula to allow improvement of local inflammatory changes.

All patients completely continent (cured). No failure. There was no major intraoperative complication. Minor early postoperative complications occurred in the form of mild gross hematuria in (60%).

Table 1: Causes of VVF

Causes of the VVF	Number of patients	Total (%)
Obstetric causes:		10(55.55%)
1. Difficult vaginal delivery	5(27.77 %)	
2. Caesarean section+hysterectomy	3(16.66 %)	
3. Caesarean section	2(11.11 %)	
Gynecologic causes:		
Abdominal hysterectomy	7(38.88 %)	7(38.88 %)
Iatrogenic:	1(5.55%)	1(5.55%)

DISCUSSION:

Vesicovaginal fistulas always represent a distressing medical condition for the patient and demand much attention⁽²⁵⁾.

The 2 most controversial aspects of surgical repair of vesicovaginal fistula are the timing of surgery and surgical approaches⁽²⁶⁾. Various surgical techniques for VVF repair have been described. Fistulas may be successfully repaired with an abdominal, vaginal or combined approach⁽²⁷⁾. Whether the fistula surgeon chooses, either of the approaches, several important factors certainly affect the results. A tension-free closure is essential. Furthermore, adequate blood supply to the layers reconstructed should be aimed for⁽²⁸⁾.

The choice of approach usually depends on surgeon preference and experience^(11,20,29). By tradition, most gynaecologists have repaired vesicovaginal fistulae

via the vaginal route^(11,20,30-33), while urologists mostly have tended to favour abdominal repair^(23,25,34-36).

The abdominal approach, gives an optimal exposure of the fistula area through the bladder, and additionally facilitates mobilization of omentum or peritoneum for interposition in the repair⁽²⁷⁾. The transperitoneal suprapubic technique provides wide mobilization of the bladder and vaginal wall, complete removal of devitalized scar tissue, and efficient closure of the healthy layers without tension⁽²⁵⁾.

The most frequently used abdominal approach nowadays is the O'Connors bivalve technique⁽¹⁴⁾. The success rate has varied between 75-95% with these various techniques^(6,20,37-42). The fundamental treatment principles for VVF repair (adequate exposure, tension-free approximation of the fistula edges, non overlapping suture lines, good hemostasis,

watertight closure and adequate postoperative bladder drainage) can be achieved through both, vaginal and abdominal route, depending upon the surgical experience⁽⁴³⁾.

Conservative measurements, such as catheter drainage and/or cauterization of the fistula tract, are reserved for fistulas less than 5 mm. in otherwise healthy tissue⁽⁴⁴⁾. In our study, we try a conservative measures in Iatrogenic fistula by urethral catheter and (oxybutynin chloride 5 mg 3 times daily) for 6 weeks, but fail to heal.

The ideal interval between the onset of the fistula and surgical repair is controversial. Some authors prefer delayed closure⁽³⁹⁾ while others state that early intervention is safe⁽³³⁾. In the present study, we delayed the operation for up to 2-3 months before closure.

Several factors support delaying the closure of postoperative fistulae for about 3 months. This probably ensures good blood supply and minimizes oedema and acute local inflammation⁽²⁷⁾. In our series, all repairs were done late according to the classical opinion related to repair timing to allow the surgical inflammatory reaction to subside. Regardless the surgical approach to VVF, the key to postoperative management is the maintenance of a dry, uninfected suture line. For this reason most authors recommend the use of antibiotics for a prolonged period after surgery, usually until all catheters are removed^(45,46). Temporary urinary diversion may be accomplished by suprapubic and/or transurethral drainage. Most authors recommend a period of 10 days to 2 weeks⁽¹⁵⁾ with continuous bladder drainage via a urethral Foley catheter. A high fluid input and output must be maintained until the urine is clear of blood by a continuous bladder drainage after 2 weeks.

In modern urological practice 90% of cases are caused by inadvertent injury to the bladder during surgery,⁽⁴⁷⁾ with gynecologic procedures the most common culprit. With hysterectomy accounting for 75% of fistulas,^(5,47) During hysterectomy bladder injury leading to fistula formation occurs when a cystotomy is made either during aggressive dissection of the uterus and cervix from the bladder, or when clamps or sutures are inadvertently placed into the bladder wall, causing necrosis. In developing countries, prolonged obstructed labor is responsible for the overwhelming majority of VVF⁽¹¹⁾.

We prefer not to excise the fistula tract for a number of reasons. Tract excision enlarges the fistula and may cause bothersome bleeding. Electrocautery to

control bleeding can lead to tissue necrosis and compromise repair. Also, excision of a tract in close proximity to the ureteral orifices may require ureteral reimplantation⁽⁴⁴⁾.

Interposition can be achieved by either routes. Many tissues have been used, those most often being peritoneal flaps^(19,24), omental flaps^(48,49), bulbocavernosus fibropatty or Martius flaps⁽⁵⁰⁻⁵²⁾.

The peritoneal flap, described in the abdominal approach in 1974 by Eisen et al⁽²⁴⁾ who report a success rate 90% in 29 patients. Also transvaginally used in the repair of VVF by Raz et al⁽¹⁹⁾ in 1993, the success rate was 82% in 11 patients. A later study from the same institution reported on the use of peritoneal flaps transvaginally in 83 patients, of whom 80 were cured after the first operation (Eilber et al⁽⁴⁴⁾, 2003). In our study, we found it simple to cover the vaginal suture line by nearby peritoneum covering bladder dome or lateral pelvic peritoneum. Our approach has given us 100% success in terms of achieving continence.

Primary vesical calculus formation after VVF is rare. the probable cause of stone formation was crystal precipitation over contaminants from the vagina, such as mucoid secretions and/or desquamated vaginal epithelium associated with bacteriuria and stagnant residual urine in the bladder. Other causes include a foreign body and indwelling catheters⁽⁵³⁾. D. Dalela et al suggest in his study treatment in two stages but in our study we did repair in single stage without complication.

Recently laparoscopic VVF repairs are gaining importance⁽⁵⁴⁾. Consensus is emerging that laparoscopic repair of VVF is feasible and efficacious.

Recently, large fistulas are treated by free bladder mucosal autograft with good results^(55,56) while, Mckay⁽⁵⁷⁾ reported successful repair of small VVFS by transurethral suture cystography technique. also the use of ND-YAG laser welding⁽⁵⁸⁾ for closure of small VVF and endoscopic injection of fibrin glue⁽⁵⁹⁾ for sealing of VVF has been reported.

CONCLUSION:

A peritoneal flap for transabdominal repair of vesicovaginal fistula is safe and achieves excellent functional results. We recommend the use of peritoneal flap in all transabdominal repair of VVF to achieve maximum results. Although a high success rate of repair, we should focus attention on strategies of prevention. Such strategies include early recognition of obstructed labor, meticulous surgical

care during gynaecological operation and minimize Iatrogenic injury to the bladder.

REFERENCES:

1. I . Romics, Zs. Kelemen and Zs. Fazakas. The diagnosis and management of vesicovaginal fistulae. *BJU International* 2002;89: 764-66.
2. Thompson, J. D.: Vesicovaginal and urethrovaginal fistulas. In: Te Linde's Operative Gynecology, 8th ed. Edited by J. A. Rock and J. D. Thompson. Philadelphia: J. B. Lippincott, 1997; chapt.41: 1175-1205.
3. Petri, E. and Friedberg, V.: Vaginaler oder abdominaler Verschluss von Blasenscheiden-fisteln. *Gyna'kologe*, 1983; 16: 231.
4. Harkki-Siren, P., Sjoberg, J. and Tiitinen, A.: Urinary tract injuries after hysterectomy. *Obstet Gynecol*, 1998;92:113.
5. Lee RA, Symmonds RE, William TJ. Current status of genital-urinary fistula. *Obstet Gynecol* 1988; 72: 313-9.
6. Sims JM. On the treatment of vesicovaginal fistula. *Am J Med Sci* 1852;23:59.
7. Carson Wong, M.D., PO N. Lam, M.D., and Vincent R. Lucente, M.D. Techniques in Endourology Laparoscopic Transabdominal Transvesical Vesicovaginal Fistula Repair* *Journal Of Endourology* ,April 2006; 20: 240-44.
8. Walsh, c; Retik, B; Vaughan, E and Wein, J..Campbell's Urology(9th edition) (2009): chapter19, Urinary Tract Fistula. USA .pages 2331.
9. Gerber and Schoenberg, 1993. Gerber GS, Schoenberg HW: Female urinary tract fistulas. *J Urol* 1993;149:229-36.
10. Akman et al., 1999. Akman RY, Sargin S, Ozdemir G, et al: Vesicovaginal and ureterovaginal fistulas: A review of 39 cases. *Int Urol Nephrol* 1999; 31:321-26.
11. Blaivas, J. G., Heritz, D. M. and Romanzi, L. J.: Early versus late repair of vesicovaginal fistulas: vaginal and abdominal approaches. *J Urol*, 1995;153: 1110.
12. Goodwin, W. E. and Scardino, P. T.: Vesicovaginal and ureterovaginal fistulas: a summary of 25 years of experience. *J. Urol.*,1980;123:370.
13. Marshall, V. F.: Vesicovaginal fistula on one urological service.*J. Urol.*,1979;121:25.
14. OConor, V. J., Sokol, J. K., Bulkley, G. J. and Nanninga, J. B.:Suprapubic closure of vesicovaginal fistula. *J. Urol.*,1973;109:51.
15. Staskin, D. R.: Vesicovaginal fistula. In: Urologic Surgery. Edited by J. F. Glenn. Philadelphia: J. B. Lippincott Co., 1991;chapt.44:479.
16. Tancer, M. L.: The post-total hysterectomy vesicovaginal fistula.*J. Urol.*,1980;123: 839.
17. Demirel, A., Polat O., Bayraktar, Y., Giil, O. and Okyar, G.:Transvesical and Transvaginal reparation in urinary vaginal fistulas. *Int. J. Urol. Nephrol.* 1993;25:439.
18. Kristensen, J. K. and LoserG.: Vesicovaginal fistulas: The transperitoneal repair revisited. *Scand. J. Urol. Nephrol.*, suppl1994;101:157.
19. Raz, S., Bregg, K. J., Nitti, V. W. and Sussman, E.: Transvaginal repair of vesicovaginal fistula using a peritoneal flap. *J. Urol.*, 1993;150:56.
20. Brandt, F. T., Lorenzato, F. R. and Albuquerque, C. D.: Treatment of vesicovaginal fistula by bladder mucosa autograft technique. *J. h e r . Coll. Surg.*, 1998;186:645.
21. Ayhan, A., Tuncer, Z. S., Dogan, L., Pekin, S. and Kisman, H.A.:Results of treatment in 182 consecutive patients with genital fistulas. *Int. J. Gynaec. Obst.*, 1995;48:43.
22. Wein, A. J., Malloy, T. R., Carpinello, V. L., Greenberg, S. H. and Murphy, J. J.: Repair of vesicovaginal fistula by a suprapubic transvesical approach. *Surg., Gynec. & Obst.*, 1980;150:57.
23. Couvelaire R. Reflections on a personal statistics of 136 vesicovaginal fistulas. *J Urol Medecale Chir* 1953;59:150-60.
24. Eisen et al., 1974. Eisen M, Jurkovic K, Altwein JE, et al: Management of vesicovaginal fistulas with peritoneal flap interposition. *J Urol* 1974; 112:195-98.
25. Luciano J. Nesrallah,* Miguel Srougi And Ruben F. Gittes The O'Conor Technique: The Gold Standard For Supratigonal Vesicovaginal Fistula Repair, *J Urol* February 1999; 161:566-68.
26. Mohsen Ayed, Rabii A El Atat, Lotfi Ben Hassine, Mohamed Sfaxi, Mohamed Chebil And Saadoun Zmerli Department of Urology, Charles Nicolle Hospital, Tunis, Tunisia Prognostic factors of recurrence after vesicovaginal fistula repair, *international Journal of Urology* ,2006;13:Issue 4: 345-49.

27. Rene´ Sotelo, Mirandolino B. Mariano, ALejandro Garcı´A-Segui, Rinci Dubois, Maximiliano Spaliviero, Wartan Keklikian, John Novoa, Henry Yaime And Antonio Finelli: Laparoscopic Repair Of Vesicovaginal Fistula J Urol, May 2005; 173: 1615–18.
28. Niels C. Langkilde, Torsten K. Pless, Finn Lundbeck and Benni Nerstrøm: Surgical Repair of Vesicovaginal Fistulae A Ten-year Retrospective Study: Scand J Urol Nephrol, 1999; 33: 100–3.
29. Phipps, J.: Laparoscopic repair of posthysterectomy vesicovaginal fistula. Two case reports. Gynecol Endosc, 1996; 5: 123.
30. Elkins TE. Surgery for the obstetric vesicovaginal fistula: a review of 100 operations in 82 patients. Am J Obstet Gynecol 1994; 170: 1108–20.
31. Collins CG, Pent D, Jones FB. Results from early repair of vesico-vaginal fistulas with preliminary cortisone treatment. Am J Obstet Gynecol 1960; 80: 1005–12.
32. Tancer ML. Observations on prevention and management of vesicovaginal fistula after total hysterectomy. Surg Gynecol Obstet 1992; 175: 501–6.
33. Wang Y, Hadley HR. Nondelayed transvaginal repair of high lying vesicovaginal fistula. J Urol 1990; 144: 34–6.
34. Blandy JP, Badenoch DF, Fowler CG, Jenkins BJ, Thomas NW. Early repair of iatrogenic injury to the ureter or bladder after gynecological surgery. J Urol 1991; 146: 761–5.
35. O'Connor VJ. Review of experience with vesicovaginal fistula repair. J Urol 1980; 123: 367–9.
36. Bissada NK, McDonald D. Management of giant vesicovaginal and vesicourethrovaginal fistulas. J Urol 1983;130: 1073–5.
37. Hodges AM. The Mitrofanoff urinary diversion for complex vesicovaginal fistulae: Experience from Uganda. BJU Int 1999;84:436-9.
38. Arrow Smith S, Hamlin EC, Wall LL. Obstructed labor injury complex: Obstetric fistula formation and the multifaceted morbidity of maternal birth trauma in the developing world. Obstet Gynecol Surv 1996;51:568-74.
39. McKay HA. Vesicovaginal fistula repair: Transurethral suture cystorrhaphy as a minimally invasive alternative. J Endourol 2004;18:487-90.
40. Ou CS, Huang UC, Tsuang M, Rowbotham R. Laparoscopic repair of vesicovaginal fistula. J Laparoendosc Adv Surg Tech A 2004;14:17-21.
41. Martius H. Die operative Wiederherstellung der vollkommen fehlenden Harnrohre und des Schliessmuskels derselben. Zentralbl Gynakol 1928;52:480.
42. Iselin CE, Aslan P, Webster GD. Transvaginal repair of vesicovaginal fistulas after hysterectomy by vaginal cuff excision. J Urol 1998;160:728-30.
43. Rakesh Kapoor, MS Ansari, Pratipal Singh, Parag Gupta, Naval Khurana, Anil Mandhani, Deepak Dubey, Aneesh Srivastava, Anant Kumar, Management of vesicovaginal fistula: An experience of 52 cases with a rationalized algorithm for choosing the transvaginal or transabdominal approach Indian journal of urology 2007 ;23 , Issue : 372-76.
44. Eilber et al., 2003. Eilber KS, Kavalier E, Rodriguez LV, et al: Ten-year experience with transvaginal vesicovaginal fistula repair using tissue interposition. J Urol 2003; 169:1033-36.
45. Cruikshank SH. Early closure of posthysterectomy vesicovaginal fistulas. South. Med. J. 1988; 81: 1525.
46. Turner-Warwick R. Urinary fistulae in the female. In: Walsh PC, Gittes RF, Perlmutter AD, Stamey TA . *Campbell's Urology*, 5th edn. W.B. Saunders Co., Philadelphia, 1986; 2718–38.
47. Tancer ML. Observations on prevention and management of vesicovaginal fistula after total hysterectomy. *Surg. Gynecol. Obstet.* 1992; 175: 501–6.
48. Kiricuta I, Goldstein AMB. The repair of extensive vesicovaginal fistulas with pedicled omentum: a review of 27 cases. J Urol 1972; 108: 724–7.
49. Turner-Warwick RT, Wynne EJC, Handley-Ashken M. The use of the omental pedicle graft in the repair of and reconstruction of the urinary tract. Br J Surg 1967; 54:849–53.
50. Elkins TE, DeLancey JOL, McGuire EJ. The use of modified Martius graft as an adjuvant technique in vesico-vaginal and rectovaginal fistula repair. Obstet Gynecol 1990; 75: 727–33.

51. Patil U, Waterhouse K, Laungani G. Management of 18 difficult vesicovaginal and urethrovaginal fistulas with modified Ingelman-Sundberg and Martius operations. *J Urol* 1980; 123: 653–6.
52. Margolis T, Elkins TE, Seffah J, Oparo-Addo HS, Fort D. Full-thickness Martius grafts to preserve vaginal depth as an adjunct in the repair of large obstetric fistulas. *Obstet Gynecol* 1994; 84: 148–52.
53. D. Dalela,* Apul Goel, S. N. Shakhwar And K. M. Singh .Vesical Calculi With Unrepaired vesicovaginal fistula: A Clinical Appraisal of An Uncommon Association, December 2003 *J of urology* Vol. 170, 2206–2208.
54. Sotelo R, Mariano MB, Garcia-Segui A, Dubois R, Spaliviero M. Laparoscopic repair of vesicovaginal fistula. *J Uro* 2005;173:1615–8.
55. Sherifi-Aghdas S., ,Mahad A;free bladder mucosal autograft in treatment of complicated VVF.BJU int.2002;89.Suppl 1:54.
56. VyasN, Nandi P.R Payvmood DwiveUS , M.,Tandon V, Singh B.P bladder mucosal autograft for repair of complicated VVF BJOG 2005;112:112.
57. McKay H.A;transurethral suture cystography for repair of VVF ;evaluation technique.int Urogynecol J Pelvic Floor Dysfunct.2001; 12:282.
58. Dogra PN Nabi G Laser welding of VVF int Urogynecol J Pelvic Floor Dysfunct.2001;12;69.
59. Sharma SK Turk TM ;Endoscopic injection of fibrin glue for the Treatment Of Urinary Tract Pathology *J Endourology*2005 ;19 :419.