

Pattern of penile growth after HCG treatment in sever hypospadias might provide a clue to intra-natal endocrinopathy and pathogenesis

Dr. Saadeldeen Gali. A. (F.I.B.M.S Urology)

Dr. Ali A. Muzaal (F.B.M.S. Plastic surgery)

Urology department and plastic surgical unit , Al-Sader Teaching Hospital , Medical College, Kufa University.

Key words:- hypospadias, HCG, penile growth, hormonal manipulation.

الخلاصة:

هذه الدراسة أجريت لتقييم فعالية هرمون HCG لتحفيز نمو العضو الذكري لدى الأطفال المصابين بتشوهه المبال التحتاني الشديد قبل التداخل الجراحي ودراسة نمط هذه الاستجابة كما تحاول هذه الدراسة تعزيز إحدى النظريات الجديدة والتي قد تفسر كيفية حدوث هذا التشوه أثناء فترة تكوين الجنين. شملت هذه الدراسة التي أجريت في فرع الجراحة البولية ووحدة الجراحة التجميلية في مدينة الصدر الطبية ستة عشر طفلا مصابا بتشوهه المبال التحتاني الشديد. حيث خضع المصابين والذين كانت تتراوح أعمارهم بين ثلاثة أشهر إلى ثمانية وأربعين شهرا جميعا إلى برنامج العلاج الهرموني بهرمون HCG قبل إجراء التداخل الجراحي وقد خلصت هذه الدراسة بان هرمون HCG فعال جدا في تحفيز نمو العضو الذكري لدى جميع المرضى كما بينت هذه الدراسة بأنه وباستخدام العلاج الهرموني فان شدة الانحراف الولادي في العضو الذكري المصاحب لهذا التشوه بدأت بالتناقص لدى جميع المرضى الخاضعين للعلاج مما يسهل إجراء عملية التداخل الجراحي كما بينت هذه الدراسة بان نمط النمو الحاصل في العضو الذكري بتحفيز الهرمون المذكور يكون معظمة في الجزء الداني لفتحة الاحليل أما الجزء القاصي من فتحة الاحليل فقد أظهرت الدراسة ممانعة أو عدم استجابة الأنسجة لهذا الهرمون وهذا النمط في النمو قد يفسر الأسباب التكوينية لهذا التشوه خلال فترة تكوين الجنين.

ABSTRACT

Hypospadias is a relatively common congenital anomaly of the penis that arises in 2 to 8 of 1000 live births, often as an isolated anomaly. This anomaly is repaired surgically in the first year of life to improve the cosmetic appearance and establish a glanular position of the urinary meatus for voiding and deposition of semen later in life. The aim of this study is to evaluate the effectiveness of HCG hormonal manipulation in inducing penile growth in hypospadias boys before surgical repair , and the pattern of this growth and response , in addition to that this thesis try to add more knowledge to the etiology and pathogenesis of one of these relatively common urogenital disorder.

Patients and methods :-This small series thesis included 16 boys with an age ranged from 3-48 ms who had proximal and penoscrotal hypospadias with sever cordea .All boys received a full course of HCG treatment using the standard WHO protocol of HCG therapy in pediatric age group. The degree and rate of response to HCG therapy together with the pattern of penile growth have been measured and evaluated before and one week after HCG therapy using the student T – test for statistical analysis.

Results :-At the end of HCG treatment penile growth has been achieved in all boys. The cordee decreased and penile length increased in all cases. The mean stretched penile length was changed from 18.68 pre HCG to 31.97 post treatment (P value < 0.001). The average penile length was nearly doubled after HCG treatment with an increase of 40% to 180% (mean 83%, P value < 0.001)What was very interesting and major finding that emerge during this study , is that the penile response and growth to HCG treatment was not universal over the whole shaft of the penis, with by far most of increment in penile length occurred proximal to urethral meatus and the percentage of

penile growth was 262% (P value < 0.001) proximal to meatus, while it was only 24% not significant (P value > 0.001) distal to it. This disproportional penile growth causing the meatus to advance distally in all cases with a mean distal migration of urethral meatus was 9.75 mm (P value < 0.001).

Conclusion :- HCG treatment in hypospadias was very effective in achieving sufficient penile growth that might facilitate the surgical outcome, the other finding is that hypospadias even the sever one is not at a fixed stage or degree, but it can easily be manipulated by hormonal treatment in addition to that, this study suggest that post natal response of hyposadias penis to HCG might provide a mirror that reflect its intra natal response during organogenesis and embryogenesis, and this thesis might provide a different insight toward the pathogenesis of hypospadias-chordea complex by diverting more attention and focusing toward a localized endocrinopathy that affect the tissue responsiveness to androgen.

Introduction

Hypospadias is a relatively common congenital anomaly of the penis that arises in 2 to 8 of 1000 live births, often as an isolated anomaly⁽¹⁾ The urinary meatus is positioned on the ventral surface of the penis. There is an incomplete foreskin, “a dorsal hood,” and varying degrees of ventral curvature. This anomaly is repaired surgically in the first year of life to improve the cosmetic appearance and establish a glanular position of the urinary meatus for voiding and deposition of semen later in life⁽¹⁾. Hypospadias affect approximately one in 250 live male births^(2, 3). recent reports suggest an increasing incidence of hypospadias⁽⁴⁾ The rising trend may simply reflect a more frequent or early diagnosis of mild forms of hypospadias over time or an increasing tendency to report the disorder to congenital anomaly registries. However, the results suggest that the ratio of minor to severe cases is decreasing, not increasing, as one would expect if the change in hypospadias rates was secondary to more frequent reporting of minor forms.⁽⁵⁾ A small percentage of severe hypospadias can be attributed to genetic syndromes or defects involving the androgen receptor⁽⁶⁾. Assisted reproductive techniques have also been associated with an increased risk for hypospadias; however, the etiology in the majority of cases of hypospadias remains unknown⁽⁷⁾.

Patients and methods:-

During the period between March 2010 and May 2011, a total of sixteen boys with an age ranged from seven months to forty-eight months with proximal penile and penoscrotal hypospadias and sever chordea were enrolled in this prospective study which have been done at urology department and plastic surgical unite of Al- Sader teaching hospital. The urethral meatus was located at the peno-scrotal junction in six patients and just distal to it, in ten patients. A standard WHO protocol⁽⁸⁾ of HCG therapy in pediatric patients have been used with a dose of 250 IU twice weekly for boys less than one year and 500 IU twice weekly for boys older than one year of age, and all boys have been completed the full HCG treatment course without any eventful complication. The stretched penile length, and the distance between the peno-scrotal junction and the urethral meatus was measured using a caliper just before and one week after hormonal manipulation and comparison of these parameters before and after therapy was performed using student's T test for statistical analysis. A statistical analysis was also used to assess the overall percentage of penile response and growth and the pattern of this growth in addition to the assessment of the distal migration of the

urethral meatus .At the end of HCG treatment course all boys have undergone surgical repair for hypospadias and chordea

Results

All boys received and completed their full HCG treatment course according to their age group, uneventfully, and there is no reported case of discontinuation due to side effects. At the end of HCG treatment, penile growth and enlargement were reported in all cases, however the degree of penile growth was variable. Before HCG therapy the stretched penile length as it was measured from the tip of the glans to the penoscrotal junction was ranged from 9-32 mm (mean =18.68) , while after HCG stimulation the stretched penile length was increased to be ranged from 22-45 mm (mean = 31.93) as it was shown in figure one. The percentage of increment in stretched penile length was variable among boys receiving HCG treatment, and it was doubled in more than 30% of cases, however it was ranged from 30% to 180% with a mean of 83.37%. (Figure two). The degree of response to HCG treatment as it was reflected by the percentage of penile growth was indirectly related to the pre HCG penile length, the smaller the penis before treatment, the grater the response will be then after. Before HCG treatment the distance between the urethral meatus to peno-scrotal junction varies from zero (at peno-scrotal junction) to 10 mm with a mean of 3.625mm, while one week after treatment this distance was changed to be ranged from 9mm to 19mm with a mean of 13.125mm. The percentage of penile growth and increasing in penile length proximal to meatus was very pronounced (mean = 262%) and statistically significant with a p value < 0.001.However the picture was differ distal to urethral meatus , in which the change in penile length as it was measured from the urethral meatus to the tip of the glans before and after HCG therapy was only slight and statistically not significant, as it was ranged from 9 to 22 mm before HCG treatment (mean = 15.06) and changed to be ranged from 12 to 26 mm one week after treatment, and the mean percentage of penile growth distal to meatus was only 24% (not significant). The distal migration of urethral meatus after HCG treatment varies from 7mm in some cases to 13 mm in others, with a mean equal to 9.75 mm which is statistically significant (p value < 0.001)

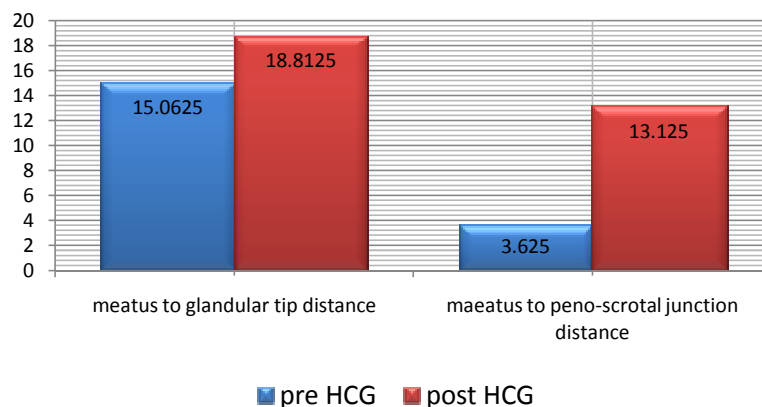


Figure one: - shows the disproportional penile growth in response to HCG therapy with more penile growth proximal to urethral meatus

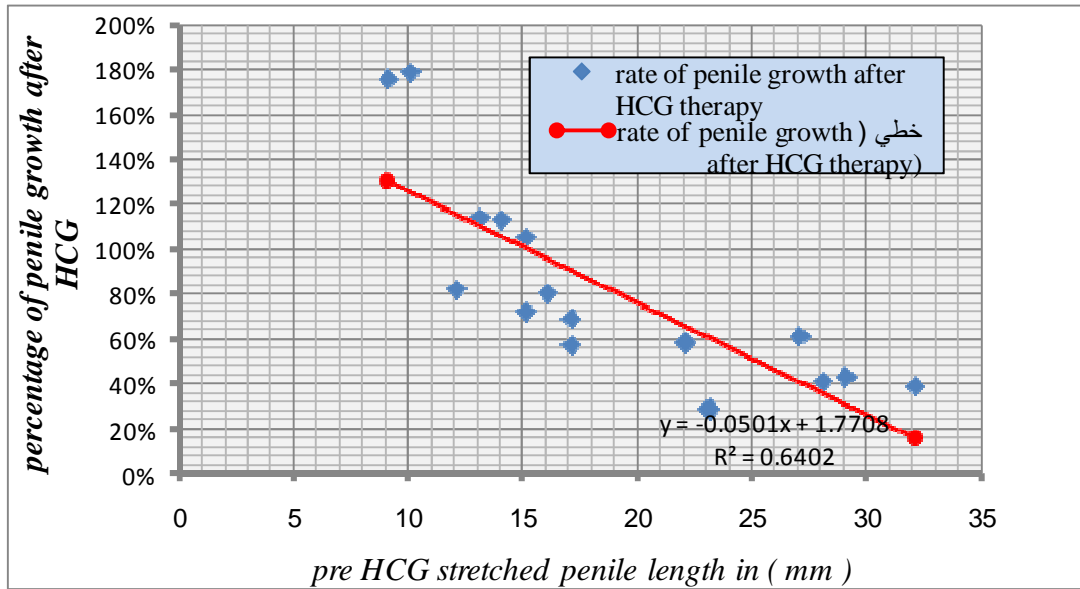


Figure two show the percentage of penile growth after HCG treatment

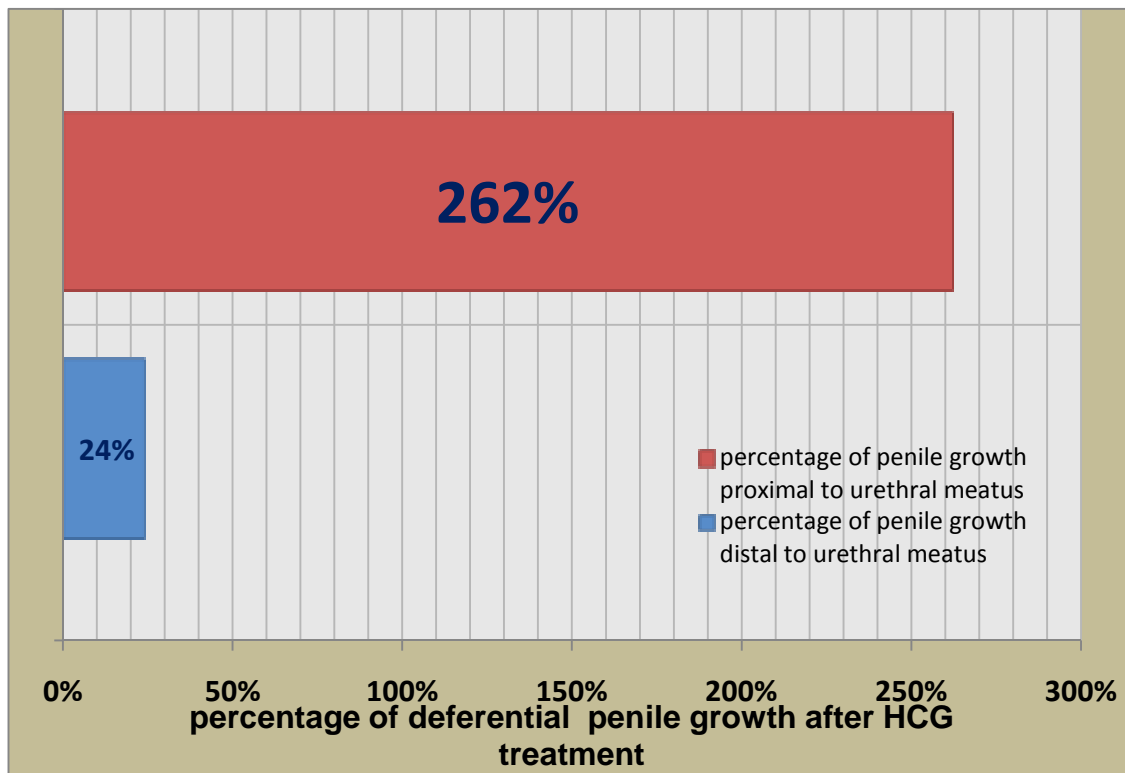


Figure three show the differential penile growth after HCG treatment

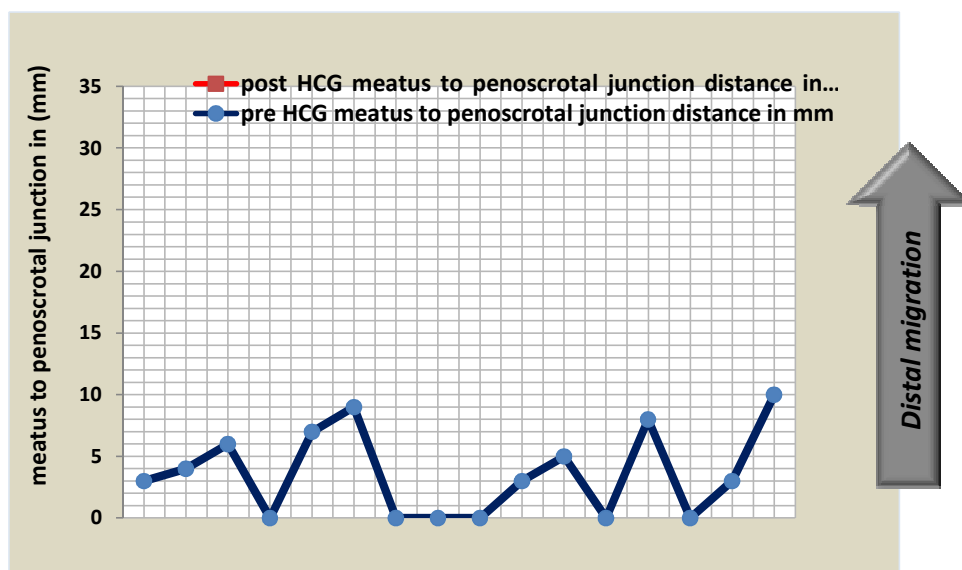


Figure four shows distal migration of meatus after HCG treatment

Discussion :-

Although HCG treatment have been widely used and investigated in the treatment of undescended testis, a relatively few number of studies investigate it's role and benefits in patients with hypospadias. For that reason there is considerable controversy surrounding the role and the clinical benefits of hormonal manipulation to stimulate penile growth and enlargement prior to reconstructive surgery. Areas of debate in that subject are many, and starting from its clinical benefits, the type of hormonal treatment (HCG versus testosterone), mode of administration (local versus systemic), the proper time at which it should be administered, patients who are most likely to benefit from such treatment, it's tolerability by the patients, and at the end, whether it affect subsequent puberty and fertility in the future^{(9),(10)}. In the other hand with the exception of sever hypospadias which was part of intersex problem and that, which was associated with ambiguous genitalia, the hormonal, cellular, biochemical, and genetic basis of hypospadias remain unknown , and there is a great debate about the role of testosterone, role of 5 α reductase, and androgen receptors in the pathogenesis of hypospadias .¹⁰⁻¹⁴ Baskin¹⁵ has proposed that future areas of study, such as endocrine disrupters, mesenchymal-epithelial interactions, and mechanisms of penile growth, may hold the key to explaining the etiology of hypospadias. The primary aim of this thesis is to study the pattern of penile growth in response to HCG in patients with severe type of hypospadias and chordea and to evaluate the effectiveness of this response before reconstructive surgery, in an attempt to add more data to collected studies in that subject, which might help reaching an appropriate recommendation in the future. Besides that, this thesis aimed to add more knowledge to the etiology of one of these common disorders .In this relatively small series study HCG treatment induce excellent

penile growth in all boys, so the average penile length was nearly doubled after HCG treatment with a mean increase in penile length by 83% of pre HCG treatment, and these results are by far superior than the results obtained in other studies by using testosterone, whether systemic or local, in which the authors noted a maximum of only 50% increase in penile size and length.¹⁶⁻²⁰ However these results which were obtained in this thesis, is slightly lower than that provided by Koff and Jayanthi²¹, in which, they reported 94% increase in penile length after HCG treatment, and this might be attributed to the longer course of treatment which have been used in this study, which was 6 weeks compared to the 4 week treatment course which have been used in our study. Both results provide strong evidence that support the superiority of HCG treatment over testosterone in inducing penile growth before reconstructive surgery in patients with hypospadias. So penile growth was higher with HCG than androgen, 83% versus 50% respectively and the reason for that might be attributed to the mechanism by which HCG stimulate penile growth. While androgen acts only directly on the target tissue, HCG acts primarily on the testis and stimulating them to secrete testosterone and during this process it might stimulate the testicles to secrete a different (growth factors) that augment and enhance the androgen action at target level and in addition to that HCG might have additional stimulatory effect on the genital target tissue in a manner similar to that in undescended testis and this why undescended testicle responding to HCG but not to androgen. In addition to that, HCG treatment have an additional benefit over testosterone in patients with hypospadias in that it can provide a test for the testicular ability to secrete testosterone which might declare some cases of intersex disorders that presented with hypospadias, as it was encountered in one of the cases during this thesis, in which the child did not response to HCG and hence he undergone standard HCG stimulation test which was negative and finally diagnosed as a case of Leydig cell hypoplasia and excluded from the study. The other highly interesting finding that emerge during this study, is that unique pattern of penile growth that occurred with by far most of the penile growth and increasing in penile length occurred proximal to the urethral meatus, so the percentage of penile growth and increasing in penile length proximal to meatus was very pronounced (mean = 262%), versus (24%) distal to the meatus. Such pattern of growth caused the urethral meatus to move distally and the chordea to decreased in all cases, with eventual decreasing in the severity of hypospadias in all boys included in the study, however the overall effects of these changes in the final outcome of surgery repair can not be assessed in this thesis because of lack of control sever one is not at a fixed stage or degree, but it can easily be manipulated by hormonal treatment. This study suggest that post natal response of hypospadias penis to HCG might provide a mirror that reflect its intra natal response during organogenesis and embryogenesis, and this thesis might provide a different insight toward the pathogenesis of hypospadias - chordea complex by diverting more attention and focusing toward a localized endocrinopathy that affect the tissue responsiveness to investigated by further studies, but was certain, HCG treatment by inducing penile growth will improve one of the most common late physiological squale of hypospadias repair²² when those boys reaching adolescence age, which was the dissatisfaction about their penile size and their sexual confidence. The post natal response of hypospadias penis to exogenous HCG and the pattern of this response, might provide a mirror that reflect its intra natal response to endogenous HCG during organogenesis and responsiveness to androgen.

Conclusion:- HCG treatment in hypospadias was very effective in achieving sufficient penile growth that might facilitate the surgical outcome, the other finding is that hypospadias even the sever one is not at a fixed stage or degree, but it can easily be manipulated by hormonal treatment in addition to that, this study suggest that post natal response of hyposadias penis to HCG might provide a mirror that reflect its intra natal response during organogenesis and embryogenesis, and this thesis might provide a different insight toward the pathogenesis of hypospadias-chordea complex by diverting more attention and focusing toward a localized endocrinopathy that affect the tissue responsiveness to androgen.

References

- 1- Leung TJ, Baird PA, McGillivray B. Hypospadias in British Columbia. *Am J Med Genet* 1985; 21:39–50 .
- 2- Avellan L 1975 The incidence of hypospadias in Sweden. *Scand J Plast ReconstrSurg* 9:129–138
- 3- Duckett JW 1998 Hypospadias. In: Walsh PC, Retik AB, Vaughan ED, Wein AJ, eds. *Campbell's urology*, 7th ed. Philadelphia: Saunders; vol 2:2093–2119
- 4- Paulozzi LJ, Erickson DJ, Jackson RJ 1997 Hypospadias trends in two US surveillance systems. *Pediatrics* 100:831–834
- 5- Dolk, 1998. Dolk H: Rise in prevalence of hypospadias. *Lancet* 1998; 351(9105):770.
- 6- Albers N, Ulrichs C, Gluer S, Sinnecker GHG, Mildenerger H, Brodehl J 1997 Etiologic classification of severe hypospadias: implications for prognosis and management . *J Pediatr* 131:386–392
- 7- . Silver RI, Rodriguez R, Chang TSK, Gearhart JP 1999 In vitro fertilization is associated with an increased risk of hypospadias. *J Urol* 161:1945–1957.
- 8- Mengel , W.,Knorr, D. and Zimmerman, F.A.: hormonal therapy for undescended testes. *Year Book Medicl Pup.*,1991:157-163.
- 9- Myers, 2000. Myers JP: Endocrine disruption: emerging science vitally important for pediatric urologists. In: Kirsch AJ, ed. *Dialogues in Pediatric Urology*, Vol. 23. Pearl River: William J. Miller Associates, Inc.; 2000:8.
- 10- Landrigan et al 2003. Landrigan P, Garg A, Droller DB: Assessing the effects of endocrine disruptors in the National Children's Study. *Environ Health Perspect* 2003; 111(13):1678-1682
- 11- Vrijheid et al., 2003. Vrijheid M, Armstrong B, Dolk H, et al: Risk of hypospadias in relation to maternal occupational exposure to potential endocrine disrupting chemicals. *Occup Environ Med* 2003; 60(8):543-550.
- 12- Silver, 2004. Silver RI: Endocrine abnormalities in boys with hypospadias. *Adv Exp MedBiol* 2004; 545:45-72.
- 13- Baskin et al., 1997. Baskin LS, Sutherland RS, DiSandro MJ, et al: The effect of testosterone on androgen receptors and human penile growth. *J Urol* 1997; 158(3 Pt 2):1113-1118.
- 14- Baskin et al., 2000. Baskin LS, Liu W, Li Y, et al: FGF-10 gene disruption results in hypospadias, Chicago, American Academy of Pediatrics, 2000.
- 15- Gearhart and Jeffs, 1987. Gearhart JP, Jeffs RD: The use of parenteral testosterone therapy in genital reconstructive surgery. *J Urol* 1987; 138(4 Pt 2):1077-1078.

- 16- Belman, 1997. Belman AB: Hypospadias update. *Urology* 1997; 49(2):166-172.
- 17- Chalapathi et al., 2003. Chalapathi G, Rao KL, Chowdhary SK, et al: Testosterone therapy in microphallic hypospadias: topical or parenteral?. *J Pediatr Surg* 2003; 38(2):221-223.
- 18- Monfort and Lucas, 1982. Monfort G, Lucas C: Dehydrotestosterone penile stimulation in hypospadias surgery. *Eur Urol* 1982; 8(4):201-203.
- 19- Koff and Jayanthi, 1999. Koff SA, Jayanthi VR: Preoperative treatment with human chorionic gonadotropin in infancy decreases the severity of proximal hypospadias and chordee [see comments]. *J Urol* 1999; 162(4):1435-1439.
- 20- Mureau et al., 1995a. Mureau MA, Slijper FM, Nijman RJ, et al: Psychosexual adjustment of children and adolescents after different types of hypospadias surgery: a norm-related study. *J Urol* 1995; 154(5):1902-1907.
- 21- Mureau et al., 1995b. Mureau MA, Slijper FM, van der Meulen JC, et al: Psychosexual adjustment of men who underwent hypospadias repair: a norm-related study. *JUrol* 1995 ;154(4) : 1351-1355.
- 22- Bin-Abbas et al., 1999. Bin-Abbas B, Conte FA, Grumbach MM, et al: Congenital hypogonadotropic hypogonadism and micropenis: effect of testosterone treatment on adult penile size why sex reversal is not indicated. *J Pediatr* 1999; 134(5):579-583.