

## Evaluation Of Corneal Endothelial Cells Hysteresis After Phacoemulsification

Dr. Alyaa Abood Kareem. M.B.Ch.B, F.I.C.M.S ophthalm., C.A.B ophthalm.  
Medical College-Kufa University  
Maan Abdul Ameer Kitab Alged. M.B.Ch.B

تقييم التغيرات التخلفية على الطبقة البطانية للقرنية بعد إزالة الساد بطريقة الاستحلاب-الفاكو

### الخلاصة

لغرض تقييم التغيرات التخلفية الحاصلة في الخلايا البطانية للقرنية بعد إجراء عملية إزالة الساد بطريقة الاستحلاب (الفاكو) أجريت هذه الدراسة على ٧٥ مريض بالساد تمت تهيئتهم لرفع الساد بهذه الطريقة. تم أخذ القراءات التالية للغشاء البقائي باستخدام المنظار المجهرى غير التلامسى قبل إجراء العملية: (سمك القرنية- معدل المساحة السطحية للخلية البطانية- كثافة الخلايا ونسبة الخلايا البطانية سداسية الشكل). أعيدت القراءات بعد مرور اسبوع ، ثلاثة اشهر وستة اشهر على العملية الجراحية. وجد أن فقدان في كثافة الخلايا البطانية وزيادة في معدل المساحة السطحية للخلية مع زيادة في سمك القرنية واختلاف كبير في نسبة التشكل السداسي للخلايا قد حصل بعد العملية.

أن إجراء عملية الساد بطريقة الاستحلاب (الفاكو) تؤدي إلى فقدان في عدد الخلايا البطانية للقرنية بشكل كبير مع زيادة في سمك القرنية وهذا ما يحصل في الأنواع الأخرى من عمليات رفع الساد والذي لا يمكن تجنبه عادة. على الرغم من أن كثافة الخلايا البطانية للقرنية قد انخفض بشكل واضح لكنه ليس العامل الوحيد للحفاظ على شكل وهيكلية القرنية فالوظيفة الفيزيائية للخلايا وقدرتها على إعادة ترتيب شكلها هو عامل مهم في هذا الجانب وهذا ما تم استنتاجه من ملاحظة التغيير الحاصل في المساحة السطحية للخلايا وشكلها.

### Abstract

**BACKGROUND:** The corneal endothelial cellular monolayer cannot regenerate after injury. Endothelial cell loss is a commonly studied relevant postoperative variable because it is associated with the long-term risk for corneal decompensation. Analysis of cell shape and pattern is a more sensitive indicator of endothelial damage than cell density alone.

**PURPOSE:** To evaluate hysteresis changes that occur in the corneal endothelium at different times (one week, three months, six months) after cataract extraction with phacoemulsification using noncontact specular microscope .

**PATIENTS AND METHOD:** Seventy-five patients scheduled for cataract extraction with phacoemulsification were examined with non contact specular microscopy (SP-3000P) performed at the center of the cornea. Corneal thickness (T), average cell area (AVG), cell density (CD), and percentage of cell hexagonality (HEX) were measured. Statistical analysis was performed using a 2-tailed Student t-test, Pearson correlation.

**RESULTS:** In all patients there was an increase in corneal thickness, widening in cell area, decrease in cell density, and extreme variability in their hexagonality after surgery. The results were as follows:- mean T was 480.5µm, 526.8µm, 534.3µm, and 541.3µm; mean AVG was 380.25mm<sup>2</sup>, 465.4mm<sup>2</sup>, 492.97mm<sup>2</sup>, and 527.77mm<sup>2</sup>; mean CD was 2809.00 cell/mm<sup>2</sup>, 2220.72 cell/mm<sup>2</sup>, 2053.56 cell/mm<sup>2</sup>, and 1899.97 cell/mm<sup>2</sup>; mean HEX was 72.27%, 27.35%, 39.35%, and 51.76% preoperatively, one week, three months, and six months postoperatively respectively. P value was <0.01 for all the findings (significant).

**DISCUSSION:** Although endothelial cell density in the early postoperative period is highly deranged but it is not the only valuable parameter to maintain corneal morphology. The ability of endothelial cells to function properly and rearrange themselves is a potential element for corneal architecture. Significant changes in the measured parameters were obtained during the entire period of the study reflecting the effect of phacoemulsification on the corneal endothelial features and function.

**CONCLUSION & RECOMMENDATIONS:** Corneal endothelial cells can be damaged by many factors during and after cataract surgery. Future refinements of the phacoemulsification techniques should aim to minimize early postoperative compromise of corneal endothelial function. A comparative study of the effect of phacoemulsification and other variety of surgeries will be a good indicator of endothelial cell damage induced by either technique.

**Key words:** corneal endothelium, corneal hysteresis, phacoemulsification

### **Introduction**

The corneal endothelium is a single layer of regularly arranged polygonal cells covering the posterior surface of the cornea. A minimum level of 400 to 700 cell/mm<sup>2</sup> is required for maintenance of normal corneal endothelial function<sup>1</sup> with corneal edema and decompensation occurring when cell density falls to 500 cells per mm<sup>2</sup> or below.<sup>2</sup> When endothelial function fails aqueous humor diffuses into the corneal stroma and produces corneal swelling and thickening. Therefore corneal hydration control is the most important index of corneal endothelial cell function.<sup>3</sup> The corneal thickness measured by pachymetry is an important indicator of the corneal edema and endothelial function.<sup>4,5,6,7</sup> In addition to having adequate cell density to maintain corneal function, a stable corneal endothelium has cells of relatively uniform size and shape.<sup>8</sup>

Corneal endothelium morphology is usually described by three aspects:-

- Endothelial cell density (ECD): is the number of corneal endothelial cells per square millimeter. The average value for adults is 2400 cells/mm<sup>2</sup> (1500-3500) with a mean cell area of 150-350µm<sup>2</sup>.
- Coefficient of variation (CoV): is a unitless number normally less than 0.3. It is the result of dividing the standard deviation of the mean cell area by the mean cell area. Polymegathism is increased variation in individual cell areas.
- Percentage of six-sided or hexagonal cells (% Hex): The apical surfaces of corneal endothelial cell form a mosaic that in the healthy young cornea consist of 70% to 80% of hexagonal cells. A mosaic of hexagonal structures which is often found in nature is geometrically and thermodynamically stable. A decrease in the hexagons with concomitant increase in number of cells with more than or fewer than six sides is known as pleomorphism and may be a sign of endothelial stress.<sup>9</sup> % Hex ideally should approach 100%. Lower percentage indicates a diminishing state of endothelium health.<sup>3,10</sup>

The principles of polymegathism and pleomorphism can best be illustrated by a discussion of the effects of diseases, surgery and contact lens wear on these parameters. However, morphometric analysis has shown that polymegathism and pleomorphism increase significantly with aging. Corneal thickness does not increase with age, but these changes in endothelial morphology may render the aged cornea more vulnerable to the stress of intraocular disease or surgery.<sup>8</sup> The corneal endothelial cell layer cannot

regenerate after injury. Trauma to the endothelium reduces cell density, increases the mean cell size, and disrupts the normal morphological pattern. Analysis of cell shape and pattern is a more sensitive indicator of endothelial damage than cell density alone.<sup>11</sup> Corneal endothelial cell loss is a commonly studied relevant postoperative variable, because it is associated with the long-term risk for corneal decomposition (pseudophakic bullous keratopathy).<sup>11, 12, 13</sup> During phacoemulsification, heat transferred from the probe to the cornea can result in stromal shrinkage. A phaco tip held too close to corneal endothelium allows the ultrasonic energy to injure and cause loss of endothelial cells. Corneal edema in these cases may appear on the first postoperative day or months to years after surgery.<sup>3</sup> Whether postoperative corneal swelling after phacoemulsification surgery correlates to corneal endothelial cell loss has been a matter of debate for several years. A more pronounced, transient postoperative corneal edema is sometimes noted after phacoemulsification surgery, indicating effects on the corneal endothelial pump function.<sup>12</sup> These have been ascribed to ultrasonic or mechanical trauma from the phacoemulsification procedure.<sup>14,15</sup> The causes of endothelial injury have been related to the mechanical effects of ultrasound, movements of lens fragments and air bubbles in addition to high fluid turbulence in the anterior chamber.<sup>16</sup> Operative factors associated with endothelial cell loss include older age, total amount of US energy, high nucleus grade, greater infusion volume and turbulence of the irrigating solution, movement of nuclear fragments and IOL and/or instrument contact.<sup>15,17</sup>

The aim of this study is to evaluate corneal endothelial changes (corneal endothelial hysteresis) induced by phacoemulsification at different times post-operatively (one week, three months and six months) using noncontact specular microscopy.

### **Patients and methods**

In this prospective study (75) patients scheduled for cataract surgery by phacoemulsification were included. Their eyes had clear corneas with no evident ocular disease apart from cataract. All shared the fact of negative past history of ocular problem or contact lens wear.

All eyes had uneventful phacoemulsification and intraocular lens implantation by the same surgeon through 3mm superior clear corneal incisions with an average surgical time of 28 - 44 minutes.

The following measurements were determined for each patient at the first day preoperatively (M1):

- central corneal thickness (T)
- endothelial cell density (CD)
- average cell area of all analyzed cells (AVG)
- percentage of cell hexagonality (HEX)

Measurements were repeated one week (M2), one month (M3), three months (M3), and six months (M4) after surgery.

In all subjects, measurements with noncontact specular microscopy (SP-3000P, Topcon Corporation, Tokyo, Japan) were done by masked single experienced technician. All measurements were taken at the same time of the day, between 10:00 am and 2:00 pm, twice or three times with a 5 min interval between each test.

SPSS software was used for statistical analysis. Results were analyzed using the two-tailed Student's t-test, Pearson correlation.

A *P* value <0.01 was considered statistically significant.

**Results**

The mean of central corneal thickness (T) in  $\mu\text{m}$  is shown in table (1) for the seventy-five patients at 1 day, 1 week, 3 and 6 months postoperatively.

Table (1) Mean central corneal thickness in ( $\mu\text{m}$ )

Thickness	Mean	$\pm$ S.D.	P value
M1	480.5333	42.01105	
M2	526.8400	56.53390	P<0.01
M3	534.3467	46.71260	P<0.01
M4	541.3733	73.72479	P<0.01

Figures 1, 2, 3 and 4 show central corneal thickness versus patients' age before surgery and after 1 week, 3 months and 6 months respectively.

Table 2 shows the mean of average cell area in  $\mu\text{m}^2$  (AVG) for the patients at the four defined time intervals

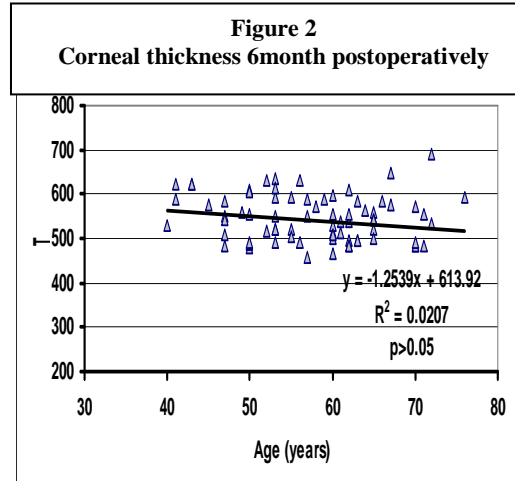
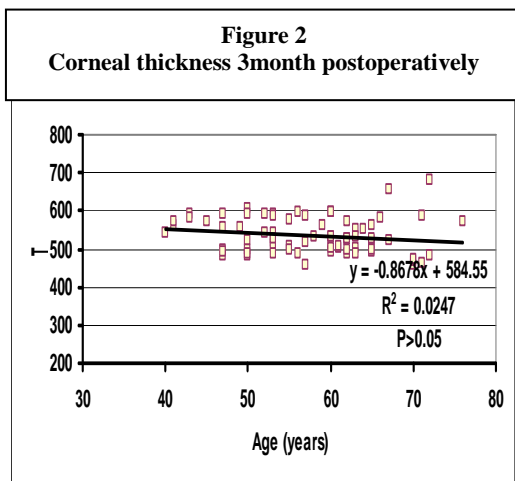
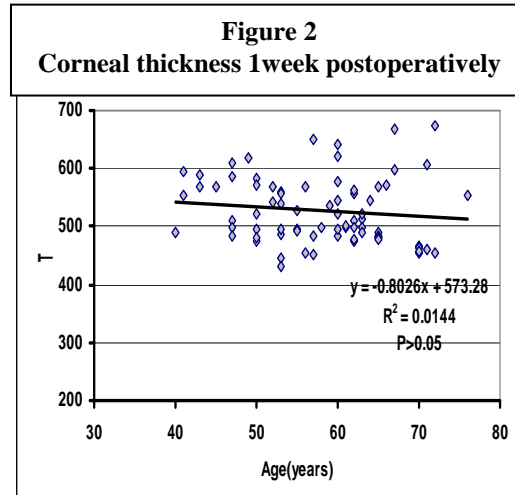
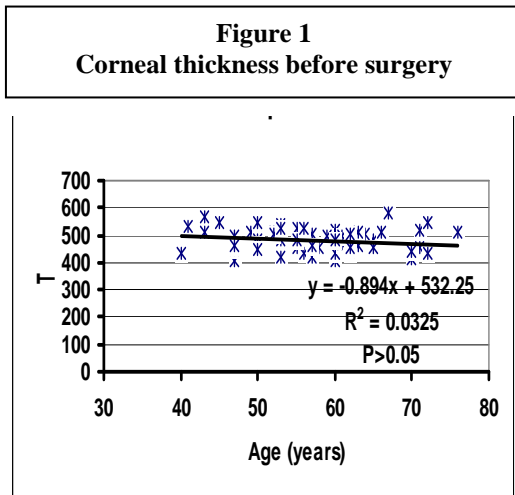


Table (2) The mean of average cell area in  $\mu\text{m}^2$  of corneal endothelium

AVG	Mean	$\pm$ S.D.	P value
M1	380.2533	53.57442	
M2	465.4133	67.79861	P<0.01
M3	492.9733	68.23785	P<0.01
M4	527.7733	65.05976	P<0.01

Figures 5, 6, 7 and 8 show AVG versus patients`age before surgery and after 1 week, 3 months and 6 months respectively

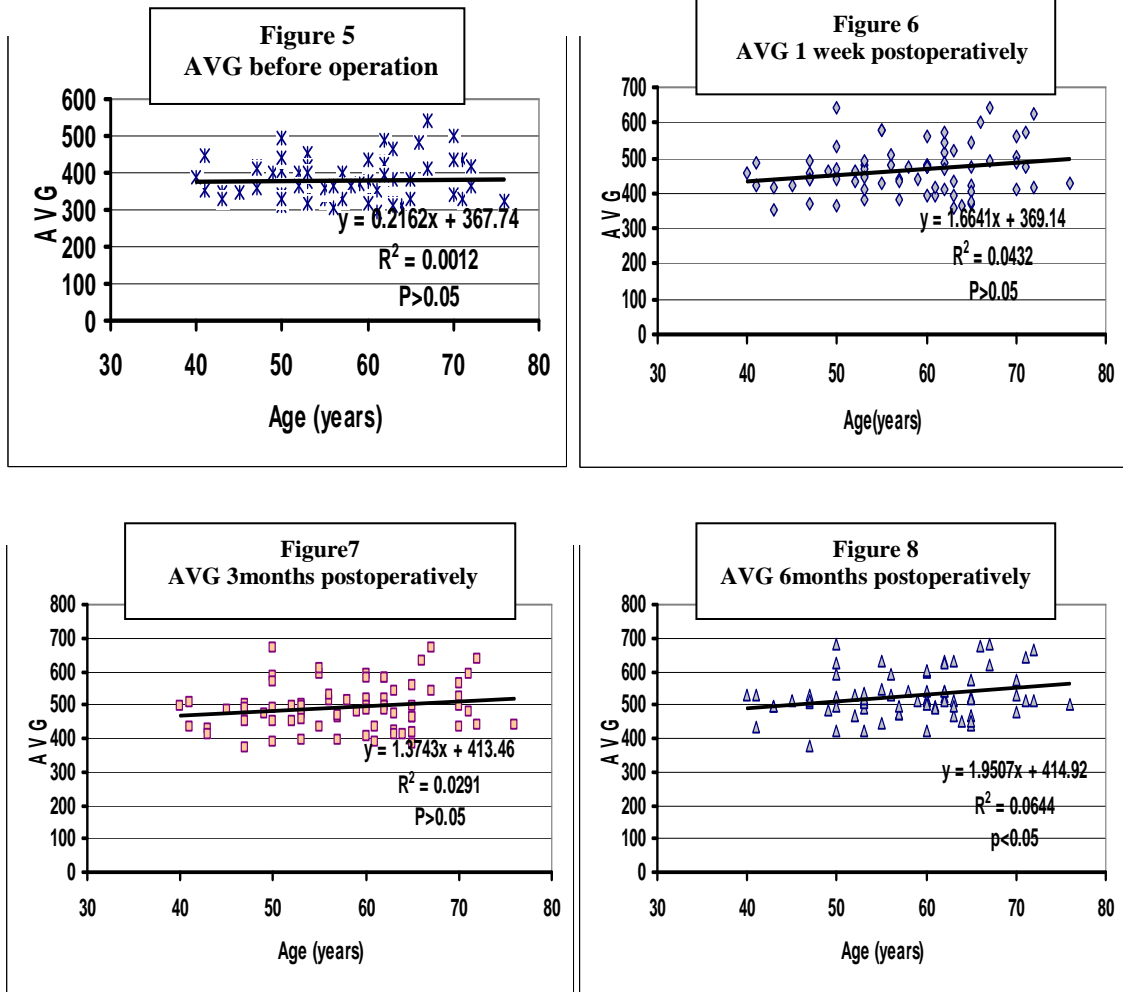


Table 3 shows the mean endothelial cell densities(CD)-cell/mm<sup>2</sup> for the four groups of measurements

CD	Mean	±S. D.	P value
M1	2809.0000	423.61294	
M2	2220.7200	359.76327	P<0.01
M3	2053.5600	360.39263	P<0.01
M4	1899.9733	335.45858	P<0.01

Table (3)The mean of endothelial cell density of corneas

Figures 9, 10, 11 and 12 show CD values for the patients before surgery and after 1 week, 3 months and 6 months respectively

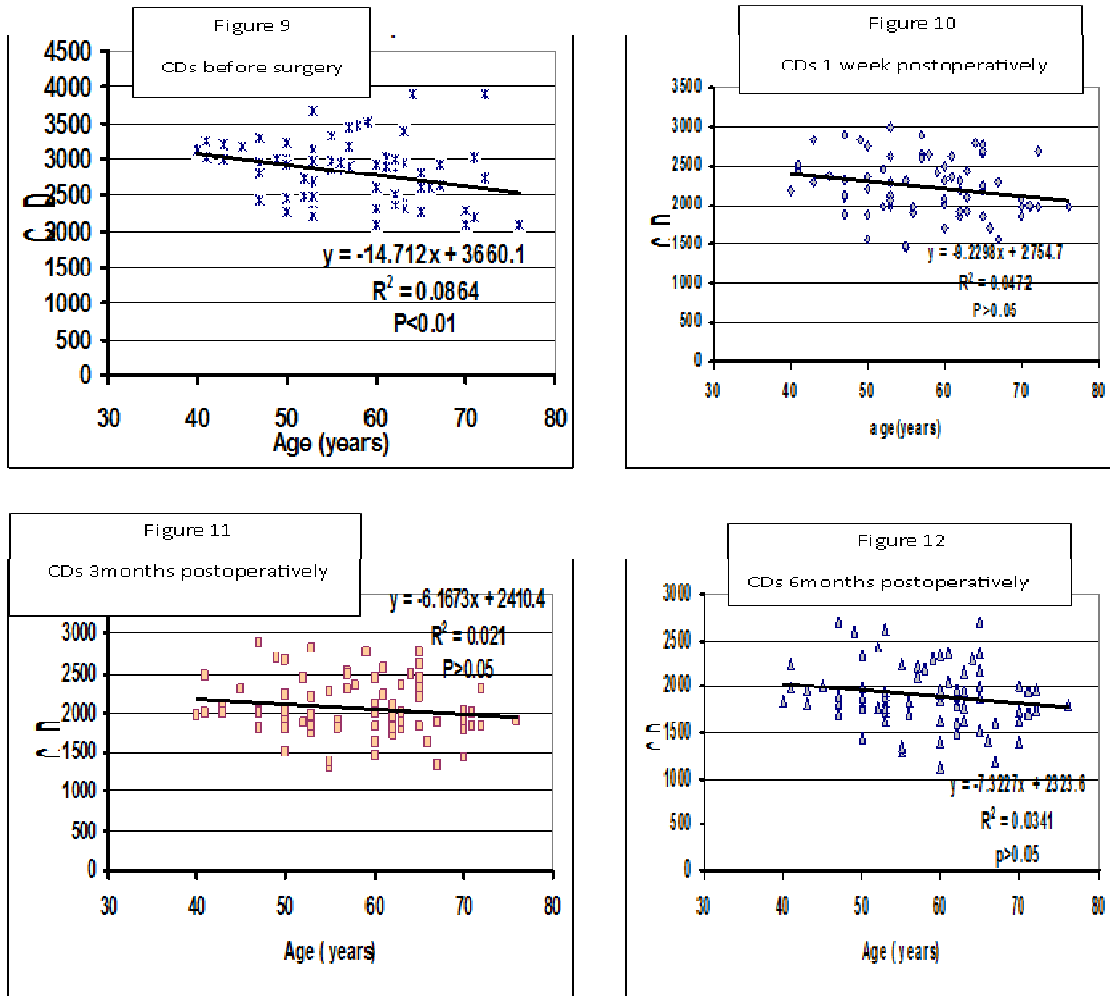
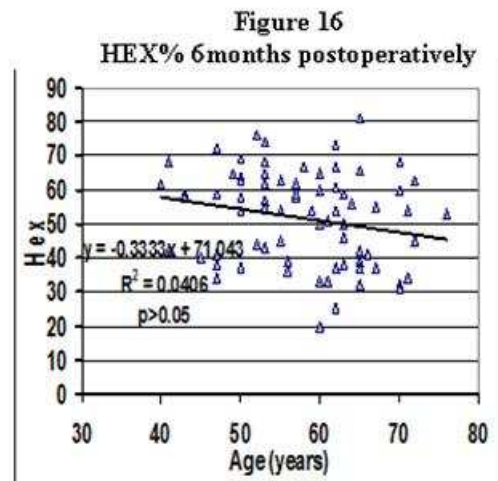
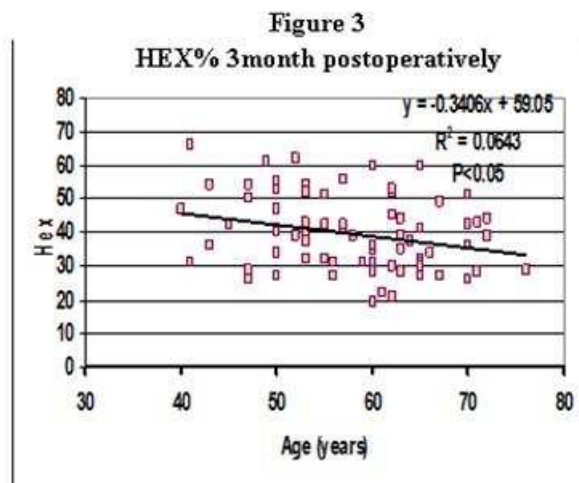
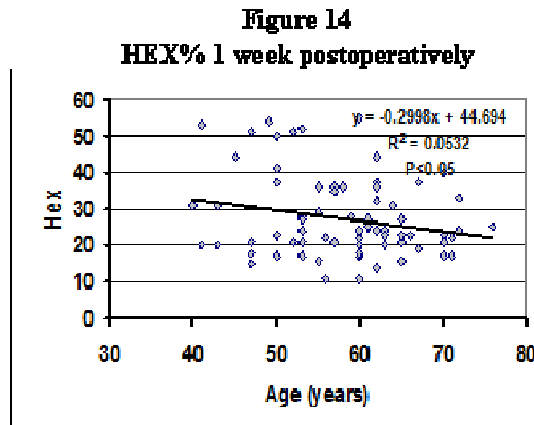
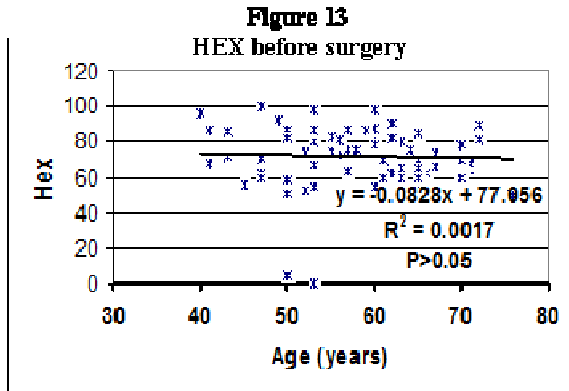


Table 4 shows the mean of percent of endothelial cell hexagonality (HEX) for the four groups of measurements

HEX %	Mean	±SD	P value
M1	72.2667	17.18055	
M2	27.3467	11.00183	P<0.01
M3	39.3467	11.37148	P<0.01
M4	51.7600	13.99791	P<0.01

Table (4) The mean of endothelial cell hexagonality%

Figures 13, 14, 15 and 16 show HEX % values for the patients before surgery and after 1 week, 3 months and 6 months respectively



## Discussion

Causes of corneal edema following surgical procedures are often multifactorial and related to the health of the patient's endothelium as well as to iatrogenic factors.<sup>3</sup> Corneal endothelial cells can be damaged by many factors during and after cataract surgery. Intraoperative factors associated with corneal endothelial injury include turbulence of the irrigation solution, mechanical trauma by instruments, the presence of lens fragments and intraocular lenses.<sup>16-20</sup> Hyaluronic acid has binding sites on the endothelium and may provide mechanical and chemical protection during surgery.<sup>21</sup> Endothelial alterations are considered important parameters of surgical trauma and are essential in estimating the safety of surgical techniques.<sup>22</sup> It is expected that endothelial damage diminishes cell density, increases corneal thickness, and alters the normal morphometric endothelial pattern.<sup>23</sup> Analysis of endothelial size and shape provides a more sensitive indication of endothelial cell damage than cell density alone. Therefore, polymegathism (expressed by the coefficient of variation in cell size) and pleomorphism (expressed by the percentage of hexagonality) may indicate endothelial trauma.<sup>24, 25</sup> In our study the corneal thickness was progressively increasing during the follow up period, there was a 9.7% increase in mean corneal thickness at 1 week postoperatively.

In the preceding months the rate of increase slows down and at 6 months postoperatively there was a 12.6% increase in mean corneal thickness of the studied eyes. Compromise of corneal endothelial function during surgery could lead to a transient increase in corneal thickness as measured by pachymetry. Meanwhile, the endothelial cell density fell down by 20.9% and 32.4% at 1 week and 6 months following surgery respectively. The density of corneal endothelium after the first week of surgery was profoundly low indicating significant change in the endothelial cells count. Some studies reported successful results with phacoemulsification surgery, even in cases with very dense nuclei, whereas others identify a dense nucleus as a major risk factor for corneal endothelial cell loss. Most of our patients had dense cataract and this can explain the level of cell loss we encountered. The average cell area after the surgery had undergone much of changes increasing by 22.3% at one week and 38.7% six months postoperatively, in other words the corneal endothelium rearrange their shape to cover the defects as they do not regenerate.

The percent of endothelial cell hexagonality dropped down very significantly corresponding to the changes in endothelial cell densities and morphology and it was very low specially in the early postoperative period (62.2% reduction at one week and 28.4% reduction at six months postoperatively). Considering that the endothelial morphology had attained acceptable values at 3 months postoperatively, the cell loss at this time is likely to have stabilized or at least to have entered a slower phase. Other studies have reported progressive cell loss over a long postoperative period.

All the above results were statistically significant with a 99% confidence limit. P value <0.01.

Endothelial cell function can be compromised in response to cataract surgery giving variable morphometric and pachymetric findings, although data pertaining to this are contradictory. Previous reports of increased corneal thickness after phacoemulsification describe variable increases in thickness months after surgery and were associated with endothelial cell loss. The interval between surgery and postoperative photography affects reported endothelial cell loss.<sup>26-27</sup>

The results of mean cell loss after different cataract surgeries are not homogeneous. Diaz-Valle et al. reported a mean cell loss of 11.8% three months after 5.5mm limbal incision and 18.3% after temporal corneal incision.<sup>28</sup> Dick and coauthors found a mean reduction in endothelial cellular density of 7.9% after temporal corneal incision.<sup>29</sup> Studies of uneventful cataract extraction reported by Kraff MC et al. showed a mean endothelial cell loss of 12.03%,<sup>30</sup> Bourne et al. reported an average of 10% reduction in corneal endothelial cell count by one year after both phacoemulsification and extracapsular cataract surgery.<sup>31</sup>

Matsuda et al. found that the frequency of hexagonal cells decreases from 68% preoperatively to 52% at four weeks after the cataract surgery and to 64% at 24 weeks after the surgery.<sup>11</sup> Jacobs also found that corneas after cataract extraction have a lower endothelial cell count and higher frequency of non hexagonal cells.<sup>2</sup>

More than one aspect of corneal endothelial cell morphology has been found to be related to age. Bourne et al. in a 10-year longitudinal study of 42 adult subjects found that there was 0.6% ± 0.5% central corneal endothelial cell loss per year. The percentage of hexagonal cells also decreases as a function of age.<sup>1,31,32</sup> Cheng et al calculated a mean endothelial cell loss of 2% per annum for cataract operated patients compared to 0.9-1% loss in the unoperated eye of the same group of patients.<sup>33</sup> Studying the endothelial cell variables with regards to the age distribution of our patients showed

an increase in corneal thickness and average cell area with decrease in cell density and endothelial cell hexagonality with advancing age in all the four groups of measurements.(figures1-16) However, the findings were not significant from the statistical point of view apart from the values for cell densities preoperatively, were elderly patients had significantly lower values. This indicates that age variation in our sample wouldn't alter the findings we obtained.

In conclusion, endothelial cell barrier function following phacoemulsification remained disturbed in spite of the apparent morphological stabilization. Corneal pachymetry alone is not useful for assessing postoperative endothelial changes, endothelial cell morphometric parameters are equally important.

With the refinement of the phacoemulsification technique, cataract surgery has undergone a remarkable development. Phacoemulsification offers faster visual rehabilitation, less induced astigmatism, and a more predictable postoperative refraction than traditional extracapsular cataract extraction. Still, the corneal endothelial cell loss is unavoidable and further refinements of the technique and adequate use of viscoelastic material is recommended.

Further studies with a larger population and a comparative analysis with other varieties of surgical techniques (like the conventional extracapsular cataract extraction) could be more conclusive.

### **References**

1. Bourne WM , Kaufman HE : Specular microscopy of the human corneal endothelium in vivo. *Am J Ophthalmol.* 81:319, 1976.
2. Jacobs PM, Cheng H, Price NC, et al. Endothelial cell loss after cataract surgery-the problem of interpretation. *Trans Ophthalmol Soc UK* 1982; 102:291–293.
3. Thomas J., Gregory L., Louis B. *American Academy of Ophthalmology; Basic and Clinical Science Course, External Disease and Cornea* 2008–2009.
4. Lattimore MR Jr. Influence of extended soft contact lens wear on the comparative measurement of central corneal thickness. *Acta Ophthalmol Scand* 1996; 74:239–242.
5. Yebra-Pimentel E, Gira´ldez MJ, Gonza´lez J, et al. Changes in corneal thickness after daily and extended wear of hydrogel lenses: a comparison of optical and ultrasonic pachometry. *Int Contact Lens Clin* 1998; 25:103–107.
6. Fakhry MA, Artola A, Belda JI, et al. Comparison of corneal pachymetry using ultrasound and Orbscan II. *J Cataract Refract Surg* 2002; 28:248–252.
- 7.Reinstein DZ,Aslanides IM,Silverman RH,et al. High frequency ultrasound corneal pachymetry in the assessment of corneal scars for therapeutic planning. *CLAO J* 1994; 20:198–203.
8. Yee RW, Matsuda M, Edelhauser HF. wide field endothelial counting panels. *Am J Ophthalmol* 99:596,1985.
9. Rao GN, Shaw EL, Arthur EJ, et al. Endothelial cell morphology and corneal deturgescence. *Ann Ophthalmol* 1979;11:885–899.
10. Tuft SJ, Coster DJ. The corneal endothelium. *Eye* 1990;4:389,4241.
11. Matsuda M, Suda T, Manabe R. Serial alterations in endothelial cell shape and pattern after intraocular surgery. *Am J Ophthalmol* 1984; 98:313–319.
12. Diaz-Valle D, Benitez Del Castillo Sanchez JM, Toledano N, Castillo A, Perez-Torregrosa V, Garcia-Sanchez J. Endothelial morphological and functional evaluation after cataract surgery. *Eur J Ophthalmol* 1996;6:242–245.
13. Dada VK, Sindhu N. Management of cataract-a revolutionary change that occurred during the last two decades. *J Indian Med Assoc* 1999; 97:313–317.

14. Walkow T, Anders N, Klebe S. Endothelial cell loss after phacoemulsification: relation to preoperative and intraoperative parameters. *J Cataract Refract Surg* 2000; 26:727–732.
15. Hayashi K, Hayashi H, Nakao F, Hayashi F. Risk factors for corneal endothelial injury during phacoemulsification. *J Cataract Refract Surg* 1996; 22:1079–1084.
16. Sugar J, Mitchelson J, Kraff M. The effect of phacoemulsification on corneal endothelial cell density. *Arch Ophthalmol* 1978; 96:446–448.
17. Edelhauser HF, Van Horn DL, Hyndiuk RA, Schultz RO. Intraocular irrigating solutions: their effect on the corneal endothelium. *Arch Ophthalmol* 1975; 93:648–657.
18. Kosrirukvongs P, Slade SG, Berkeley RG. Corneal Endothelial changes after divide and conquer versus chip and flip phacoemulsification. *J Cataract Refractive Surg* 1997; 23:1006-1012.
19. Mc Carey BE, Plack FM, Marshall W. The cataract procedure. I, the effect of intraocular irrigation solutions on the corneal endothelium. *Invest Ophthalmol* 1976; 15:449-457.
20. Roper Hall MJ, Wilson RS. Reduction in endothelial cell density following cataract extraction and intraocular lens implantation. *Br J Ophthalmol* 1982; 66:516-517.
21. Harfstrand A, Molander N, Stenevi U, et al. Evidence of hyaluronic acid and hyaluronic acid binding sites on corneal endothelium. *J Cataract Refractive Surg* 1992; 18:265-269.
22. Werblin HP. Long term endothelial cell loss following cataract surgery: model for evaluating endothelial cell damage after intraocular surgery. *Refract Corneal Surg* 1993; 9:29-35.
23. Mishima S. Clinical investigations on corneal endothelium. *Am J Ophthalmol* 1982; 93:1-29.
24. Sweeney DF, Holden BA, Vannas A, et al. The clinical significance of corneal endothelial polymegathism. ARVO abstract 8. *Invest Ophthalmol Vis Sci* 1985; 26:53.
25. Matsuda M, Miyake K, Inaba M. Long term corneal endothelial changes after intraocular lens implantation. *Am J Ophthalmol* 1988; 105:248-252.
26. Binder PS, Sternberg H, Wickham MG, Worthen DM. Corneal endothelial damage associated with phacoemulsification. *Am J Ophthalmol* 1976; 82:48–54.
27. Galin MA, Fetherolf E, Lin L, et al. Symposium on intraocular lenses: Experimental cataract surgery. *Ophthalmology* 1979; 86:213-218.
28. Diaz-Valle D, Ben`tezdel Castillo Sa`nchez JM, Castillo A, et al. Endothelial damage with cataract surgery techniques. *Cataract Refract Surg* 1998; 24:951-955.
29. Dick HB, Kohnen T, Jacobi FK, Jacobi KW. Long term endothelial cell loss following cataract surgery through a temporal clear corneal incision. *Cataract Refract Surg* 1996; 22:63-71.
30. Kraff MC, Sanders DR, Lieberman HL. Specular microscopy in cataract and intraocular lens patients; a report of 564 cases. *Arch Ophthalmol* 1980; 99:1782-1784.
31. Bourne RR, Minassian DC, Dart JK, Rosen P, Kaushal S, Wingate N. Effect of cataract surgery on the corneal endothelium: modern phacoemulsification compared with extracapsular cataract surgery. *Ophthalmology* 2004; 111:679–685.
32. Carlson KH, Bourne WM, McLaren JW, Brubaker RF. Variations in human corneal endothelial cell morphology and permeability to fluorescein with age. *Exp Eye Res* 1988; 47:27–41.
33. Cheng H, Jacobs PM, McPherson K, Noble MJ. Precision of cell density estimates and endothelial cell loss with age. *Arch Ophthalmol* 1985; 103:1378-81.