

Pathological study of p53 and ki67 in relation to clinic pathological parameters of laryngeal cancer

Esraa A. AL-Dujaily , M.B.Ch.B, M.Sc .(path.).

Short running title of no more than 40 characters:

p53, laryngeal cancer.

Address correspondence and reprints request to: Dr. Esraa Abdul-Aal, Department of Pathology and Forensic Medicine, Faculty of Medicine, Kufa University, Kufa, P.O. Box 18, Iraq. Mobile: 00964 (7801 409 921) E-mail: esraad@yahoo.co.uk

دراسة مرضية لل p53 وعلاقته بعوامل التكهن وعوامل تقدم الورم المرضية والسريرية لسرطان الحنجرة

ملخص

الأهداف: هذه الدراسة تهدف إلى تحديد أهمية ال p53 باستخدام الصبغة المناعية النسيجية الكيميائية واحتمالية ترابطه بعوامل التكهن وعوامل تقدم الورم المرضية والسريرية لسرطان الحنجرة.

الطريقة: تم الحصول على ٥٠ عينة مثبتة بالفورمالين ومطمورة بالبارافين لمرضى مصابين بسرطان الحنجرة. تم اعتبار انسجة الحبال الصوتية الغير مصابة بأي تغيرات مرضية لثلاثين عينة من الخمسين عينة كمجموعة مقارنة. استخدمت طريقة LSAB لتحديد التعبير المناعي النسيجي ل (p53) .

النتائج: أظهرت دراستنا علاقة ذات مغزى بين التعبير النسيجي الموجب لل p53 في (٣٥) حالة من الأنسجة المصابة بالسرطان. لم نلاحظ أي تعبير نسيجي ل (p53) في نسيج القولون الطبيعي مع وجود فرق ذا مغزى بالمقارنة مع الأنسجة السرطانية (p<0.05) . لم نجد ارتباط ذا مغزى بين التعبير النسيجي المناعي ل (p53) مع العمر، الجنس ومرحلة الخبيث للورم (P>0.05) .

علاوة على ذلك إن التعبير المفرط ل (p53) مرتبط بعلاقة معنوية ايجابية مع درجة تمايز الخبيث، موقع وحجم الورم (P<0.05) .

خاتمة: بالاعتماد على نتائج الدراسة الحالية يمكن استنتاج أن ال (p53) يلعب دور مهم في تولد نشأة خبيث الحنجرة ويسند الدليل عن دوره في عملية تطور وحياة الخلية. ويمكن التوجيه بأن تعطيل ال (p53) ربما يكون هدف لإعاقه عملية تطور وبالتالي بطور فعالية العلاج المضاد لهذا النوع من سرطان الحنجرة .

Abstract

Background: This study aimed to determine the significance of p53, evaluated by immunohistochemistry, and its possible correlation with clinicopathological parameters of laryngeal cancer.

Methods: FFPE (Formalin fixed, paraffin-embedded blocks) from 50 patients with laryngeal cancer were included in this study. We considered the uninvolved vocal cord that have no any pathological changes of thirty cases out of the fifty cases was evaluated as a non-tumoral sample were included as a comparative group. Labeled Streptavidin-Biotin Complex (LSAB) method was employed for immunohistochemical detection of p53.

Results: Our study showed significant p53 positivity among malignant cases (35)cases were positive for p53. P53 showed no positive immunoexpression in normal tissue sections with significant difference from that of malignant cases (p<0.05) . p53 showed no significant difference in relation to age ,sex and stage of the tumor. Furthermore p53 showed significant difference in relation to grade , site ,size(P<0.05).

Conclusion: Based upon the findings of this study, it can be concluded that p53 play an important role in the pathogenesis of laryngeal cancer and supports the evidence of its role in evolution and cell survival of this aggressive tumor . This study recommended

that the blocking of p53 may be a target for blocking the evolution and hence improving the efficacy of anti-cancer therapy against this type of cancer.

Background:

The squamous cell carcinoma represents about 90% of malignant tumors of the larynx, being correlated with smoking and alcoholism. Laryngeal squamous cell carcinoma (SCC), the most common malignant neoplasm of the upper airway in adults, accounts for about 1.5% of all cancers, These tumors can be classified anatomically, depending on their position in the larynx: supraglottic, glottic and subglottic cancers. The glottic localization has the best prognosis because of its poor lymphatic drainage, slow tumoral progression and late metastasis^(1,2). Stage, anatomical location, and histological differentiation of a tumor are gross predictors of clinical outcome, but for cancer of the larynx these prognostic factors have a limited predictive value for identifying a high risk of relapse or death. Therefore, it is important to define new prognostic indicators which may help to recognize the biological behavior of the tumor⁽²⁾. The exact molecular mechanisms of malignant transformation of the laryngeal mucosa are not clear. It has been suggested that the process of tumorigenesis is based on the accumulation of various stages of genetic damage, which impairs the mechanisms of cell cycle regulation⁽³⁾. Disruption of two major pathways controlling the cell cycle, tumor-suppressor gene p53 and pRb pathway are important⁽⁴⁾. The p53 gene product, which is able to block the cell cycle in G1 after encountering genotoxic stress, plays a central role in the G1 phase of the cell cycle⁽³⁾. Disruption of the pathways regulated by p53 leads to increased cell proliferation and additional genetic damage. Mutations in p53, resulting in expression of a non-functional protein, appear to be the most common abnormality in human neoplasms and are present as an early event in laryngeal carcinoma⁽⁴⁾. Although a relation was shown between p53 expression and shorter survival of the patients, conflicting results have been reported regarding its clinicopathological implications in laryngeal cancers^(5,6,7). On the other hand, expression of p53 has been associated with progression from dysplastic lesions to invasive carcinoma^(8,9).

Materials and Methods:

We analyzed tissue samples from 38 men and 12 woman with laryngeal SCC (mean age 60 years, age range 40-80 years) at Al Sader teaching hospital. The uninvolved vocal cord was evaluated as a non-tumoral comparative group sample in 30 cases out of 50 malignant cases. All patients were from the same geographic region (middle Euphrates). We selected cases whose disease had been diagnosed at our pathology department and for whom complete medical records were available. None of them had been treated previously. The TNM classifications were based on the 1992 recommendations of the American Joint Committee on Cancer. For conventional histopathologic examination, 10-µm paraffin sections stained with hematoxylin and eosin were examined. Tumors were graded according to morphologic differentiation: grade 1 is well differentiated, grade 2 is moderately differentiated, and grade 3 is poorly differentiated or undifferentiated⁽⁹⁾. All specimens were fixed in 10% formalin and routine histologic paraffin sections were made and stained with hematoxylin and eosin. Sections were cut to 3-4-µm thickness and mounted on poly-L-lysine-coated slides. The sections were deparaffinized in xylene and rehydrated in alcohol. The sections were incubated overnight with p53 antigen (pre-diluted, Dako) as primary antibodies. After that, the slides were rinsed gently with phosphate-buffered saline and an Envision Dual

link system-HRP (ready to use, Dako) was used as the secondary antibody. Incubation with 3,3-diaminobenzidine tetrahydrochloride was performed for 10 min as a substrate chromogen solution to produce a brown color. Finally, the sections were counterstained with hematoxylin. Appropriate positive and negative control sections were processed in parallel. Finally, Sections were evaluated under a light microscope and staining intensity of the tumor cells was classified semiquantitatively. P53 staining was considered negative if the staining was below 10% and positive if it was above 10%⁽¹⁰⁾.

Statistical analysis: the chi-squared test was used to compare categorical variables. Analyses were performed with SPSS software (Statistical Package for the Social Sciences, version 15; SSPS Inc., Chicago, IL, USA), with $P < 0.05$ as the cut-off value for significance.

Results:

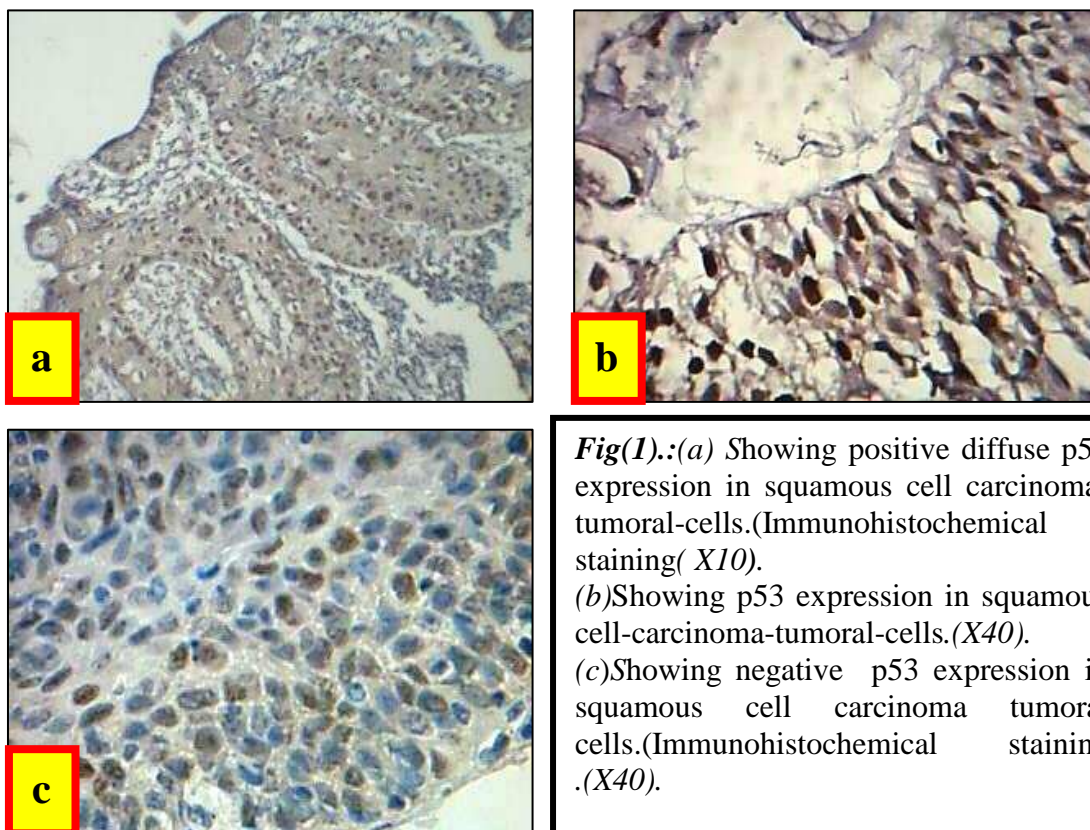
Our study showed significant p53 positivity among malignant cases (70%). P53 showed no positive immunoexpression in normal tissue sections that has been tested in parallel with that of malignant samples ,with significant difference from that of malignant cases ($p=0.000$) . P53 showed no significant difference in relation to age, sex and stage of the tumor ($P>0.05$). Furthermore p53 showed significant difference in relation to grade, site ,size ($P=0.003,0.003$ and 0.02) respectively. P53 was positive in (82.8%, 55.6% and 83.3%) of (grade I, II and III) respectively Fig (1). Regarding tumor site it was positive in (80.5%, 25% 20%) of Glottic, Supraglottic and Epiglottic respectively. Furthermore, p53 showed positivity in (77.5%and40%) of tumor size $<4\text{cm}$ and $\geq 4\text{cm}$ respectively. Table(1).

Table 1. p53 overexpression in relation to clinico pathological parameters:

<u>Parameters</u>	P53 in relation to clinicopathological parameters		<u>P</u> <u>value</u>
	<u>+ve</u>	<u>-ve</u>	
Normal tissue	0(-)	30(100%)	000*
Malignant cases	35(70%)	15 (30%)	
<u>Age</u>			
>50years	25(71.4%)	10(28.6%)	0.74
≤50years	10(66.6%)	5(33.4%)	
<u>Sex</u>			
Male	25(65.8%)	13(34.2 %)	0.25
Female	10(83.4%)	2(16.6%)	
<u>Tumor size</u>			
<4cm	31(77.5%)	9(22.5%)	0.02*
≥4cm	4(40%)	6(60%)	
<u>Tumor site</u>			
Glottic	33(80.5%)	8(19.5%)	0.003*
Supraglottic	1(25%)	3(75%)	
Epiglottic	1(20%)	4(80%)	

Grade			
I	29(82.8%)	6(17.2%)	0.003*
II	5(55.6%)	4(44.4%)	
III	1(16.7%)	5(83.3%)	
Tumor stage			
Stage III	25(71.4%)	10(28.6%)	0.74
Stage IV	10(66.7%)	5(33.3%)	

*: "significant p value"



Fig(1).:(a) Showing positive diffuse p53 expression in squamous cell carcinoma-tumoral-cells.(Immunohistochemical staining(X10).
 (b)Showing p53 expression in squamous cell-carcinoma-tumoral-cells.(X40).
 (c)Showing negative p53 expression in squamous cell carcinoma tumoral cells.(Immunohistochemical staining .(X40).

Discussion:

It has been suggested that laryngeal tumorigenesis is based on the accumulation of multiple genetic lesions in the sequence of dysplasia-carcinoma. The p53 protein plays an important role in apoptosis and cell growth regulation. This pathway is frequently inactivated by gene mutations that account for increased cell proliferation and makes cells susceptible to additional genetic damage ⁽¹¹⁾.

In previous studies, p53 expression has been found in laryngeal squamous cell carcinoma at frequencies ranging from 40% to 90% ^(12,13,14) . The expression of p53 in the series of patients studied in our study (70%) was within the range of values reported in the literature. In the literature, data on the relationship between p53 and clinicopathological parameters, obtained in different tumor types and from different series, are somehow controversial. p53 showed significant positivity among malignant cases in comparison there was no positive immunoexpression in normal tissue sections,

this observation was expected to us hence p53overexpression expression looks to be a landmark in the malignant laryngeal tissue, and does not play any role in the normal and benign laryngeal tissue sections that has been tested in parallel with that of malignant samples, this finding is agreed by Cabanillas R,etal,2007⁽¹⁵⁾.

Our study, showed a statistically significant difference between p53 expression and tumor size, site and grade in patients with laryngeal squamous cell carcinoma . The relation between p53 expression, and histological grade ,it was positive in (82.8% , 55.6% and 83.3%) of (grade I, II and III) respectively suggests the role of p53 in the progression of laryngeal carcinomas, this finding is agreed with that of Şirin Baspinari etal 2006 ⁽¹⁶⁾. Furthermore, there was no statistically significant difference between expression of p53 protein in relation to age, sex of the patient (P>0.05), this finding is agreed with that of Mustafa Kazkayasi et al 2001⁽¹⁷⁾.Regarding the tumor stage there was no statistically significant difference between p53 expression in relation to clinical stage ,the same finding found in the study of Şirin Baspinari etal 2006 ⁽¹⁶⁾, in our study this is could be due to the small sample size of IVcases (10 cases)only.

In conclusion, we suggest that analysis of p53 expression in tumoral tissues may help predict the clinical course in patients with laryngeal SCC and may, therefore, aid in the selection of patients who should be treated more aggressively.

References:

- 1.** Cann IC, Fried MP, Rothman KJ. Epidemiology of squamous cell cancer of the-head-and-neck.OtolaryngolClinNorthAm,1985;18:367-88.
- 2.** Gale N, Zidar N, Kambic V, Poljak M, Cr A (1997) Epidermal growth factor receptor, c-erbB-2 and p53 over expressions in epithelial hyperplastic lesions of the larynx. Acta Otolaryngol (Stockh) Suppl 527:105–110.
- 3.** Chen X, Bargonetti J, Prives C. p53, through p21 (WAF1/CIP1), induces cyclinD1synthesis.CancerResearch,1995;55:4257-63.
- 4.** Wayne S, Robinson RA. Upper aerodigestive tract squamous dysplasia: Correlation with p16, p53, pRb, and Ki-67 expression. Arch Pathol Lab Med 2006;130:1309-14.
- 5.** Jöckel MC, Sellmann L, Dorudian MA, Youssef S, Fözesi L. Prognostic significance of p53/bcl-2 co-expression in patients with laryngeal squamous cell carcinoma. Laryngoscope 2000;110:1339-45.
- 6.** Kropveld A, Slootweg PJ, Blankenstein MA, Terhaard CH, Hordijk GJ. Ki-67 and p53 in T2 laryngeal cancer. Laryngoscope 1998;108:1548-52.
- 7.** Polkowski W, van Lanschot JJ, Ten Kate FJ, Baak JP, Tytgat GN, Obertop H, *et al.* The value of p53 and Ki67 as markers for tumour progression in the Barrett's dysplasia-carcinoma sequence. Surg Oncol 1995;4:163-71
- 8.** Mithani SK, Mydlarz WK, Grumbine FL, Smith IM, Califano JA. Molecular genetics of premalignant oral lesions. Oral Dis 2007;13:126-33.
- 9.** Cabanillas R, Rodrigo JP, Astudillo A, Domvnguez F, Suárez C, Chiara MD. P53 expression in squamous cell carcinomas of the supraglottic larynx and its lymph node metastases: New results for an old question. Cancer 2007;109:1791-8.
- 10.** Kropveld A, Slootweg PJ, Blankenstein MA, Terhaard CH, Hordijk GJ. Ki-67 and p53 in T2 laryngeal cancer. Laryngoscope 1998;108:1548-52.

- 11.** Pignataro L, Capaccio P, Pruneri G, Carboni N, Buffa R, Neri A, *et al.* The predictive value of p53, MDM-2, cyclin D1 and Ki67 in the progression from low-grade dysplasia towards carcinoma of the larynx. *J Laryngol Otol* 1998;112:455-9.
- 12.** Polkowski W, van Lanschoot JJ, Ten Kate FJ, Baak JP, Tytgat GN, Obertop H, *et al.* The value of p53 and Ki67 as markers for tumour progression in the Barrett's dysplasia-carcinoma sequence. *Surg Oncol* 1995;4:163-71.
- 13.** Gerdes J, Becker MH, Key G, Cattoretti G. Immunohistological detection of tumour growth fraction (Ki-67 antigen) in formalin-fixed and routinely processed tissues. *J Pathol* 1992;168:85-6.
- 14.** Mithani SK, Mydlarz WK, Grumbine FL, Smith IM, Califano JA. Molecular genetics of premalignant oral lesions. *Oral Dis* 2007;13:126-33.
- 15.** Cabanillas R, Rodrigo JP, Astudillo A, Domvnguez F, Suarez C, Chiara MD. P53 expression in squamous cell carcinomas of the supraglottic larynx and its lymph node metastases: New results for an old question. *Cancer* 2007;109:1791-8.
- 16.** Şirin BAŞPINAR İetalThe relation of immunohistochemical p53 and p63 expression with histopathological parameters in laryngeal carcinomas ,turkish journal of pathology,2006, Cilt 22, Sayı 2, Sayfa(lar) 074-081.
- 17.** Mustafa Kazkayasi · Sema Hücümenoğlu ,Gerçek İ. Siriner · Mahmut Hücümenoğlu Over-expression of p53 and c-erbB-2 oncoproteins in laryngeal carcinoma .*Eur Arch Otorhinolaryngol* (2001) 258 :329–335.