

Comparative study of median nerve compression following colle's fracture Reduction anesthesia

Dr.Ali M.S.Al-Shadedi, FRCS.Ed, FRCS.GI, Consultant orthopedic surgeon, Assistant Professor orthopedic surgery

الخلاصة:

هدف الدراسة:

الدراسة مسبقية الإعداد، عشوائية ومقارنة لمعرفة فيما اذا كان زرق المخدر الموضعي في خثرة منطقة كسر كوليز للرأس عند ارجاعه يؤدي الى زيادة خطر حدوث متلازمة الضغط على العصب الاوسط مقارنة بالطرق التقليدية لارجاع الكسر بواسطة استعمال المخدر العام او استعمال المهدئات.

المرضى وطرق البحث:

تم دراسة ستون حالة عشوائية التقسيم الى مجموعتين متساويتي العدد كل واحدة تشمل ثلاثون مريضاً. تم ارجاع الكسر في المجموعة الاولى تحت المخدر الموضعي مقارنة بالمجموعة الثانية والتي استعمل التخدير العام او مهدئ الالم في عملية الارجاع. اتبعت نفس طريقة العلاج في ارجاع الكسر واسناده بالجبسونة ومتابعة المرضى بالفحوص اللازمة للكشف المبكر عن ظهور علامات ضغط العصب الاوسط والتنام الكسر، مباشرة قبل ارجاع الكسر وبعد يومين وبعد اسبوع وبعد كل اسبوعين ولمدة ستة اسابيع متوالية.

النتائج:

كانت نسبة حدوث متلازمة انضغاط للعصب الاوسط في المجموعة الاولى هي (٢٦.٦%)، بينما كانت النسبة في المجموعة الثانية هي (٦.٦%).

العبارة المستخلصة:

يستحسن استعمال المخدر العام او استعمال المهدئ في ارجاع كسر كوليز وان لاتستعمل طريقة التخدير الموضعي الا في الضرورة القصوى عند وجود مانع ما.

ABSTRACT

Aim of the study:

This is a prospective randomized comparative study to investigate whether or not injection of local anesthesia into the fracture Hematoma on reduction of Collie's fracture increases the risk of carpal tunnel syndrome in comparison to other traditional method of reduction under anesthesia or analgesia.

Patients and methods:

60 patients were diagnosed with colle's Fracture and randomized into two groups. Each of 30 patients of collie's Fracture, patients in the first group was reduced under Heamatoma bloke anesthesia, while the second group was reduced under general anaesthesia or analgesia. All of these patients were reduced and immobilized in the same way and examined for symptoms and sign of median nerve compression, pre-reduction examination, immediately after reduction, after two days, 1week and every two weeks for 6 successive weeks and sent for electromyography (EMG) and nerve conduction study (NCS).

Results:

The incidence of CTS (Carpal tunnel syndrome) was (26.6%) in group one and (6.6%) in group two.

Conclusion :

It is suggested to limit the use of hematoma block anaesthesia in reduction of Coles fracture unless there is special contraindication to other method.

Key words: Colles' fracture. Hematoma block anaesthesia. Carpal tunnel compression.

Introduction

Colles fracture is the injury that Abraham Colles described in 1814 as a transverse fracture of the radius just above the wrist, with dorsal displacement of the distal fragment.(1)

It is the most common of all fractures particularly in older people the high incidence being related to the onset of post- menopausal osteoporosis (1). The mechanism of injury of Colles fracture is a fall on an outstretched hand causing tension forces on volar aspect of the radius with bending and compression Forces on dorsal aspect of the radius(24) . With shear and/or compression component the fracture may become intra- articular .This fracture can be presented with many complication and these can be classified as early complications (2,7) like difficult reduction. Loss of reduction, unstable reduction, or Median nerve compression which is one of the most common complications (13%) of cases(6), associated carpal bones injury and Pain dysfunction syndrome. Or classified as intermediate and late complication like loss of reduction and deformity, Stiff hand, also Median nerve compression (carpal tunnel syndrome) and Extensor pollicis longus tendon rupture.

Most type I (Frykmann classification) distal radial Fractures (10,11) (Colles fracture) can be successively treated nonoperatively (3,8). Displaced fracture must be reduced under general Anaesthesia or local or regional anaesthesia (Hematoma block, Biers Block or axillary block etc.).

Carpal tunnel syndrome (CTS) is the most common, most important and the most carefully studied of all nerve entrapment syndrome resulted from fracture distal radius. (4).

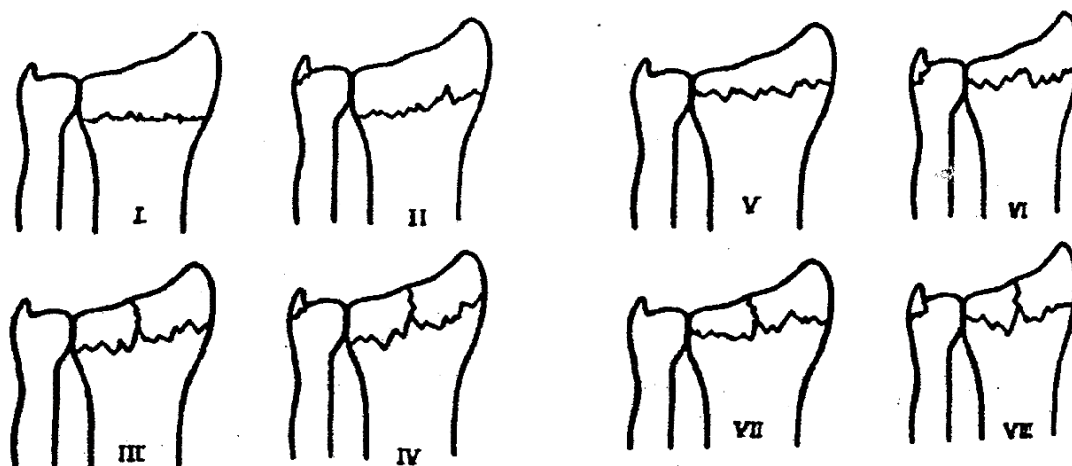
It is defined as compression of median nerve within the confines of the carpal tunnel which is characterized by pain and parasthesia, in the distribution of median nerve in the hand (5).

The incidence of median nerve compression in colles' fracture range between (0.7–17%) of cases. Any condition that crowds or reduce the capacity of carpal tunnel may initiate the symptoms; Colles' fractures and edema from trauma are among the most obvious causes. In the treatment of colles' fracture, immobilization in marked flexion and ulnar deviation can cause acute compression.

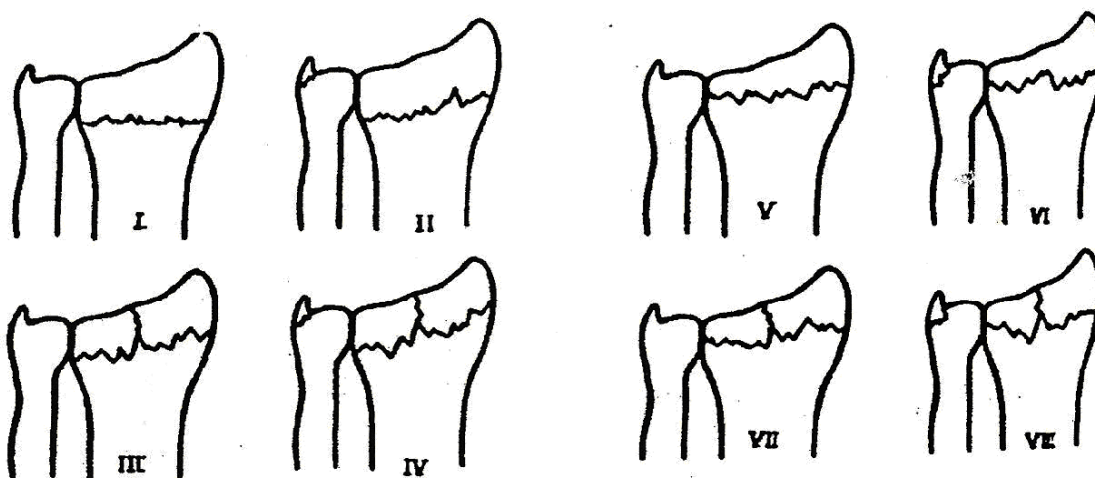
Frykmann classification(fig7).

Is the most common classification encountered in literature.

- I. Extra articular fracture of radius.
- II. Type one with fracture of the distal ulna.
- III. Radio – carpal joint involvement.
- IV. Type three with fracture of the distal ulna.
- V. Distal radio ulnar joint involvement.
- VI. Type five with fracture of the distal ulna.
- VII. Radio-carpal and radio-ulnar joints both involved.
- VIII. with fracture of the distal ulna.



The Frykman Classification of Colles'



The Frykman Classification of Colles'

fig (7)

Patients and methods:

Patients:

A randomized prospective study of 60 patients diagnosed with Colles fracture in the emergency department of Al- Yarmouk Teaching Hospital from august 2005 – to September 2006.

Age of those patients ranged from 30 – 75 years, mean age was 55 years, 38 patients were female and 22 of them were male.

Methods:

Randomly 30 patients were given Hematoma block anaesthesia as follow:

Each of those patient receive 10 ml of 1 % lignocain which was infiltrated dorsally in to the fracture hematoma after aspiration of blood, waiting for 10 – 15 min(12). then the Colles fracture was reduced by traditional method of closed reduction fallowed by applicant of dorsal back slab below Elbow .

The other 30 patient randomly recruited into the second group, In which Colles' fracture reduced under analgesia(13) and general anaesthesia.

24 patients were reduced under analgesia (Tramdol 100 mg) and sedation with diazepam, 5-10 mg slowly intravenously.

6 patients were reduced under GA during surgical procedure needed for other associated injuries.

The fractures in all patients were reduced by the same method and back slab was applied.

Patients which were excluded from the study include:

- 1-Those with previous carpal tunnel release to exclude the effect of fibrosis and released transverse carpal ligament.
- 2-Pregnant woman to exclude the effect of fluid retention.
- 3-Incomplete fallow up.
- 4-Those patients with Colles fracture that required other methods of Treatment (ligamentotaxis, percutaneous pinning, etc.)

The entire patients of the two groups were:

- Examined before reduction.
- Examined immediately following reduction and applicant of back slab.
- Examined after 2 days.
- Examined after 1 week in addition to x – ray check up and changing back slab to pop (plaster of Paris).
- Examined every 2 weeks for 6 weeks.
- EMG, NCS was done at 6 weeks.

The examination included looking for symptoms and signs of median nerve entrapment which are:(9)

Symptoms:

Parasthesia and later on nocturnal parasthesia,

Pain in the hand, weakness in the hands and sensory symptoms in the median nerve distribution of the hand.

Signs and tests:

Tinels sign test (percussion test).

Phalen test. (Forced flexion test)

Durkan test. (Compression test).

Carpal tunnel compression can be confirmed by the following tests:

Nerve conduction study(NCS) and electromyography(EMG).

Any patient, who has any symptoms or sign with positive neurophysiologic test, is regarded as having median nerve compression.

The following factors are stabilized in all patients:

All patients presented with Colles fracture Treated by closed reduction and dorsal back slab replaced by plaster of Paris cast after 1 week and kept for 6 weeks.

All patients were given the same type of analgesia.

Other associated injuries were ignored except those patients with neck pain, x-ray of cervical spine and EMG were done to exclude cervical and double crush phenomenon.

All fracture immobilize in 20° flexion and 20° degree ulnar deviation.

Result:

60 patients with Cole's fracture were studied. 30 of them were reduced under local infiltration (Hematoma block) and the other 30 patients their fractures were reduced by other methods; (24) patients were reduced by using Analgesia, and (6) patients by (GA). 6 females, constitute (15%) of the total candidates under investigation were diabetic and 2 females were hypertensive, 2 of the male (5%) were diabetic and 1 hypertensive (2.5%). (Tab.5)

The total unhealthy males in our study is 3 patient (7.5%) of the total candidates exposed to the study, compared to 8 females (20%) of the total.(Tab.5)

Eight (20%) of the total cases were diabetics as compared to Three cases (7.5%) were complaining of hypertension. (Tab.5)

Group 1: 30 patients who were reduced under hematoma block.

8 patient out of those 30 developed CTS. (26.6%). (Tab1)

3 patient out of those 8 patients were Diabetic one of them was male, and two were female, and one female was hypertensive.(Tab.6)

6 patients out of those 8 patients were female, and 2 were male.

Group 2: 30 patients who were reduced under analgesia and general analgesia.

2 patients out of 24 patients were reduced under conscious analgesia developed CTS. (6.6%) (Tab1). Both of them were female. 1 patient was diabetic. (Tab.6)

No patient out of 6 who were reduced under G.A develops CTS.

The incidence of CTS in Colles' fracture of our series about 17%.

Pain is the commonest symptom of CTS which present in 6 out of 10 patients developed Median nerve compression(60%).

Parasthesia present in 4 patients(40%), hypoesthesia present in 1(10%), weakness of grip present in 2 (20%).(4) Tinels test is the commonest positive test presents in 3 patients, the other two tests were difficult to perform because of pain at fracture site. (Some of the patients have more than one complaint).

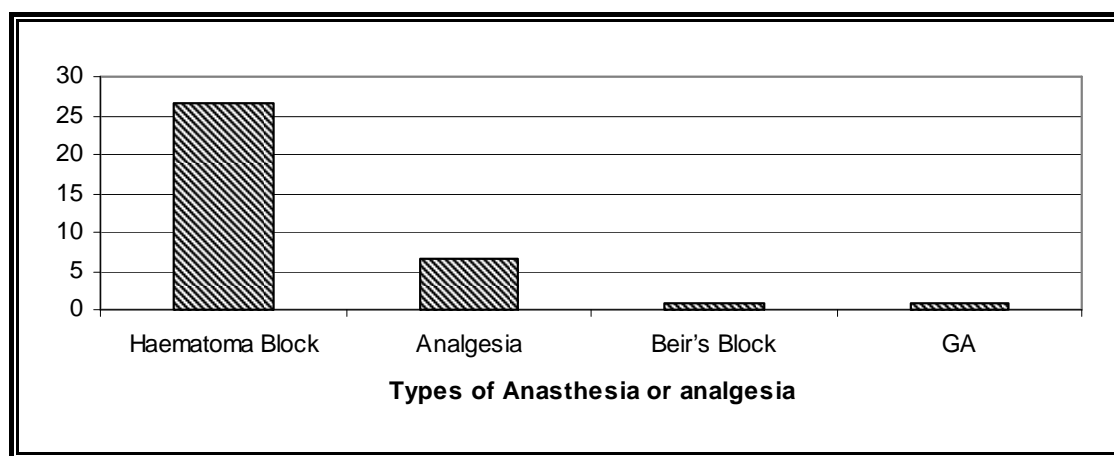
Electro diagnostic test was positive in 8 patients out of 10 cases diagnosed clinically.

The number of patients developed carpal tunnel syndrome in 48 hours were 3 (37.5 %), 1 patient in 1 week (12.5%) and 1 patient in 1-6 weeks. 3 patients after 6 weeks (37%).

Tab. & Graph 1

Methods	Percentage of CTS
Haematoma Block	26.6%
Analgesia	6.6%
GA	0%

Incidence of CTS in Colle's Fracture with different types of Anaesthesia and analgesia.



Percentage of incidence of CTS in various types of anaesthesia and analgesia.

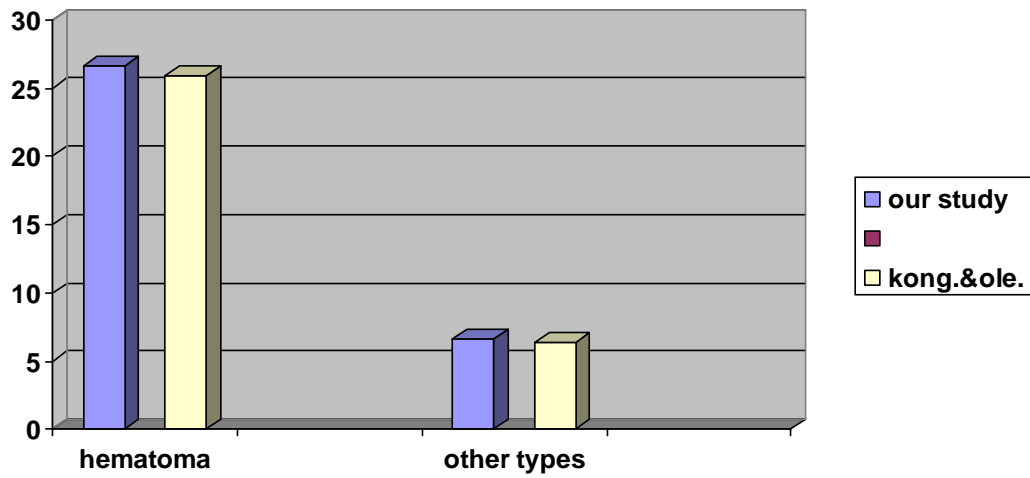
Table 2

Time	No. of Patients	Percentage
48 hr	3	37.5%
1 Wk	1	12.5%
1 Wk – 6 Wk	1	12.5%
6 Wk	3	37.5%

Incidence of CTS diagnosed by NCS in Relation to Time.

Studies	Hematoma block	Conscious analgesia
Our study	26.6%	6.6%
Kongsholm & oleured	25.9%	6.4%

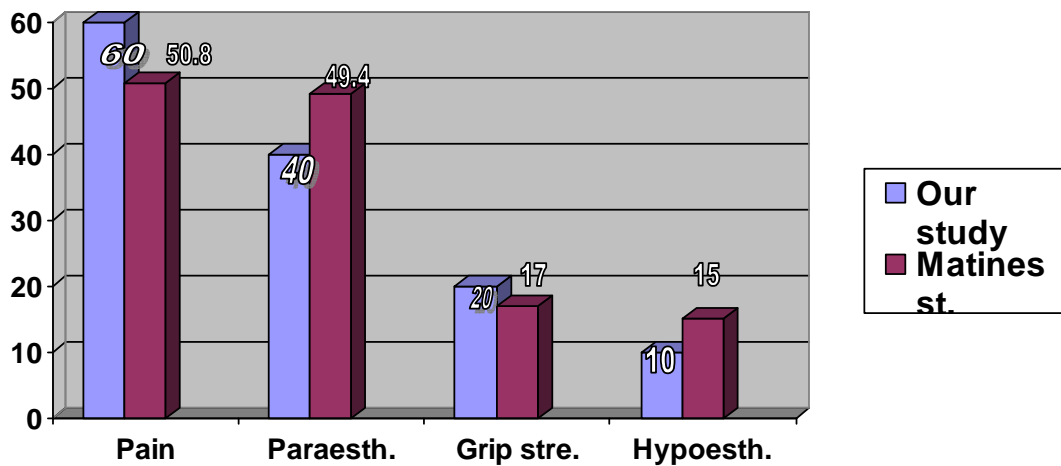
Incidence of CTS in different Studies.(Tab&grap3



Tab. & Graph 4

	<i>Pain</i>	<i>parasthesia</i>	<i>Grip strength</i>	<i>Hypoesthesia</i>
Our Study	60%	49%	20%	10%
Matines et al	50.8%	49.4%	17%	15%

Incidence of symptoms of CTS in various studies.



Unhealthy Male &Female patients in entire group under study. (Tab.5)

HYPER.		D.M.		TOTAL		
3	7.5%	1	2.5%	2	5%	M
8	20%	2	5%	6	15%	F
11	27.5%	3	7.5%	8	20%	Total

Unhealthy CTS Male & Female patients in each group of patients under survey(Tab.6)

Total	Unhea.CTs Pat Group 2		Unhea.CTS Pat. Group 1		
	F	M	F	M	
4 13.1%	1 3.3%	-----	2 6.6%	1 3.3%	DM
1 3.3%	-----	-----	1 3.3%	-----	HPT
5 16.4%	1 3.3%	-----	3 9.9%	1 3.3%	Total

Discussion

Median nerve injury is rare in Colles fracture, but compression in the carpal tunnel is fairly common (18). Carpal tunnel syndrome is one of the most common complications of fracture of distal radius.(11,14,15,16,17,18).

The majority of colle's fractures treated by closed reduction; manipulation under proper analgesia and/ or anaesthesia was used for reduction. Haematoma Block anaesthesia is still one of the common methods used by the surgeon for closed reduction of colle's fracture. However, others used biers block, brachial plexus block, conscious Analgesia and general anaesthesia. (7).

In our study we try to correlate the incidence of neurological complication (carpal tunnel syndrome) in colles' fracture reduced under Haematoma Block with other methods.

The incidence of CTS with colle's fracture reduced under Haematoma Block was 26.6%, which is comparable to the study of Kongshoim J, Olerud C. which was 25.9%. While the incidence of CTS in colle's fracture reduced under Analgesia and GA in our series was 6.6% compared to 6.4% in Kongshoin study, (tab&graph3). The incidence of median nerve compressions in Colles fractures as stated by Stewart, Innes and Brakes range between(0.7-17).(4)

This complies with our result of median nerve compression following reduction of Colles fracture without using local anaesthesia to about (6.6%). The aspiration of no more than one ml. of blood before the injection of about 5-7 ml. of local anesthetic into Haematoma of colle's fracture which increases the fluid content of carpal tunnel, apart from local trauma to the nerve which increases the edema and the local intra carpal pressure, raises the risk of occurrence of CTS and result in acute local compressive neuropathy. (23)

This led eventually to an increase in the incidence of CTS in our series to about (16.6%) after the use of local anesthetic, if this fact obtained from our work indicates anything; it does indicate that the use of local anesthetic increases the risk of median nerve compression to that limit.

In our study there is two cases (6.6%) of CTS complicate, Colle's fractures which were reduced under analgesia or general anaesthesia. This probably may be due to the fact that these methods are superior to Haematoma block in respect to the fact that it is the method of choice for Colle's fracture requiring manipulation and immobilization as it does not cause an increase in local pressure as hematoma block anaesthesia. (21).

The incidence of CTS in Colles' fracture in the first two days is higher (35.5%) due to local bleeding and edema, local injection of anesthetic and finally due to the method of splinting of volar flexion and ulnar deviation that result in acute compression of median nerve in higher incidence, this was agreed by kongsholm and olerud for their conclusion in having an accurate assessment of carpal tunnel geometry and size by CT scan in correlation with Colles' fracture in different positions.(22)

Another peak of the incidence occur after 6 Wk., this is secondary to scaring and fibrosis caused by trauma and local injection with increase in local pressure.

The overall incidence of CTS in Colles' fracture in our series about (17%) which was unfortunately at the upper limit of figures given by Stewart, Innes and Bakers (0.07-17%).(18 ,19)

There is a noticeable increase in the incidence of neurological complication in patients with other underling disorder. It is higher in Diabetic patient and Hypertensive; this is probably because these disorders increase the susptability of the nerve to the effect of pressure and trauma and they are a cause of CTS by themselves, disregarding the trauma or the local injection of anesthetic (20).

The sensitivity of electrodiagnostic tests in our series is 80% of the clinical tests.

Although electro diagnosis is a sensitive diagnostic indicator but it should not be used as an alternative to a careful history and clinical examination. Symptoms and physical examination are useful in objecting and confirming the clinical impression and assessing the severity of involvement.We used any symptom or sign of CTS for inclusion of the cases in our study. (20)

Pain is the commonest symptom (60 %) followed by parasthesia (40%) , grip strength loss (20%) then hypoesthesia (10%) which compared to Martines et al ; demonstrated that pain is the commonest (50.8%),parasthesia(49.4%),weakness(17%) hypoesthesia(15%).(Tab&fig4)..

The majority of the cases improved spontaneously. But some need surgical release. However this is beyond the scope of this study.

Conclusion:

1-CTS is common complication of colle's fracture and every surgeon should carefully look for symptoms and signs of CTS. Immediately and in every visit – during follow up of colle's fracture.

2-The incidence of CTS in colle's fracture reduced under local infiltration is significantly higher than other methods of Analgesia or anaesthesia. So it is suggested to limit the use of Haematoma block for reduction of colle's fracture.

References:

- 1-Solomon L, Warwick D, Naygam S."Apley's system of orthopedic and fracture"9th edition, 2010;P.772-5.
- 2-Eversman W.Ingeen DP, "Entrapment and compression neuropathy"Operative hand surgery .New York Churchill Livingston.2003, 3rd edition 1423-147.
- 3-Chapman MW,(Distal radial fracture)"Chapman's orthopedic surgery"1997 ,4th edition .375-382..
- 4-Stewart HD. Innes AR, Brake FD , "The hand complication of Colles' fracture" .Journal of surgery .2007; PB,103-106.
- 5-Gellman H, Gelberman RH ,Tanam B , "carpal tunnel syndrome an evaluation of provocative test" JBJS ;1986 No 557 B. P: X154-162.
- 6-Robrt M. Szabo MD. David R. MD. "Nerve entrapment syndrome at wrist" Jour. of Am. Acad. of orth. surg.(1999)Vol.2 No.2,P: 76-84 ..
- 7-Eric AF, Fishman MD.(Complication of Colles' fracture)2009.(WWW.pubmed.gov).
- 8-(Duncan. I, Sullivan. D.)-"Recurrent carpal tunnel syndrome treatment options" Jour. Of Southern Orth. Association.2005;Vol.8, No.1,P: 28.
- 9-Phalen GS, Clinical evaluation of 359 hands with carpal tunnel syndrome." Clinical and related researches, 1972, 83.P; 29-40.
- 10-Sove J. Solyurd.Acta orthopeda.,1993;Vol.73.P;244-252 "Classification of distal radius fracture "
- 11-Frykman C. "Fracture of distal radius including sequel shoulder, hand, fingers, syndrome disturbance in distal radio-ulnar joint and impairment of nerve function ".Acta ortho.scand.1997.suppl.P;108.
- 12- Brucescot.D "Technique of regional anaesthesia "2010.mediaglobe SA, Switzerland, 9th.edition, P; 482-485.
- 13-Kendall JM, Allen P,Young P, Meek SM, McCabe SE, .Journal of accident and emergency medical report,"Concise analgesia in Colles' fracture reduction"1995 Nov. 14 (6)35 .WWW.Pubmed.gov.
- 14-Ronald McRae,(Wrist examination) .Clinical Orthopedic Examination .4th.edition;1998; Churchill Livingston ,P: 86-88 .
- 15-Aro H. Kovanent C, , Katervuok D, Nieminens S," Compression Neuropathy after Colles Fracture "Clinical orthopedic journal . 1988, P 233,217-225.
- 16-Belesol RJ, Hess AV, "Distal radial fracture and concomitant skeletal and soft tissue injury "Orthopedic Clinical research of North America .1998 .24.P:327-331.
- 17-Lgnch AC, Lipscomb PR "The Carpal Tunnel Syndrome and Colles Fracture ",Jama 1983 .185.P:103-104 .
- 18-Stewart HD, Innes AR, Brake F, "The hand complication of Colles' Fracture ".Journal of hand surgery .1985.10 B. P:103-106 .
- 19-Eversmann WW, Green DP, "Operative hand surgery entrapment compression neuropathies" New York Churchill Livingston 1998, 2nd.ed. P: 1423-1478.
- 20-Wainapel SF. David SL. Rogoff JB. "Electro-diagnostic study of carpal tunnel syndrome after Colles' fracture .Am. Journal. Of phys. Med.1981 june.60 (30), P: 126-131.
- 21-Acad J.A.M."Anaesthesia in distal radial fracture ". Jour. Am. Acad. Orth. Srurg. 1994. 245. Vol. 2, No. 2, March-April. P.119.

22-KOngsholm J. Olerud C. "neurological complication of reduction of Colles' fracture without anaesthesia compared with traditional manipulation after local infiltration anaesthesia .1997(1) P:43-47.WWW.Pubmed.gov.

23-William TM. Cabe MC. Kelly S. "Verification of the Pressure in the provocative test of carpal tunnel syndrome " Anal of plastic surgeon .2002, July Vol.37, P: 8-11.

24-Terry Canale S."Distal radial fracture" Campbell's Oper. Orthop.2003. Mosby, Philadelphia, Pennsylvania .19102, Vol.3.P:3045.