

The Evaluation Of Histopathological Findings For Patients With Normal Colonoscopy

*Dr.Hassanain H.Khudier MBChB, FIBMSpath.

**Nadia Moeen Najim M.B.Ch.B.

Correspondence: Dr.Hassanain H.Khudier

Institute: Sulaimania teaching hospital

Mobile: 07701471644

E-mail: hkh1970@gmail.com

*department of pathology;College of medicine;University of Sulaimania.

** path.lab; Sulaimania teaching hospital .

تقييم نتائج الفحص النسيجي للمرضى الذين شخصوا طبيعياً بناظور القولون

د. حسنين حافظ خضير
البورد العراقي في علم الامراض/قسم الامراض-كلية الطب -جامعة السليمانية
د. نادية معين نجم
بكالور يوس في الطب والجراحة العامة

خلاصة البحث

الخلفية: إن ناظور القولون هو احد الطرق المستخدمة لغرض التشخيص والعلاج وكذلك يستخدم للبحث عن اسباب التغيير في حركة الامعاء (القبض او الاسهال) وكذلك الاعراض الاخرى كالام البطن والنزف المعوي او فقدان الوزن وفقر الدم مجهول الاسباب .

غرض الدراسة: تهدف هذه الدراسة في تقييم اهمية الفحص النسيجي لعينات القولون للمرضى الطبيعيين باستخدام ناظور القولون والذين يعانون من اعراض مختلفة كالاسهال المزمن وغيرها .

المرضى وطرق العمل: بين الفترة من الاول من حزيران ٢٠٠٨ ولغاية الاول من حزيران ٢٠٠٩ اجريت الدراسة على ١٠٠ مريض الذين ادخلوا الى مركز الجهاز الهضمي في السليمانية لاجراء ناظور القولون.
ان كل المرضى الذين كانت نتائجهم بالناظور طبيعية قد شملوا بهذه الدراسة والذين تم اخذ خزعات القولون منهم لغرض فحصها نسيجياً.

النتائج: ان معظم المرضى كانوا في العقد الرابع من عمرهم ولم يوجد فارقا كبيراً بين كلا الجنسين.
كذلك وجد ان ٤٣ % من المرضى كانت نتائج الفحص النسيجي لديهم غير طبيعية بينما كانت النتائج طبيعية في ٥٧ %.
ان الاسهال المزمن كان اكثر الاعراض السريرية شيوعاً حيث شكل نسبة ٤٠ % وكانت نتائج الفحص النسيجي لهم هو التهاب القولون المجهرى (lymphocytic colitis) ونسبة ٤٠ %.

الاستنتاجات: لقد وجد ان معظم المرضى خصوصا الذين يعانون من الاسهال المزمن ان الفحص النسجي لديهم غير طبيعي وبنسبة 77.5% بينما كانت النتائج طبيعية في 22.5% فقط. لذلك وحسب هذه النتائج ينصح باخذ الخزعات من القولون وخصوصا امن المرضى الذين يعانون من الاسهال المزمن حتى وان كان النظم لديهم طبيعيا.

Abstract

Background: Colonoscopy is a method of endoscope that has had a major role in diagnosis and treatment.

Colonoscopy also is used to look for causes of unexplained changes in bowel habits (diarrhea or constipation) and to evaluate symptoms like abdominal pain, rectal bleeding, weight loss and unexplained anemia.

Objective: The aim of this study is to evaluate the benefits of histopathological examination of colonic biopsy in patients who had normal colonoscopy result and presented with different symptoms (chronic diarrhea and others).

Method: During a period between 1st of August 2008 to 1st of August 2009, a prospective and retrospective study was done on 100 patients who presented with different symptoms and admitted to gastrointestinal tract center in Al-Sulaimania teaching hospital for colonoscopic examination. All the patients who were found to have a normal colonoscopic result and biopsies were taking from them were included.

Results: Most frequent patients were in the 4th decade of life and nearly equal male to female ratio. It was found that 43% of all patients with normal colonoscopy had abnormal colonic histopathology (microscopic colitis 28%, non specific colitis 15%), and normal histopathology in 57% for different presenting symptoms. Most common presenting symptom was chronic diarrhea found in 40% and their histopathological diagnosis were mainly lymphocytic colitis found in 16 patients (40%).

Conclusion: It was found that there was abnormal colonic histopathology in 31 patients (77.5%) of 40 patients with chronic diarrhea and in 9 patients only (22.5%) were normal. So according to this study, a diagnostic investigation for chronic diarrhea and other symptoms using a flexible colonoscopy is highly efficient and cost effective.

Introduction

Colonoscopy is a method of endoscope that has had a major role in diagnosis and treatment, it allows observation of mucosal surface of large bowel with a biopsy of identified lesions which sent for histopathological examination, also, it is used for therapeutic purposes including snare polypectomy and endoscopic mucosectomy to remove colorectal neoplasm especially adenoma or carcinoma with minimal submucosal invasion. ^(1, 2)

Colonoscopy also is used to look for causes of unexplained changes in bowel habits (diarrhea, constipation) and to evaluate symptoms like (abdominal pain , rectal bleeding, weight loss and unexplained anemia) and is used as routine scanning test for people of 50 years and older. ^{(3).}

The results of colonoscopy are said to be normal if the lining of the colon is a pale reddish- pink, with normal vascularity and there are no abnormal looking masses in its lining. ^{(3).}

Microscopic colitis:- is inflammation of the colon in which the patient presented as abdominal pain, watery diarrhea and sometimes rectal bleeding, and the colonoscopy

usually shows no signs of inflammation on the visible surface of the colon (i.e. the result of examination is normal colonoscopic result).⁽⁴⁾

Histopathologically there are 2 types of microscopic colitis (collagenous and lymphocytic), both types presented with 3-20 times non bloody- watery bowel movements per day accompanied by cramping abdominal pain.⁽⁴⁾

Patients are almost always more than 30 years old (mean age 55y), Collagenous colitis mainly affects middle and old age women while lymphocytic colitis affects males and females equally. Both diseases are benign in nature, with neither debilitating weight loss nor malignancy as potential outcomes. Some scientists think that collagenous colitis and lymphocytic colitis are the same disease in different stages.⁽⁵⁾

A diagnosis of collagenous colitis or lymphocytic colitis is made after tissue samples taken during a colonoscopy or flexible sigmoidoscopy are examined with a microscope⁽⁶⁾.

Microscopically:- in lymphocytic colitis the surface epithelium is somewhat flattened with loss of mucin and cytoplasmic vacuolization, and intraepithelial lymphocytes more than one lymphocyte per five epithelial cells with neutrophils, eosinophils, and occasional crypt abscesses.⁽⁷⁾

Normally the lymphocytes and occasional eosinophils may be present between the surface epithelial cells, which rest on a continuous thin basement membrane; the number of lymphocytes is one lymphocyte per five epithelial cells of colon. However collagenous colitis is moderately active colitis in the mucosa including cryptitis or crypt abscess and lymphocytic infiltration, the characteristic feature is the presence of discontinuous zone or band of collagen beneath the superficial lining cells. The thickness of this band is (12-30 microns). The thickness of the band varies so several tissue samples from different areas of colon may need to be examined⁽⁸⁾.

No definite cause has been found for microscopic colitis although the possible causes are bacteria and their toxins, viruses or non- steroidal anti-inflammatory drugs. Some researchers have suggested that microscopic colitis results from an autoimmune response which means that the body's immune system is destroying cells for no known reason⁽⁹⁾. Lymphocytic colitis shows a strong association with other autoimmune diseases including celiac sprue, thyroiditis, arthritis and autoimmune gastritis. The collagenous colitis may be associated with chronic wasting diseases and chronic autoimmune diseases like chronic hepatitis, rheumatic fever, vasculitis, etc.⁽¹⁰⁾.

The aim of this study is to evaluate the benefits of Histopathological examination of colonic biopsy in patients who had normal colonoscopy result and presented with different symptoms (chronic diarrhea and others).

Patients and Method

During a period between 1st of August 2008 to 1st of August 2009, a prospective and retrospective study was done on 100 patients who presented with different symptoms (abdominal pain, chronic diarrhea, and chronic constipation, bleeding per rectum and unexplained anemia and admitted to gastrointestinal tract center in Al-Sulamania teaching hospital for colonoscopic examination. All the patients who were found to have a normal colonoscopic result were included, the examination was done by Olympus type (Evis, LUCERA CLV-260) flexible colonoscopy, biopsies from terminal ileum and cecum were received in separate containers (test tubes) containing 10% neutral buffered formalin and then sent for histopathology lab, a gross description of tissue was performed, including the number of tissue fragments and dimension of each

tissue fragment. Then the specimen was put in filter paper then in cassette, processed in Auto processor (Sakura type) and embedded in paraffin, sectioning in 4 micrometers thickness by microtome(Sakura ,Accu-cut), then stained by Haematoxylin and Eosin stain.

Results

The Number of the patients in this study were 100, 51 females, and 49 males. Their age ranged between 20-70 years with the mean age of 41.4 years and most of them were in forth decade of life as shown in table-1 and Fig.-1.

Figure -2 shows the frequency of main presenting symptoms of (100) patients with normal colonoscopy.

Most of patients presented with chronic diarrhea (40%), followed by chronic constipation (21%), bleeding per rectum (18%), abdominal pain (7%), discomfort in anus (6%), unexplained iron deficiency anemia (4%), and mucous in stool 4% only.

Table -2 shows the histopathological results of (100) patients with normal colonoscopic examination. The results were (57%) normal histopathological findings,(28%)microscopic colitis,(25% lymphocytic, and 3% collagenous), and 15% were non specific colitis.

Table -3, Fig -3: show the histopathological diagnoses in 40 patients with chronic diarrhea in different age groups.

Table -4 and Fig.-4 show the presenting symptoms in patients diagnosed histopathologically as a microscopic colitis .

This means that about 67% of patients with microscopic colitis presented with chronic diarrhea, and about 11% with chronic constipation, 7% with abdominal pain,7% with pain in anus,4% with bleeding per rectum, and other 4% with unexplained iron deficiency anemia.

Figure- 5: shows lymphocytic colitis with increase in intraepithelial lymphocytes.

Figure-6 shows collagenous colitis with thick collagenous band below the basal lamina.

Table- 1: Age and sex distribution of (100) patients with normal Colonoscopy.

	Age\y	male	female	Total
1-	11-20	0	1	1
2-	21-30	7	9	16
3-	31-40	19	18	37
4-	41-50	14	11	25
5-	51-60	4	11	15
6-	61-70	5	1	6
	Total	49	51	100

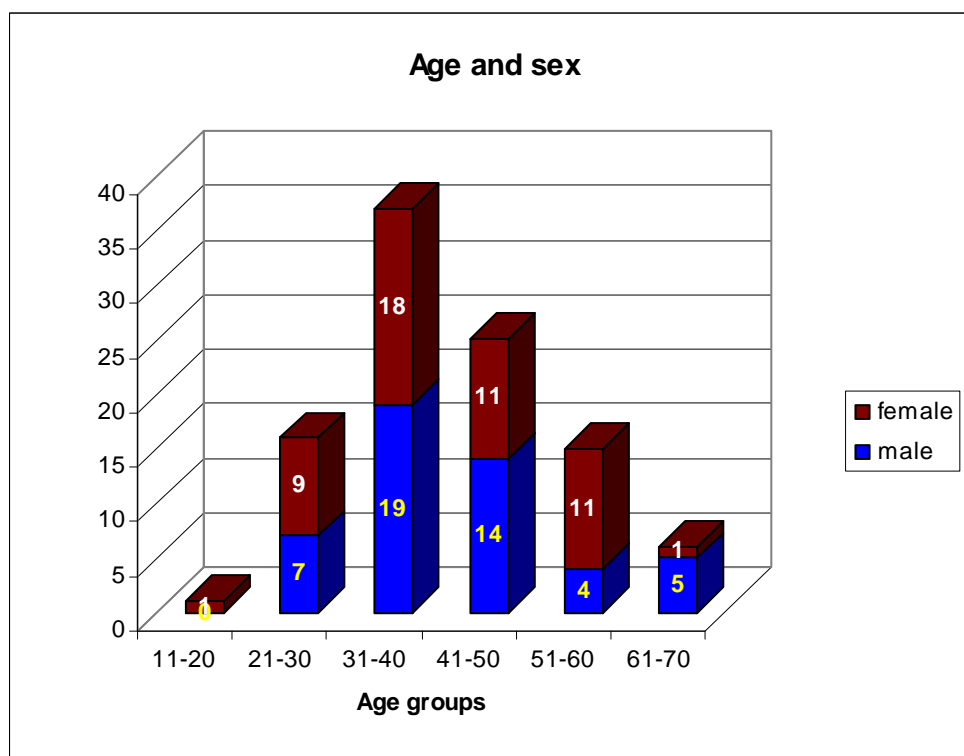


Fig -1: Age and sex distribution of (100) patients with normal colonoscopy:

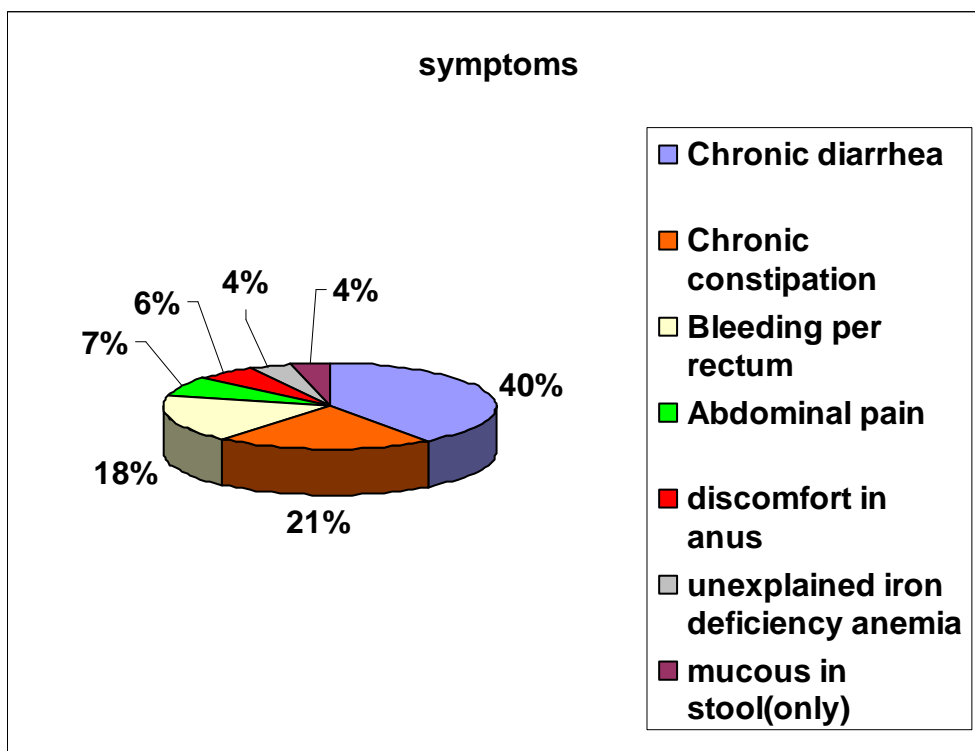


FIG.-2 Frequency of presenting symptoms of (100) patients with

normal colonoscopy

Table-2 Histopathological diagnoses of 100 patients in relation to sex.

	Histopathology findings	Female no	Male no.	percentage
1	Normal results	30	27	57%
2	Lymphocytic colitis	10	15	25%
3	Collagenous colitis	3	0	3%
4	Nonspecific colitis	8	7	15%
	Total	51	49	100

Table 3: histopathological diagnoses in 40 patients with chronic diarrhea in different age groups:

age in years	Normal	Non specific colitis	lymphocytic colitis	collagenous colitis
11-20	0	1	0	0
21-30	5	1	2	1
31-40	3	2	7	1
41-50	0	5	5	1
51-60	1	3	2	0
61-70	0	0	0	0
total	9	12	16	3

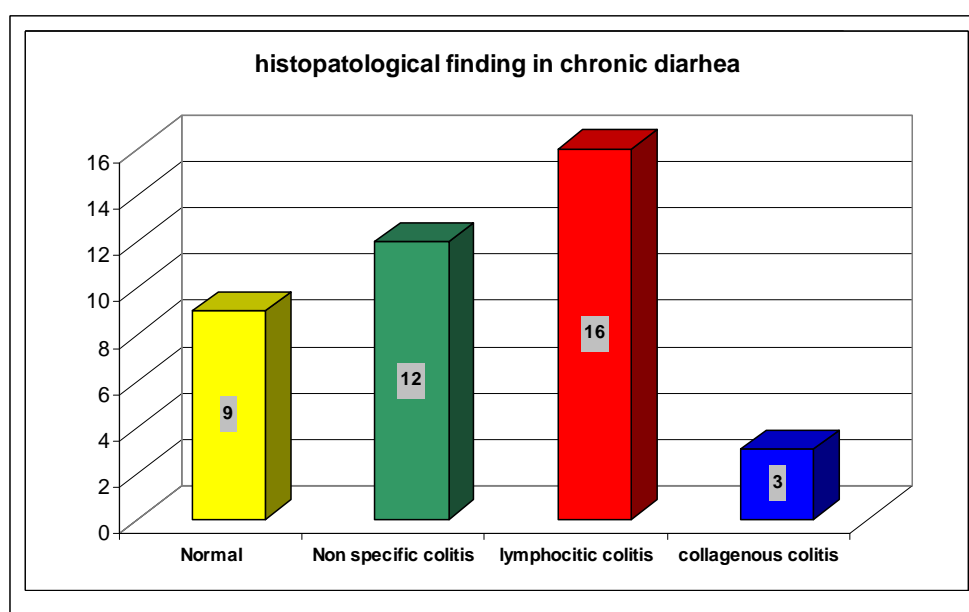


Fig. 3: histopathological diagnoseses in 40 patients with chronic diarrhea

Table -4 presentation of microscopic colitis:

Presentation	total	percentage
Chronic diarrhea	19	67.86%
chronic constipation	3	10.71%
abdominal pain	2	7.14%
Pain in anus	2	7.14%
Bleeding per rectum	1	3.57%
Iron deficiency anemia	1	3.57%
Total	28	100%

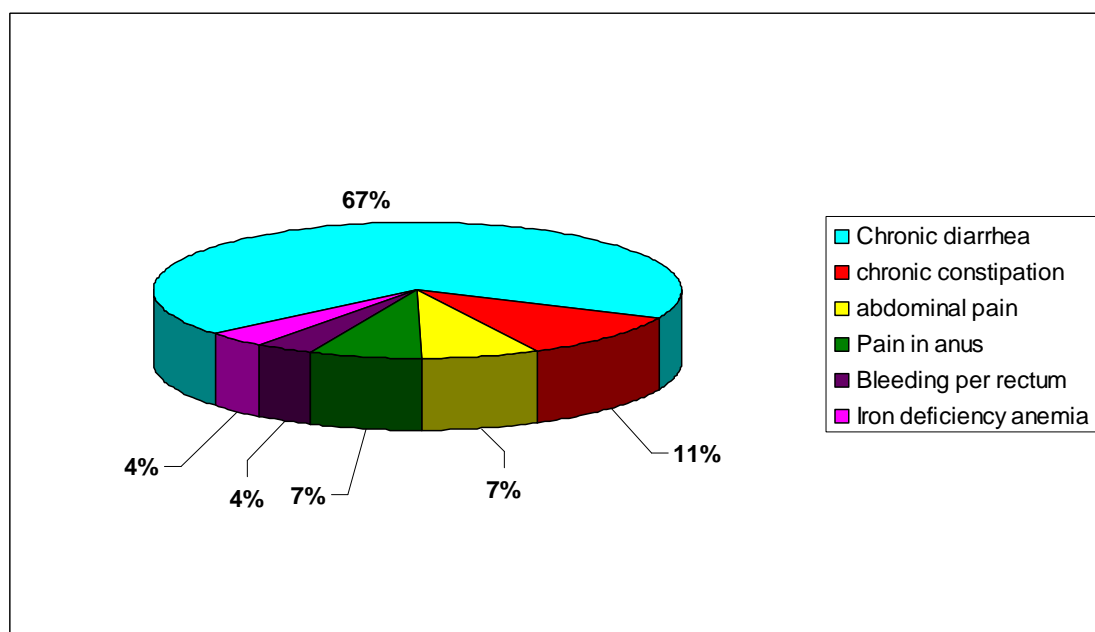


Fig.-4 presentation of microscopic colitis:

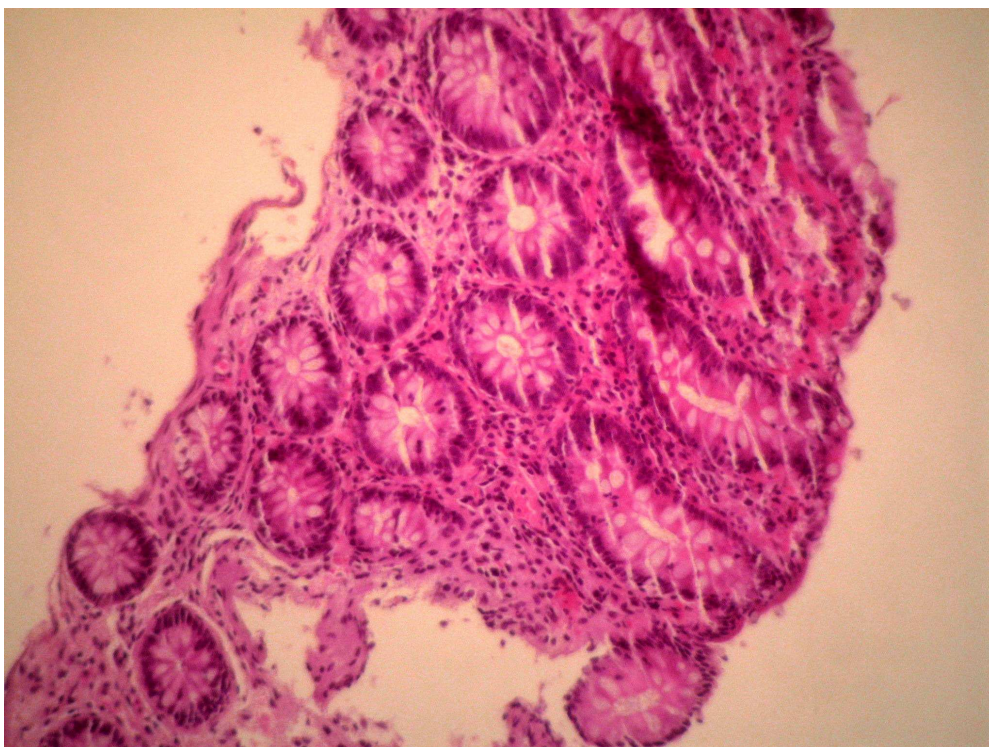


Fig -5 Lymphocytic colitis. H&E x400

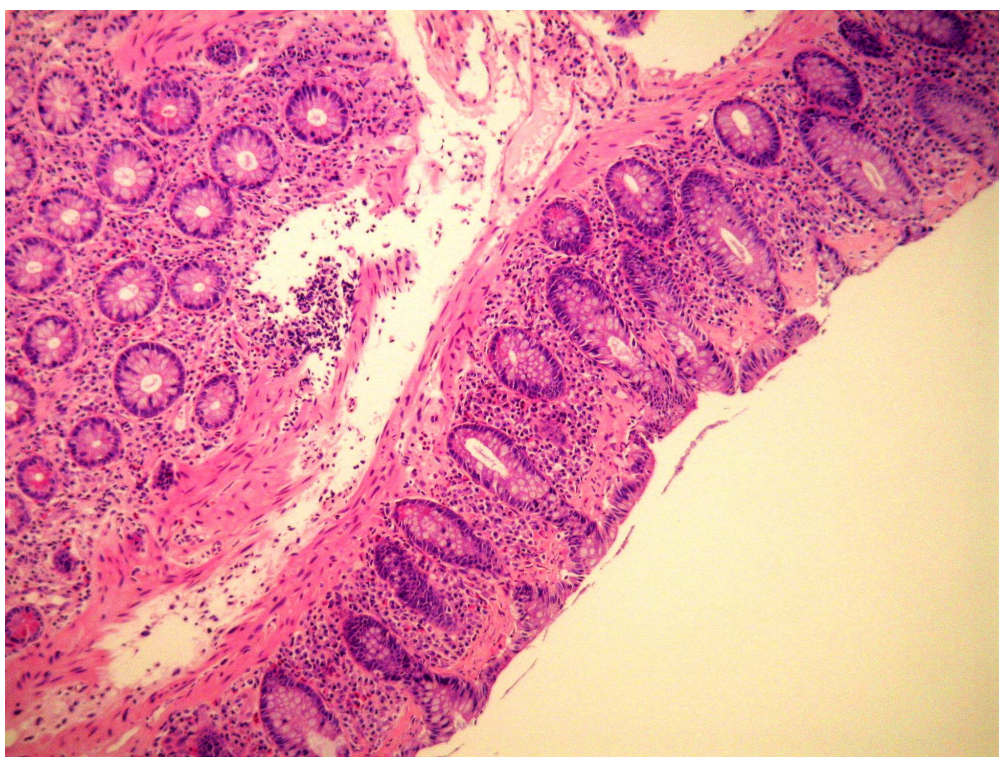


Fig -6 Collagenous colitis. H&E x400

Discussion

Most frequent patients in the current study were in the 4th decade of life and nearly equal male to female ratio. Most common presenting symptom was chronic diarrhea found in 40% and their histopathological diagnoses were mainly lymphocytic colitis in 16 patients(40%), followed by non specific colitis (30%), normal histopathology (22.5%), and collagenous colitis(7.5%).

In this study, microscopic colitis (lymphocytic and collagenous) was found in 47.5% of patients with chronic diarrhea and normal colonoscopy, which is near to 42% reported in France by Gineston et.al ⁽¹¹⁾. While higher than those reported by Prior et al in England 4 % ⁽¹²⁾. Lee et al in Korea 18 % ⁽¹³⁾. and 14% which was found by Marshall et al. ⁽¹⁴⁾.

Non specific colitis was diagnosed in 30% in patients with chronic diarrhea which is higher than those reported by Yusoff et al ⁽¹⁵⁾, which was reported only in 0.4%.

This great difference can be explained by small size of sample in current study or the histopathologists were over diagnosed the cecal biopsy as a microscopic or non specific colitis especially when there is clinical suspicion of those diseases.

The collagenous colitis which was found in 3% of normal colonoscopy female patients, and all presented with chronic diarrhea, and affect middle age group, which agree with other reported studies ⁽¹⁶⁾.

Normal Histopathological results were found in 57% of cases in this study and 22.5% in patients with chronic diarrhea, which is disagree with that mentioned by other study ,which was 84.9% ⁽¹⁷⁾.

Conclusion

The colonic biopsy from patients with normal colonoscopic findings especially those with chronic diarrhea are mandatory to reach or exclude diagnosis especially of microscopic colitis.

References

- 1.Shobna j Bhatia, Rakesh A., B Ramakrishna. Indian Journal of Gastroenterology. 2007; Vol 26 september-October. Page: 249.-250
- 2.Geobesk Ectors N,DHaensG,Rutgeerts P.Is ileoscopy biopsy worthwhile
- 3.Pardi DS: microscopic Colitis Mayo Clinic Proc.78, 2003; p: 614. www.pathoidia.com/path link
- 4..Dasilva JG,D,Brito T, citra Damio Ao,Ludonna AA,Siphai AM.Histologic Study of colonic mucosa in patients with chronic diarrhea and normal colonoscopic findings Gastroenterol Hepatol 2006;40:1-2.
- 5.Vinay Kumar, K Abbas, N. Fausto: Robbins and Cotran Pathologic Basis of Disease, 7th edition: Elsevier Saunders, 2005; pp: 840-841.
- 6.Theodore M.Bayless, M.D., B., W.J.R.National Digestive Diseases Information Clearinghouse (NDDIC). NIH publication No. 06-5036.January 2006.
- 7.JOHN .H .SINARD.Microscopic colitis, John Hopkins Atlas of Surgical Pathology, 1996; p 129.
- 8.Harris G.Y Fantis, MD.chief, Gastrointestinal Pathology. section.<http://www.netautopsy.org/axso.P: 184.htm>.
- 9.Arthur Schoenstadt, MD: Microscopic colitis.2009.<http://www.emedtv.com/>
- 10.Juan Rosai MD .Rosai And Ackerman's, Surgical Pathology. Ninth edition, china: Mosby, Volume 2, 2004; p791.

11. Gineston JL, Sevestre H, Descombes P, Viot J,Sevenet F, Davion T, et.al. Biopsies of the endoscopically normal rectum and colon: a necessity. Incidence of collagen colitis and microscopic colitis. *Gastroenterol Clin Biol* 1989; 13:360-3.
- 12.Prior A, Lessells AM, Whorwell PJ. Is biopsy necessary if colonoscopy is normal? *Dig Dis Sci* 1987; 32:673-6.
- 13.Lee JH, Rhee PL, Kim JJ. Kohn KC, Park SW, Han JH, et.al. The type of mucosal biopsy in the diagnosis of chronic diarrhea: value of multiple biopsies when colonoscopic finding is normal or non specific. *Korean J Intern Med* 1997; 12:182-7.
- 14.Mashall JB, Singh R, Diaz-Arias AA. Chronic, unexplained diarrhea: are biopsies necessary if colonoscopy is normal? *Am J Gastrointest* 1995; 90:372-6.
- 15.Yus off. IF. Ormonde DG, Hoffman NE. Routine colonoscopy for diarrhea. *J Gastroenterol Hepatol* 2002; 17:276-80.
- 16.Podolsky DK: Inflammatory bowel disease .*N Engl J Med* 2003; 347:417.
- 17.Kenneth D.Fine, MD, Richard H.Seidel, MD, Kim .The prevalence, anatomic distribution, and diagnosis of colonic causes of chronic diarrhea.2000; 51(3): p 318-324.