

# INNATE IMMUNE RESPONSES OF ILT VIRUS INFECTION IN LAYER AT PRODUCTION STAGE IN Iraq

Basim Manswr<sup>1</sup>

Mushtaq Talib Bakr Al-Zuhariy<sup>2</sup>

Amjed Hussein Ulaiwi<sup>2</sup>

Saad Mohammed Hammad<sup>2</sup>

1. College of Veterinary Medicine, University of Diyala

2. College of Veterinary Medicine, University of Baghdad

[mushtaq.t@covm.uobaghdad.edu.iq](mailto:mushtaq.t@covm.uobaghdad.edu.iq), <https://orcid.org/0000-0001-6635-7609>.

## ABSTRACT

Since 2011, there have been epidemics of respiratory infection in Iraq's laying hen farms, including hemorrhage tracheitis, which closely resembles laryngotracheitis and exhibits symptoms such as symptoms and lesions, respiratory issues, and swelling. Infectious laryngotracheitis (ILT) in layers hen farms in Iraq had to be molecularly identified and determined, together with viral load and innate immune responses of gene transcription (INF- $\gamma$ , IL1, IL6, and IL10). A total of 40 samples 20 trachea and 20 lungs were taken from various suspect contaminated layer flocks of Iraqi farms (age: 33 weeks). Real-time PCR results showed that 10 samples from both tissues tested positive for the ILT virus. The highest viral load,  $5.52 \times 10^3$  copies/L viral nucleic acid, was found in tracheal tissue at 7 dpi, whereas the lowest viral load,  $1.65 \times 10^3$  copies/L viral nucleic acid, was found in lung tissues. At 3 and 7 days after infection, the expression of INF- $\gamma$ , IL1 and IL6 was significantly higher there in tracheal tissues ( $P \leq 0.05$ ) than in the lung tissues, indicating a down regulation of these three molecules. In both organs at the same time, there was no up regulation of IL10. The findings of this study show that ILTV up-regulates the transcription of several cytokines in the trachea, including INF- $\gamma$ , IL1, and IL6, during various stages of the cytokine production process.

**Key words:** Viral load, IFN- $\gamma$ , RT-PCR.

## INTRODUCTION

Chickens upper respiratory are susceptible to infectious laryngotracheitis (ILT) (Bagust et al., 2000), which is Descends to alpha herpesvirus infectious laryngotracheitis virus (ILTV; Gallid herpesvirus 1). (Devlin et al., 2006). This virus mostly affects the conjunctiva, nasal, and tracheal epithelium; symptoms typically include coughing, dyspnea, and ocular or nasal exudates. These clinical symptoms may be accompanied by a reduction in weight gain or egg production (Gowthaman, et al., 2020). ILTV can also enter the neurological system after lytic infection (Gowthaman, et al., 2020; Coppo et al., 2018), where it creates a latent infection (Coppo, et al., 2013). Worldwide, ILTV has an impact on the poultry industry. Enzootic types of the illness can have high rates of morbidity (80%) and mortality (usually 10–20%), which decrease animal welfare and cause farmers to suffer large financial losses (Coppo, et al., 2018). An identifiable subset of cytokines and chemokines were immune response associate genes that had enhanced transcription during ILT infection (Lee, et al., 2010). Immune response associate genes that demonstrated enhanced transcription during ILT infection were a specific subset of cytokines and chemokines (Lee, et al., 2010). In response to microorganisms and antigens, immune system cells create cytokines, which play a role in controlling inflammatory and immunological reactions. They function by adhering to their cell surface receptor, and their biological processes involve activating the target cell's genes, which may make immune cells more active or multiply (B-cells, T-cells, macrophages, and natural killer cells). One cytokine has the capacity to influence a variety of cell types, some cytokines perform many tasks, and some cytokines promote the production of

other cytokines. Pro-inflammatory cytokines generated by hens include interleukin (IL)-1, IL-6, IL-8, and IL-18 (Göbel, et al., 2003; Kaiser et al., 2003). Together with their pro-inflammatory effects, certain cytokines are also important for controlling and enhancing the adaptive immunological response of T helper (Th) cells. Cytokines are thought to be regulated by transforming growth factor (TGF) and IL-10. IL-2, INF- $\gamma$ , IL-12, IL-15, IL-16, and IL-18 are type I (Th1) cytokines that support cell-mediated reactions. The cytokines IL-3, IL-4, IL-5, and IL-13 of type II (Th2) are supportive of humoral immune responses (Schat, et al., 2014). A single cytokine can have an impact on a variety of cell types. Cytokines can also serve many purposes, and some can encourage the creation of additional cytokines. Interleukin-1 (IL-1), IL-6, IL-8, and IL-18 from chickens are pro-inflammatory cytokines (Göbel, et al., 2003; Kaiser et al., 2003). Together with their pro-inflammatory effects, certain cytokines are also important for controlling and enhancing the adaptive immunological response of T helper (Th) cells. Cytokines are thought to be regulated by transforming growth factor (TGF) and IL-10. Type I (Th1) cytokines such as IL-2, INF- $\gamma$ , IL-12, IL-15, IL-16, and IL-18 promote cell-mediated responses. The cytokines IL-3, IL-4, IL-5, and IL-13 of type II (Th2) are supportive of humoral immune responses (Heidari, et al., 2008). The primary approach for diagnosing viruses is DNA detection by real-time or conventional polymerase chain reaction (PCR) (Valones, et al., 2009, Schaad and Frederick, 2002). Due to its increased quickness, sensitivity, repeatability, and low danger of carryover contamination, real-time PCR has acquired widespread adoption (Mackay, 2004). It has been demonstrated that ILTV real-time PCR assays are effective for detecting and quantifying ILTV DNA. This method allowed researchers to identify and quantify the amounts of ILTV DNA present in the tissues of hens that had been exposed to the virus at various points in time and in clinical instances. In this study, the innate immune profile, singing, and lesions provide additional information about the interaction between the ILT and the host.

## **MATERIALS AND METHODS**

### **Ethical approve**

The regulations of the vice president's office for research at the Universities in Diyala and Baghdad were followed when collecting data from all laying hen farms using specialized tools and practicing veterinarians.

### **Sample collections**

A total of 40 samples 20 trachea and 20 lungs were taken from various suspect contaminated layer flocks of Iraqi farms (age: 33 weeks). Several farms are dealing with nasal discharge, conjunctivitis, reduced egg production, gasping, coughing, expectorating bloody mucus, and severe dyspnea that could cause asphyxia.

### **Histopathological changes**

Microscopic examinations of upper trachea sections stained with H&E and taken at 3 and 7 days after the ILT infection samples (Fischer, et al., 2004).

### **DNA extractions and real-time PCR**

Using the follow the manufacturer for the TIANamp Gdna Kit, genomic DNA of the ILTV was extracted from tissues that had been obtained and were infected (the trachea and the lungs) (TIANGEN, Beijing, China). The LightCyclerR480 was used to carry out the real-time PCR (Roche Diagnostics GmbH, Mannheim, Germany). The primers (5'TTCCGAGATCGAAGAAGTGAG 3'; 5'ACTCTGGTGGTGGCAAGTATCCTGT 3') were created to amplify a 567 bp segment in accordance with the consensus sequence of the gB gene (Zhao, et al., 2013).

### Host cell mRNA and ILTV transcripts quantitation

In order to extract DNA for PCR analysis from the specimen's infected tissues, a pair of gB Forward/Reverse primers based on the ILTV gB gene were used. Primer sets for cytokine and ILTV mrna quantification IFN- and IL-6 (Kaiser et al., 2003) amplification primers have been used in the past. IL-1 and IL10 cytokine and amplification primers were previously disclosed (Ecco, et al., 2011; Rue, et al., 2011) (Tab. 1). The expression of fold changes for each cytokine transcript for tissues was estimated using the method  $CT = (CT_{\text{target}} - \text{actin})$  (Schmittgen and Livak, 2008). Previously published strategies for the internal standard -actin's amplification (Ecco, et al., 2011).

Table 1 contains the primers used to quantify the expression of the cytokine mRNAs.

Gene		Sequence	Amplicon size (bp)
IFN- $\gamma$	FW	GTGAAGAAGGTGAAAGATATCATGGA	70
	RV	GCTTTGCGCTGGATTCTCA	
IL1- $\beta$	FW	GCTCTACATGTCGTGTGTGATGAG	100
	RV	TGTCGATGTCCCGCATGA	
IL-6	FW	GCTCGCCGGCTTCGA	70
	RV	GGTAGGTCTGAAAGGCGAACAG	
IL-10	FW	AGGTGAAATCTGGCAGTGGAAAT	93
	RV	ACCTGGACGCTGAATGCAA	

### Statistical analysis

Apollo 7 was employed to conduct the data's data analysis (GraphPad, Software Inc. San Diego, CA, USA).

## RESULTS AND DISCUSSION

### Clinical pathology

Five to twelve days after infection, laying hens exhibited symptoms such as gasping, rattling, coughing up bloody mucoid exudate, and elongation of the neck during inspiration. In laying flocks, decreased productivity can play a variety of roles. Birds with the condition are anorexic and inactive. Edema of the conjunctiva, nasal turbinates, sinuses, larynx, and trachea are among the lesions. The tracheal mucosa may exhibit mucoid exudate and noticeable congestion. Furthermore, bleeding of the trachea's mucosal surfaces is frequently observed. The findings of tracheal tissues' 3 dpi histopathology revealed the production of syncytial cells with light deciliation and a number of intranuclear inclusion bodies (Fig 1).

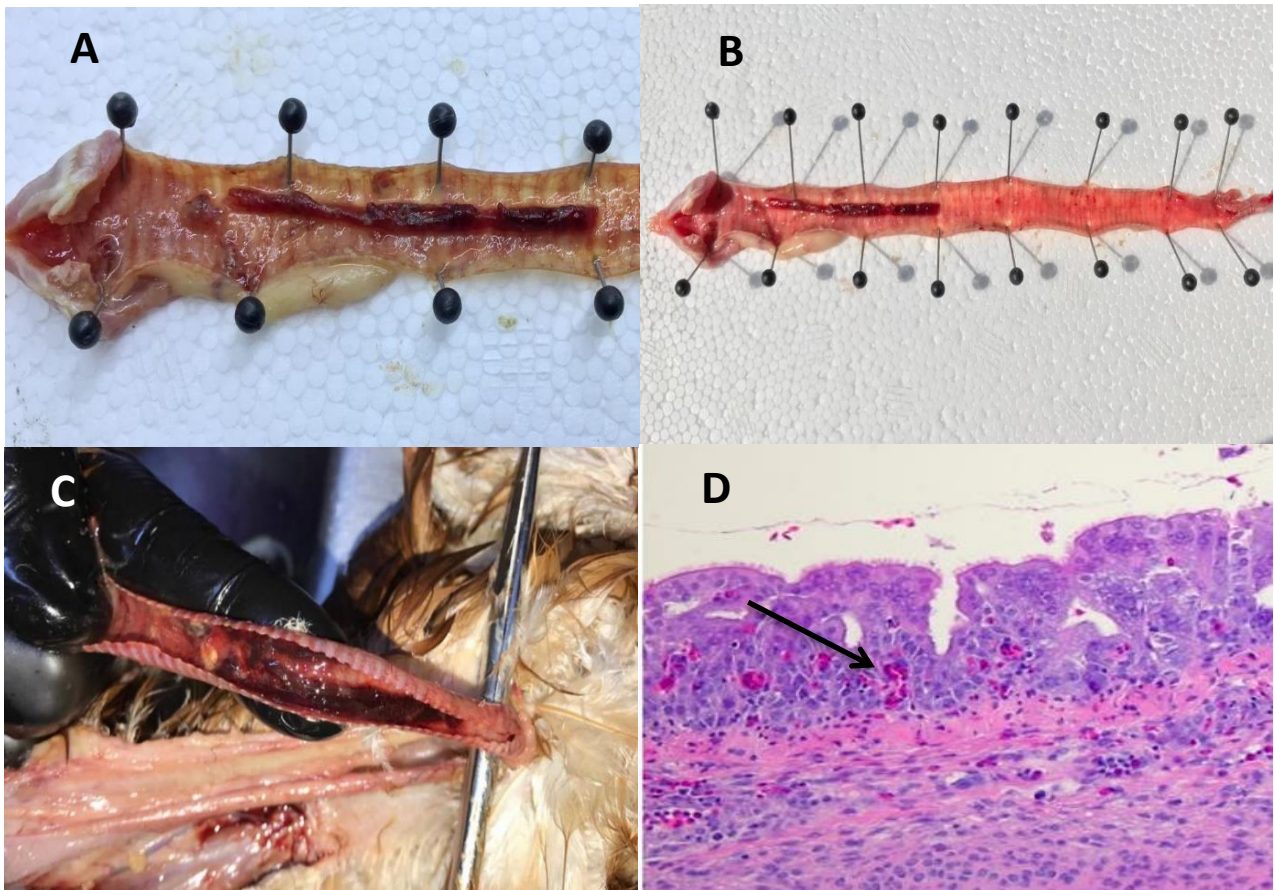


Figure 1. (A, B, C); Trachea of a broiler chicken presenting edema, congestion, and hemorrhage of the mucosal surfaces. Collected trachea at 3 dpi displaying syncytial cell development and many intranuclear inclusion bodies (H & E 10X).

The examination of real-time PCR (viral load) revealed highly significant ( $P \leq 0.05$ ) rates of infection in tracheal tissues, which were  $5.52 \times 10^3$  copies/ L at 3 dpi and  $2.542 \times 10^3$  in the heart. The lowest virologic values were found in the lung ( $1.65 \times 10^3$ ) despite the fact that the viral load in tracheal tissues at 7 dpi was  $2.39 \times 10^3$  copies/ L.

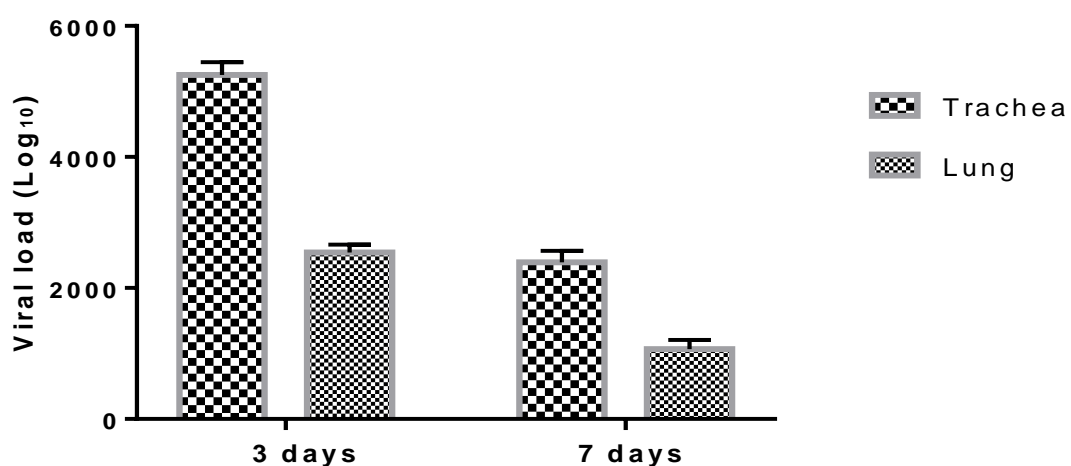


Fig.2: PCR analysis of ILTV DNA copies (viral load) in tracheal and lung tissues at 3 and 7 days after infection.

In contrast the lung tissue, which showed down regulation at the same time, the results of (INF- $\gamma$ , IL1, and IL6) mRNA gene expression at 3 days showed a highly significant upregulation ( $P \leq 0.05$ ) in tracheal tissue. In compared to the lung, which has the lowest gene expressions, the trachea showed

a marginally significant ( $P \leq 0.05$ ) upregulation of these genes expression in tracheal tissue at 7 days. All tissues did not exhibit an increase in IL-10 during that time (Figure 3).

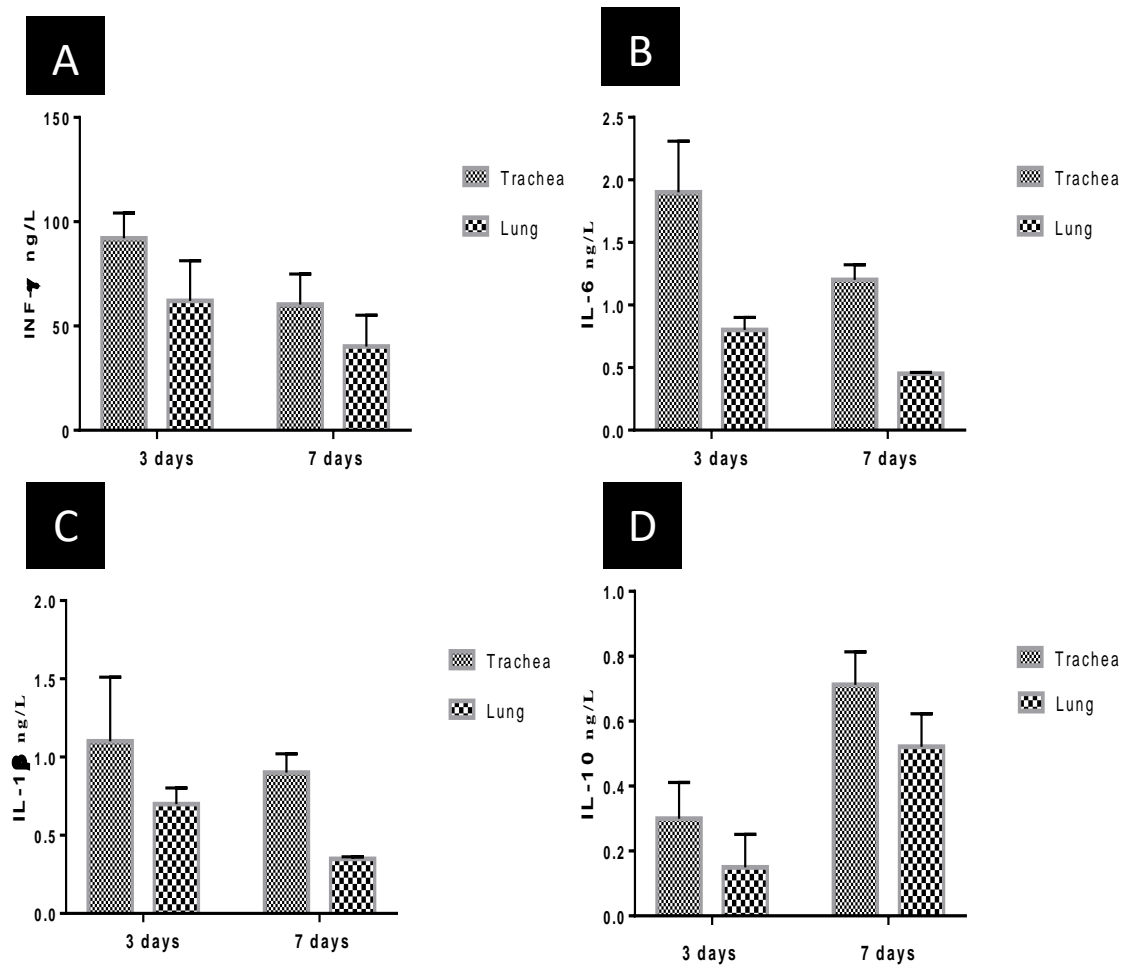


Fig. 3: Gene expression of cytokines transcripts mean fold changes (A:INF- $\gamma$ , B:IL1, C:IL6 and D:IL10) in tracheas and lung at 3- and 7-days post infection.

Lesions and symptoms were perfect for ILT spontaneous infection, as previously documented (Preis, et al., 2013). This virus mostly affects the ocular, nasal, and tracheal epithelium; symptoms typically include coughing, dyspnea, and ocular or nasal exudates these clinical manifestations in laying hens can be accompanied by decreased weight gain or decreased egg output (Preis, et al., 2013). This study's goal was to examine how major cytokine genes were expressed in conjunction with viral replication in the trachea and lung following ILT infection in layer hens at the early stages of infection (Coppo et al., 2018). When compared to lung tissue, the trachea showed a marked rise in viral genome loads after three days. simultaneously to the 7 dpi. These outcomes lined up exactly with (Vagnozzi, et al., 2018). A normal mucosal epithelium persisted but intranuclear inclusion bodies were present, indicating that viral replication had begun in the trachea at 3 days after infection. The viral genome load in the lung peaked at 3 days after infection and then started to diminish 7 days later. These similar to the study conducted the conclusions of (Vagnozzi, et al., 2018). When the tracheal mucosal epithelium was still intact at 3 days' post-infection, there was an increase in type I interferon gene transcription upregulated, which has been reported to imply that ILTV infection may cause early antiviral. manufacturing. It was additionally interesting to note that the INF- $\gamma$  gene's production was activated during infection. Yet from 3 dpi to 7 dpi, there was an overexpression of



the INF- $\gamma$  gene, which was timed to the migration of elector cells to the trachea. These results are in line with all those made public by Coppo et al. (2018) & Vagnozzi (2018). This alteration in INF- $\gamma$  transcription was accompanied by an increase in virus replication in the producing chickens' tracheas. Overall, these findings imply that shortly after ILTV infection, fast INF- $\gamma$  expression may activate antiviral mechanisms that prevent early virus multiplication. The residual neutrophil concentrations inside the lung primary cell culture are most likely what is causing the transcription upregulation of top player genes (chCXCLi1, chCXCLi2, and IL6) that was observed in the first-generation chicken embryo lung cells following ILTV infection. We saw IL-1 transcriptional increase in the mucous membrane of trachea from 3 dpi to 5 dpi, which is consistent with Coppo *et al.* (2018). The chCXCLi2 acts as an angiogenesis factor and a chemotaxis factor to draw macrophages and dendritic cells and cells to apparently site of infection (Poh, et al., 2008). There has also been evidence of a powerful antiviral response induced by IL-1 that is dependent on the NF-B innate antiviral pathway in cases of human virus - associated virus infection (Bose, et al., 2003). Hepatoblastoma cell line antiviral response to IL-1 receptor induction against the virus that causes hepatitis B has been demonstrated. But what we noticed IL1 mRNA expression in the lungs significantly increased, while ILTV replication both in vitro and in vivo significantly decreased (Haddadi, et al., 2015). More research is required to determine whether the antiviral action of ILTV relies on the level of IL-1 induction. As this is happening, IL-1 interacts with interleukin-1 receptor type I (IL-1R type I), causing the production of immune-related molecules that trigger a series of inflammatory events. Monocytes and macrophages, as well as epithelial and endothelial cells, all express IL-1 (Gyorfy, et al., 2003). Consequently, during an acute ILTV infection, increased IL-1 gene transcription causes the recruitment to neutrophils and macrophages to the airway. systemic inflammation IL-1 gene expression in Between 3 dpi to 7 dpi, the laryngeal epithelial membrane was associated with the sequence of the IL-10 gene. An inducible regulator known as chicken IL-10 has already been found to reduce immune reactions (Wu, et al., 2016). Recent in vitro investigations utilizing conjunctival and trachea mucosal explants or tracheal tissue cultures (Reddy, et al., 2014). Coppo *et al.* (2018) demonstrated that the substantial damage to the tracheal epithelium seen during acute ILTV contamination is significantly influenced by the host inflammatory response. In line with earlier research, it is clear from the current study that the peak of inflammatory transcriptional activation occurred at the same time as heightened inflammation, significant tissue damage, and viral replication inside the trachea.

## **Conclusion**

The study was concluding the ILTV causes an up-regulation of INF- $\gamma$ , IL1, and IL6 in the airways and pulmonary tissue. This rise in cytokine production in both organs is related to the viral load. These findings might help in the creation of new strategy to activate actual defenses against ILTV.

## **Acknowledgments**

The authors are thankful to Al-Rashidia flocks company for providing the samples for this study. The authors gratefully acknowledge Dr. Ganapathy and Julian Chantrey for guiding us through processing the data of this article.

## **Conflict of interest**

To the knowledge of the investigator, there are no conflicts of interest related to the publishing of the whole study.

## **Reference:**

1. Bagust, T., Jones, R. & Guy, J. (2000). Avian infectious laryngotracheitis. *Revue scientifique et technique* (International Office of Epizootics). 19(2):483-92. DOI: [10.20506/rst.19.2.1229](https://doi.org/10.20506/rst.19.2.1229)
2. Bose, S., Kar, N., Maitra, R., DiDonato, J.A., & Banerjee, A.K. (2003). Temporal activation of NF- $\kappa$ B regulates an interferon-independent innate antiviral response against cytoplasmic RNA viruses. *Proceedings of the National Academy of Sciences*. 100(19):10890-5. DOI: [10.1073/pnas.1832775100](https://doi.org/10.1073/pnas.1832775100)
3. Coppo, M.J., Devlin, J.M., Legione, A.R., Vaz, P.K., Lee, S.W., & Quinteros, J.A., (2018). Infectious laryngotracheitis virus viral chemokine-binding protein glycoprotein G alters transcription of key inflammatory mediators in vitro and in vivo. *Journal of Virology*. 92(1):1534-17. DOI: [10.1128/JVI.01534-17](https://doi.org/10.1128/JVI.01534-17)
4. Coppo, M.J., Noormohammadi, A.H., Browning, G.F. & Devlin JM. (2013). Challenges and recent advancements in infectious laryngotracheitis virus vaccines. *Avian Pathology*.;42(3):195-205. DOI: [10.1080/03079457.2013.800634](https://doi.org/10.1080/03079457.2013.800634)
5. Devlin, J., Browning, G., Hartley, C., Kirkpatrick, N., Mahmoudian, A. & Noormohammadi, A. (2006). Glycoprotein G is a virulence factor in infectious laryngotracheitis virus. *Journal of general virology*. 87(10):2839-47. DOI: [10.1099/vir.0.82194-0](https://doi.org/10.1099/vir.0.82194-0)
6. Ecco, R., Brown, C., Susta, L., Cagle, C., Cornax, I., & Pantin-Jackwood, M. (2011). In vivo transcriptional cytokine responses and association with clinical and pathological outcomes in chickens infected with different Newcastle disease virus isolates using formalin-fixed paraffin-embedded samples. *Veterinary immunology and immunopathology*. 141(3-4):221-9. DOI: [10.1016/j.vetimm.2011.03.002](https://doi.org/10.1016/j.vetimm.2011.03.002)
7. Fischer, A.H., Jacobson, K.A., Rose, J., & Zeller, R. (2008). Hematoxylin and eosin staining of tissue and cell sections. *Cold spring harbor protocols*. (5):4986. DOI:[10.1101/pdb.prot073411](https://doi.org/10.1101/pdb.prot073411)
8. Göbel, T.W., Schneider, K., Schaerer, B., Mejri, I., Puehler, F., & Weigend, S. (2003). IL-18 stimulates the proliferation and IFN- $\gamma$  release of CD4<sup>+</sup> T cells in the chicken: conservation of a Th1-like system in a nonmammalian species. *The Journal of Immunology*. 171(4):1809-15. DOI: [10.4049/jimmunol.171.4.1809](https://doi.org/10.4049/jimmunol.171.4.1809)
9. Gowthaman, V., Kumar, S., Koul, M., Dave, U., Murthy, T.G.K. & Munuswamy, P. (2020). Infectious laryngotracheitis: Etiology, epidemiology, pathobiology, and advances in diagnosis and control—a comprehensive review. *Veterinary Quarterly*.;40(1):140-61. DOI: [10.1080/01652176.2020.1759845](https://doi.org/10.1080/01652176.2020.1759845)
10. Gyorfy, Z., Ohnemus, A., Kaspers, B., Duda, E., & Staeheli, P. (2003). Truncated chicken interleukin-1  $\beta$  with increased biologic activity. *Journal of interferon & cytokine research*. 23(5):223-8. DOI: [10.1089/107999003321829935](https://doi.org/10.1089/107999003321829935)
11. Haddadi, S., Thapa, S., Kameka, A., Hui, J., Czub, M., Nagy, E., (2015). Toll-like receptor 2 ligand, lipoteichoic acid is inhibitory against infectious laryngotracheitis virus infection in vitro and in vivo. *Developmental & Comparative Immunology*. 48(1):22-32. DOI: [10.1016/j.dci.2014.08.011](https://doi.org/10.1016/j.dci.2014.08.011)
12. Heidari, M., Huebner, M., Kireev, D., & Silva, R.F. (2008). Transcriptional profiling of Marek's disease virus genes during cytolytic and latent infection. *Virus Genes*. 36:383-92. DOI [10.1007/s11262-008-0203-7](https://doi.org/10.1007/s11262-008-0203-7)
13. Kaiser, A., Bercovici, N., Abastado, J.P., & Nardin, A. (2003). Naive CD8<sup>+</sup> T cell recruitment and proliferation are dependent on stage of dendritic cell maturation. *European journal of immunology*. 33(1):162-71. DOI:[10.1002/immu.200390019](https://doi.org/10.1002/immu.200390019)

14. Lee, J.Y., Song, J.J., Wooming, A., Li, X., Zhou, H., & Bottje, W.G., (2010). Transcriptional profiling of host gene expression in chicken embryo lung cells infected with laryngotracheitis virus. *BMC genomics*. 11(1):1-15. DOI: [10.1186/1471-2164-11-445](https://doi.org/10.1186/1471-2164-11-445)
15. Mackay, I.M. (2004). Real-time PCR in the microbiology laboratory. *Clinical microbiology and infection*. 10(3):190-212. DOI: [10.1111/j.1198-743x.2004.00722](https://doi.org/10.1111/j.1198-743x.2004.00722)
16. Poh, T.Y., Pease, J., Young, J.R., Bumstead, N., Kaiser, P. (2008). Re-evaluation of chicken CXCR1 determines the true gene structure: CXCL1 (K60) and CXCL2 (CAF/interleukin-8) are ligands for this receptor. *Journal of Biological Chemistry*. 283(24):16408-15. DOI: [10.1074/jbc.M800998200](https://doi.org/10.1074/jbc.M800998200)
17. Preis, I.S., Braga, J.F., Couto, R.M., Brasil, B.S., Martins, N.R., & Ecco, R. (2013). Outbreak of infectious laryngotracheitis in large multi-age egg layer chicken flocks in Minas Gerais, Brazil. *Pesquisa Veterinária Brasileira*. 33:591-6. DOI: [10.1590/S0100-736X2013000500007](https://doi.org/10.1590/S0100-736X2013000500007)
18. Reddy, V.R., Steukers, L., Li, Y., Fuchs, W., Vanderplasschen, A., & Nauwynck, H.J. (2014). Replication characteristics of infectious laryngotracheitis virus in the respiratory and conjunctival mucosa. *Avian pathology*.;43(5):450-7. DOI: [10.1080/03079457.2014.956285](https://doi.org/10.1080/03079457.2014.956285)
19. Rue, C.A., Susta, L., Cornax, I., Brown, C.C., Kapczynski, D.R., & Suarez, D.L., (2011). Virulent Newcastle disease virus elicits a strong innate immune response in chickens. *Journal of general virology*. 92(4):931-9. DOI: [10.1099/vir.0.025486-0](https://doi.org/10.1099/vir.0.025486-0)
20. Schaad, N.W., & Frederick, (2002). R.D. Real-time PCR and its application for rapid plant disease diagnostics. *Canadian journal of plant pathology*. 24(3):250-8. DOI: [10.1080/07060660209507006](https://doi.org/10.1080/07060660209507006)
21. Schat, K.A., Kaspers, B., & Kaiser, P. (2014). *Avian immunology*: Elsevier Philadelphia, USA; 2014. DOI: [10.1016/B978-0-12-396965-1.00009-1](https://doi.org/10.1016/B978-0-12-396965-1.00009-1)
22. Schmittgen, T.D., & Livak, K.J. Analyzing real-time PCR data by the comparative CT method. *Nature protocols*. 3(6):1101-8. DOI: [10.1038/nprot.2008.73](https://doi.org/10.1038/nprot.2008.73)
23. Vagnozzi, A.E., Beltrán, G., Zavala, G., Read, L., Sharif, S., & García, M. (2018). Cytokine gene transcription in the trachea, Harderian gland, and trigeminal ganglia of chickens inoculated with virulent infectious laryngotracheitis virus (ILTV) strain. *Avian Pathology*. 47(5):497-508. DOI: [10.1080/03079457.2018.1492090](https://doi.org/10.1080/03079457.2018.1492090)
24. Valones, M.A.A., Guimarães, R.L., Brandão, L.A.C., Souza, P.R.E., Carvalho, A. & Crovela, S. (2009). Principles and applications of polymerase chain reaction in medical diagnostic fields: a review. *Brazilian Journal of Microbiology*. 40:1-11. DOI: [10.1590/S1517-83822009000100001](https://doi.org/10.1590/S1517-83822009000100001)
25. Wu, Z., Hu, T., Rothwell, L., Vervelde, L., Kaiser, P., Boulton, K. (2016). Analysis of the function of IL-10 in chickens using specific neutralising antibodies and a sensitive capture ELISA. *Developmental & Comparative Immunology*. 63:206-12. DOI: [10.1016/j.dci.2016.04.016](https://doi.org/10.1016/j.dci.2016.04.016)
26. Zhao, Y., Kong, C., Cui, X., Cui, H., Shi, X., & Zhang, X., (2013). Detection of infectious laryngotracheitis virus by real-time PCR in naturally and experimentally infected chickens. *PloS one*. 8(6):67598. DOI: [10.1371/journal.pone.0067598](https://doi.org/10.1371/journal.pone.0067598).

دراسة مناعية مرضية لاصابة فيروس التهاب الحنجرة والرغامي المعدي للدجاج البيض في مرحلة الإنتاج

باسم محمد منصور<sup>1</sup>, مشتاق طالب بكر<sup>2</sup>, أمجد حسين عليوي<sup>2</sup>, سعد محمد حمد<sup>2</sup>

قسم الامراض وامراض الدواجن، كلية الطب البيطري، جامعة ديالى – العراق<sup>1</sup>

قسم الامراض وامراض الدواجن، كلية الطب البيطري، جامعة بغداد – العراق

[mushtaq.t@covm.uobaghdad.edu.iq](mailto:mushtaq.t@covm.uobaghdad.edu.iq), <https://orcid.org/0000-0001-6635-7609>.



## المستخلص

منذ عام 2011، كانت هناك أوبئة مع اضطرابات في الجهاز التنفسي في مزارع الدجاج البياض في العراق، مثل علامات وأفات، وصعوبات في التنفس، والتهاب القصبات النزفية، والتي تشبه إلى حد بعيد التهاب الحنجرة والقصبات. هدفت هذه الدراسة إلى الكشف الجزيئي وتحديد الحمل الفيروسي والاستجابات المناعية الانية والتعبير الجيني  $INF-\gamma$ ,  $IL1$ ,  $IL6$  and  $IL10$  والتهاب الحنجرة والحنجرة المعدية في قطعان الدجاج البياض في العراق. من مجموع 40 عينة (20 القصبة الهوائية، 20 رئة) من قطعان مشتبه بإصابتها بالتهاب الحنجرة والحنجرة المعدية (عمر 33 أسبوعاً) مع من المزارع العراقية. أظهرت نتائج RT-PCR أن 10 عينات كانت إيجابية لفيروس التهاب الحنجرة والحنجرة المعدية من كلا النسجين. تم تسجيل الحمل الفيروسي  $10^3 \times 5.52$  نسخة / ميكرو لتر للحمض النووي الفيروسي في أنسجة القصبة الهوائية بعمر 7 أيام بعد الإصابة في القصبة الهوائية بينما ينتج عن أدنى حمل فيروسي  $10^3 \times 1.65$  نسخة / ميكرو لتر من الحمض النووي الفيروسي في أنسجة الرئة بعمر 7 أيام بعد الإصابة. كانت هناك تعبيرات أعلى ( $P \leq 0.05$ )  $INF-\gamma$ ,  $IL1$ , and  $IL6$  في أنسجة القصبة الهوائية مقارنة بأنسجة الرئة في 3 و 7 أيام بعد الإصابة التي تظهر انخفاض في  $INF-\gamma$  و  $IL1$  و  $IL6$  في 3 و 7 أيام بعد الإصابة. لم يكن هناك زيادة في  $IL10$  في كلا الأنسجة في نفس الوقت الفترة. نتائج هذه الدراسة تبين أن التهاب الحنجرة والحنجرة المعدية أعلى نسخ للحمض النووي / ميكرو لتر في القصبة الهوائية جنباً إلى جنب مع الزيادة للسيتوكينات  $INF-\gamma$ ,  $IL1$ , and  $IL6$  في القصبة الهوائية خطوات مختلفة من السلسلة الالتهابية، وبالتالي تغيير الالتهاب، والفوعة، وتوازن الاستجابة المناعية لعدوى التهاب الحنجرة والحنجرة المعدية.

**الكلمات المفتاحية:** الحمل الفيروسي،  $INF-\gamma$  ، تفاعل البوليميرز المتسلسل.