

Missed And Delayed Diagnosis Of Diaphragmatic Hernia: A Case Report

Mohammed Tafash Dagash M.B.Ch.B, FICMS
Instructor Department of Surgery College of
Medicine Anbar University Iraq- Al-Anbar-Fallujah
E-Mail :m_tafash@yahoo.com

introduction

Rupture diaphragm may follow a penetrating , crushing or deceleration injury. Most ruptures occur in the left hemidiaphragm & most are centrally situated . Herniation of stomach , spleen, omentum & small bowel may occur through the defect ,& often these structures are themselves traumatized by the injurious forces applied.⁽¹⁾

Rupture of the diaphragm complicates severe blunt external trauma or crushing injuries to the abdomen (5 %) or chest (1%)

most diaphragmatic ruptures occur on the left side .⁽²⁾

Traumatic diaphragmatic hernia is a serious consequence of blunt abdominal trauma from road traffic accident (RTA). It has been reported to occur in between 3-8% of patients after major blunt trauma to the abdomen.^(3,4)

There are two phases of the condition :

1. Immediate consequences of rupture (Shock, Pain ,blood loss,Haemoperitoneum or haemothorax)
2. Effects of migration of abdominal viscera into chest (displacement of pulmonary, cardiac & mediastinal contents, abdominal visceral obstruction or perforation)

There are 5 signs of a ruptured diaphragm ,none of which is particularly reliable :

- 1.Diminished chest excursion .
- 2.Impaired chest wall resonance .
- 3.Absence of retraction of the intercostals spaces on diaphragmatic movement .
- 4 .Adventitious gastrointestinal sounds in the chest .
5. Cardiac displacement .

Traumatic diaphragmatic hernia may present as acute or late as missed hernia.

History, clinical examination & radiological investigation need to diagnoses the condition. The diagnosis is obvious if abdominal viscera are seen in the hemithorax (fig.2). contrast Studies of the gastrointestinal tract (fig.3) or computed tomography (fig.4) may sometimes be needed to confirm the diagnosis.

Treatment

Reduction of the contents of the hernia & primary suture repair via the abdominal approach are usually all that is required ,at which time associated abdominal injuries can discovered & treated .

Old diaphragmatic ruptures are best treated by thoracotomy so that adhesions to the lung & chest wall can be lysed .⁽⁵⁾

In this report we discuss the late presentation of traumatic diaphragmatic hernia

Case Report

A 36-year-old female patient married before 16 years ,with 6 pregnancy deliver 6 baby, The body weight was 55 kg and height 150 cm. complain from dyspnea .

Past history with car accident since childhood (6 year old)., clinical examination scaphoid abdomen (Fig.1).

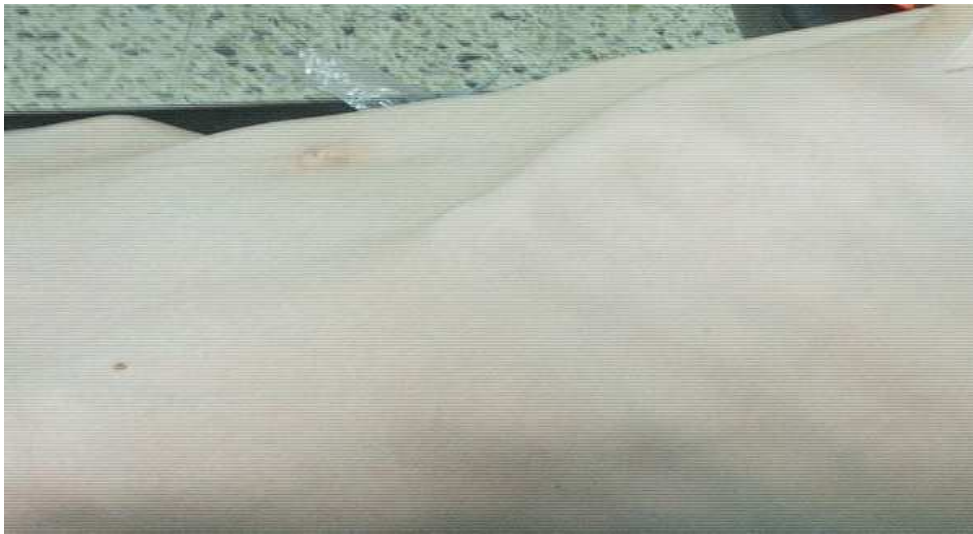

Fig.1 showing scaphoid abdomen .

bowel sound in the left side of chest Preoperative laboratory results were within normal ranges.

Chest-x-ray show bowel in the left hemithorax as seen in (fig.2)

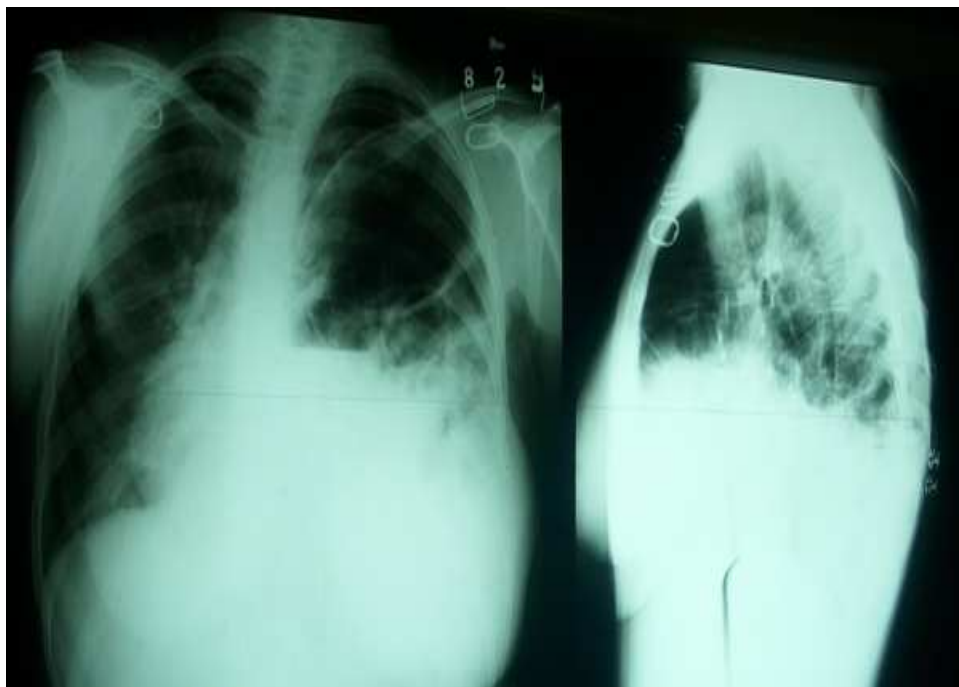

Figure 2: PA & lateral Chest X-ray (erect) showing rupture of the left hemidiaphragm with loops of colon in the left chest.

Contrast studies (Barium swallow) showing most part of stomach intrathoracic with gastroesophageal junction intraabdominal (Fig.3)

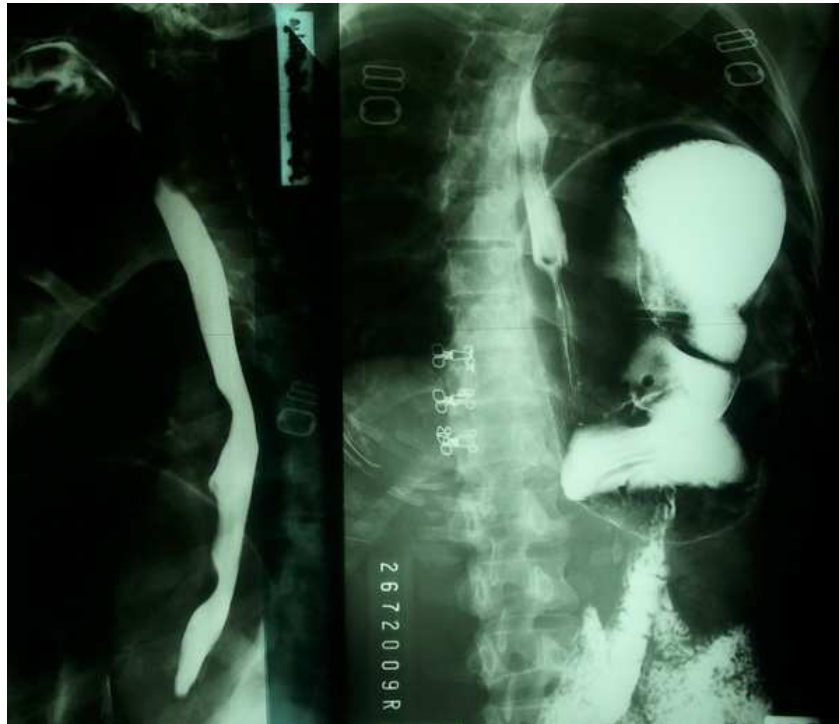

Fig. 3 Barium swallow (erect) showing most part of stomach intrathoracic with part of colon & esophagal compresion.

CT scan of the chest was done & confirm the diagnoses as see in fig .4.

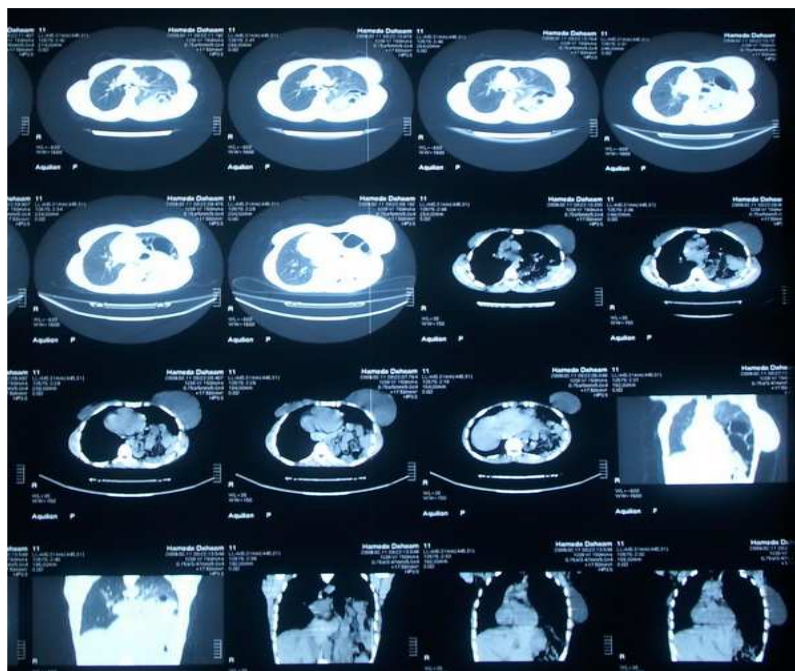


Fig.4. Chest CT scan showing rupture of the left hemidiaphragm with loops of colon, stomach in the left chest.

Through the left lower (7th intercostals space) thoracotomy finding stomach, colon, part of left lobe of liver, omentum & part of small bowel herniation through the defect with adhesion to the pericardium, anterior & posterior part of defect (posteriolateral defect: Bochdalek hernia)

As see in fig.5.

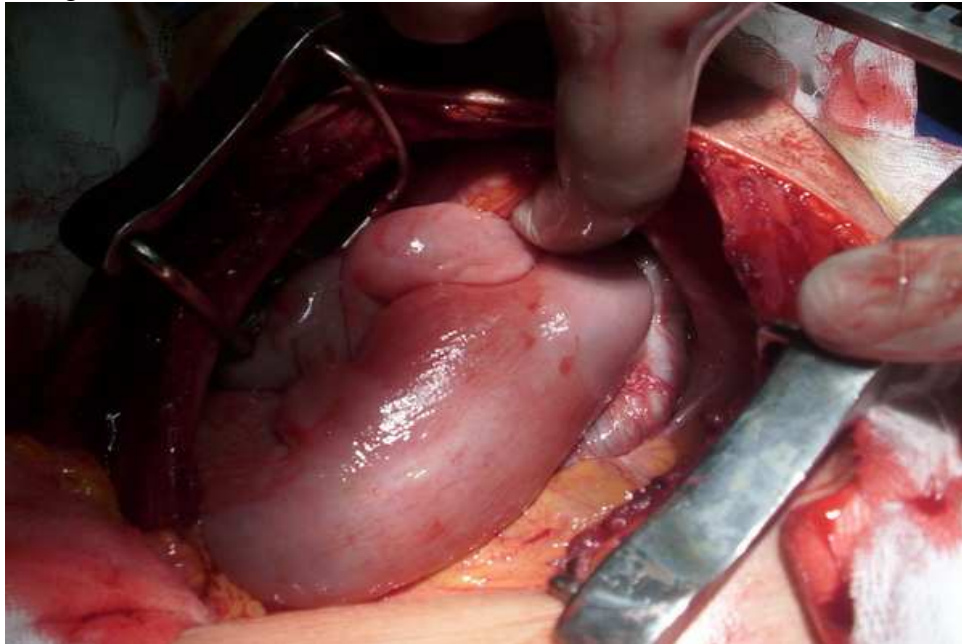


Fig.5 Intraoperative show ,stomach, small bowel ,colon herniation through the defect.

Reduction of abdominal contents ,repair of diaphragmatic rupture (Fig 6 ,7,drainage of pleural cavity, left abdominal drain ,nasogastric tube & bladder folly ,then close the chest in layer. The patient has recovered uneventfully.

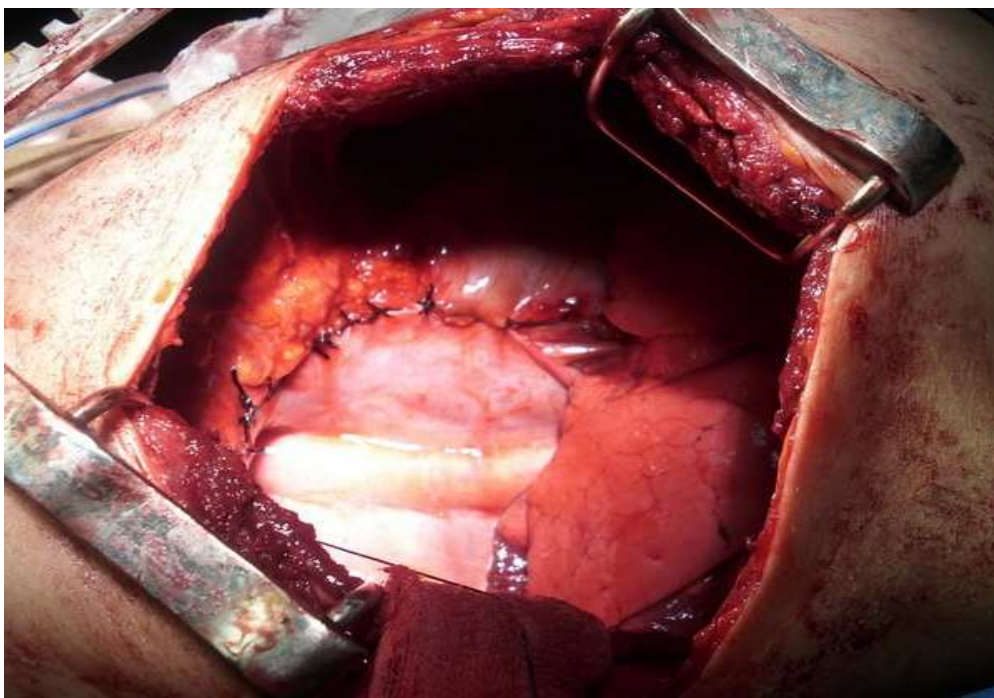


Fig.6.intraoperative show reduction of abdominal contents ,lung ,thoracic aorta & repair the defect .

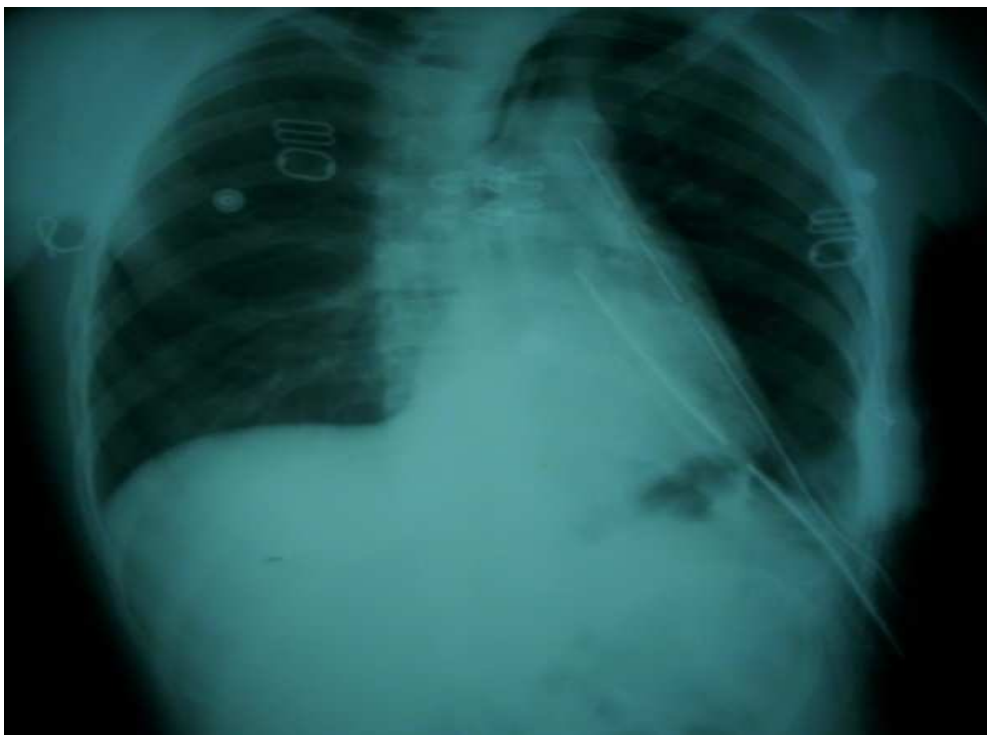


Fig.7 Chest X-ray (erect) postoperative showing reduction the abdominal contents, chest drain. abdominal drain & reduce the mediastinal to central part (look for fig1 above).

Discussion:

The present report is the first case report in our series where late presentation of diaphragmatic hernia.

Delayed diagnosis of traumatic diaphragmatic hernia is not unusual as in this case, especially when there was no chest symptom at the time of the trauma and there was another injury, which distracted any attention to the diaphragmatic rupture.^(6,7)

At the time of injury ,close scrutiny of the plain erect chest X-ray for diaphragmatic elevation or irregularity, pleural effusion ,left lower rib fractures or shift of mediastinal structures may indicate diaphragmatic rupture.

This presentation is also similar to other reports from the literature, where diaphragmatic elevation was an incidental finding in an asymptomatic diaphragmatic rupture, which was later diagnosed 30 years after an automobile accident⁽⁸⁾

The most reported site of affection is the left hemi-diaphragm as in this case report.^(8, 9, 10)

The herniated organs in the chest cavity in this case report were the stomach large intestine , small intestine & part of liver. This is similar to the findings in some reported cases where the spleen and left kidney did not herniate into the chest cavity.^(8,9)

Abdominal approach for early diaphragmatic ruptures to deal with intraabdominal injuries.

While old diaphragmatic ruptures are best treated by thoracotomy so that adhesions to the lung & chest wall can be lysed.

In conclusion:

Traumatic diaphragmatic hernia still incidental discover.

Occasionally bowel sounds heard through the chest wall help to suggest the diagnosis, which is frequently overlooked.

References:

1. Scott an Aid to clinical surgery 6th edition ,by Robin C.N.Williamson & Bruce P.Waxman, 1998, chapter 14 p.126.
2. Scott an Aid to clinical surgery 6th edition ,by Robin C.N.Williamson & Bruce P.Waxman, 1998, chapter 24 p.241.
3. Killeen KL, Shanmuganathan K, Mirvis SE. Imaging of traumatic diaphragmatic injuries. Semin Ultrasound, CT, MR. 2002 Apr; 23(2): 184-92.
4. Vermillion JM, Wilson EB, Smith RW. Traumatic diaphragmatic hernia presenting as a tension fecopneumothorax. Hernia, 2001, Sept. 5(3): 158-60.
5. Atlas of cardiothoracic surgery. L.Henry Edmunds, JR., M.D. 1999 p.238.
6. Lerner CA, Dang H, Kutilek RA. Strangulated traumatic diaphragmatic hernia stimulating a subphrenic abscess. J Emerg Med. 1997, Nov - Dec; 15(6): 849-53.
7. Zimmermann T. An unusual trauma in labour: Diaphragmatic rupture. Zentrald Gynakol. 1999; 121(2): 92-4.
8. Wataya H, Tsuruta N, Takayama K, Mitsudomi T, Nakanishi Y, Hara N. Delayed traumatic hernia diagnosed with MRI. Nihon Kyobu Shikhan Gakkai Zasshi 1997 Jan 35(1): 124-8.
9. Pojarliev T, Tzvetkov I, Blagov J, Radionov M. Laparoscopic repair of traumatic rupture of the left diaphragm cupola with prosthetic mesh. Surg Endosc. 2003 Apr; 17 (4): 660. Epub 2003 Feb 10.
10. Kawasaki C. Maekawa M. Two cases of traumatic-diaphragmatic hernia. Nippon Geka Hokan. 1998 Dec. 1; 67 (3-4): 72-7.