

Closed reduction With percutaneous pinning versus Open reduction and internal fixation in the treatment of extension supracondylar humeral fractures

Dr.Wejdi A. Al -Fatlawy
M B CH B, FICMS
Surgical department
Orthopedic branch
Medical Collage, Kufa University

دراسة مقارنة في معالجة كسر فوق اللقمة للعضد الأطفال

الكثير من الاهتمام انصب على مشاكل اعوجاج كسر فوق اللقمة للعضد في الاطفال .الاعوجاج الانسي والوحشي نسب في الماضي لانقباض النمو في الصفيحة العظمية السفلى للعضد أكثر من انتسابها لسوء التعديل . لقد عالجتنا ٧٢ حالة من كارتلاند ٣ لكسر فوق اللقمة للعضد خلال الفترة من تشرين الثاني ٢٠٠٦ الى كانون الاول ٢٠٠٩ (متابعة لمدة سنتين) في مستشفى المناذرة ،مستشفى الحكيم ومستشفى الصدر . ٣٦ حالة عولجت بالطريقة المغلقة وتثبيت الداخلي و ٣٦ حالة عولجت بالطريقة المفتوحة والتثبيت الداخلي للاطفال للفئة العمرية من ٥ الى ١٢ سنة . وقد كانت النتائج في ما يتعلق بالطريقة المغلقة ممتازة في ١٧ حالة (٤٧ %) وجيدة في ١٢ حالة (٣٣ %) ومقبولة في ٦ حالات (١٧ %) وضعيفة في حالة واحدة (٣ %) بينما كانت النتائج في الطريقة المفتوحة والتثبيت الداخلي ممتازة في ١٠ حالات (٢٨ %) وجيدة في ١٠ حالات (٢٨ %) ومقبولة في ١١ حالة (٣٠.٥ %) وضعيفة في ٥ حالات (١٣.٥ %). لقد استنتجنا ان الطريقة المغلقة هي افضل من الطريقة المفتوحة لانها تقلل وقت الشفاء وتعطي نتائج وظيفية مثلى مع احتمال ضعيف بلاصابة بالتهاب.

Abstract

Background: - much attention has been paid to the problem of malreduction of supracondylar fractures of the humerus in children .in past, cubitus varus or cubitus valgus frequently thought to occur because of growth arrest of the distal humeral physis rather than because of malreduction of the fracture.

Patient and methods: -We managed 72 patients with Gartlands type three supracondylar humeral fractures. fractures during the period between November 2006 and December 2008(with two years follow up)at al Sader and al Manathera hospitals .There were 36 cases treated by closed reduction with Percutaneous pinning method and 36 cases treated by open reduction and internal fixation method in five to twelve years old children.

The results:-The results were assessed by using the modified scoring system of Flynn et al ,Regarding closed reduction and Percutaneous pinning method, the outcome was excellent in17(47%), good in 12(33%), and fair in 6(17%)case, and poor in1(3%) but with the open reduction and internal fixation method the outcome was excellent in10(28%), good in10(28%), fair in 11(30.5%) and poor in 5(13.5%).

Conclusions:-We concluded that the closed reduction and Percutaneous pinning method is superior to open reduction and internal fixation method in that it shortens the average time for healing and it offers a good functional factors with minimum risk of infection.

The aim of the study The aim of this study is to determine whether closed reduction and Percutaneous pinning method results in a better outcomes at tow years follow up

after the injury compared with those after open reduction and internal fixation. In the treatment of Gartlands type three posterior supracondylar humeral fractures in children.

Introduction

Supracondylar humeral fractures are among the commonest fractures seen in children. The distal fragment may be displaced either posteriorly or anteriorly^(1,2, 3,4,5,6,7). It is a fracture through the distal metaphysis .I.e. it is proximal to distal physis. Improvements in technology, particularly in the field of fluoroscopy, have allowed surgeons to carefully select injuries and facilitate the peroperative insertion of percutaneous pins⁽⁸⁾. In children, the supracondylar region appears as an area of thin, weak bone located in the distal humerus. .The medial and lateral columns of the distal part of the humerus are connected by a thin segment of bone between the olecranon fossa posteriorly and the coronoid fossa anteriorly, resulting in a high risk of fracture to this area^(8, 9). With a fall on an extended elbow, the olecranon engages the olecranon fossa and acts as a fulcrum. The resulting injury is an extension-type supracondylar humeral fracture⁽⁸⁾. Supracondylar fractures account for up to 60 percent of pediatric elbow fractures 98% of extension type^(10,11,12,13,14). They occur most frequently in children in first decade of life in boys more than girls. It results from a fall on an outstretched arm in up to 70 percent of patients. The non-dominant extremity is most commonly affected (mostly in the left side)^(1, 2, 3, 4, 5) Supracondylar fractures are classified into extension and flexion types. The Gartlands classification system is used to describe the extent of the injury .it may be classified according to severity and degree of displacement .Type 1 is minimally displaced fracture, Type 2 is displaced with intact posterior cortex. Type 3 is a completely displaced fracture^(2, 6, 7, 8, 9). On x-ray, The fracture line occurs at or near the olecranon fossa. On a true lateral radiograph of a normal elbow, the anterior humeral line should cross the capitellum through its middle third. In an extension-type supracondylar fracture, the capitellum is posterior to this line^(1,2,3,4,5,6,7,15,16). As seen on the anteroposterior view, The Baumann angle is formed by the line perpendicular to the long axis of the humeral shaft and the physal line of the lateral (capitellar) condyle. The Baumann angle is decreased in varus angulation and increased in valgus angle^(10,12,13,14,17,18, 19, 20). regarding the treatment there are different methods 1-closed reduction and POP splinting. 2-closed reduction and immobilization in shoulder spica . 3-Dunlop skin traction. 4-overhead olecranon skeletal traction. 5-closed reduction and Percutaneous pinning. 6-open reduction and internal fixation using K. wires^(1,2,4,5,7,12,14,15,16,17,.). Regarding **Complications** of this fracture :**Vascular injury** and resultant Volkmanns ischemia which need urgent treatment ,other wise it leads to Volkmann's ischeamic contracture .Emergent reduction and stabilizing should be performed^(2,7,10). **Nerve injury** of ulnar ,median or radial nerve which are mostly temporary of the neuropraxia and recover spontaneously⁽¹⁰⁾. **Malunion** which is either cubitus varus or cubitus valgus. Cubitus varus is most common angular deformity .It is due to either improper reduction or due to redisplacement after manipulation. It does not affect the function but can cause ugly (gunstock) deformity which need surgical correction^(1, 2, 3,4,5,6,7,10). **Joint Stiffness** is common complication treated with active exercise (10). **Myositis ossificance** is rare complication. **Pin Track Infections** has ranged from <1% to 21%⁽²⁾. Most of them respond to oral antibiotics and local pin care, rarely they required intravenous antibiotics^(17, 18, 19).

Patients and methods

A prospective study done from November 2006 to December 2008, we managed 72 cases of closed supracondylar fractures at al Sader, and al Manathera hospitals to evaluate the best method for treatment of these types of fractures with follow up of 6-18 months(mean follow up was nine months). In this study; we had selected only cases of closed supracondylar fractures in children with age ranging from 5-12 years old (the mean age is 6.5 years) who were otherwise healthy and carried no systemic diseases or illnesses .All patients were diagnosed as being a case of closed supracondylar fractures clinically confirmed by plane X-rays films. The patients included in this study were chosen according to **criteria of exclusion** which include: 1-open fractures. 2- Delayed entry into the study more than 3 weeks after the initial injury.3- Patients with other medical disease like metabolic bone disease, diabetes mellitus or congenital heart diseases. 4- The patients with both closed supracondylar fracture and any ipsilateral upper limb injury.5- non-displaced fracture.6-cases subjected to previous surgery on the ipsilateral humerus. The patients with acute injury were first received in the casualty unit or as an outpatient in the orthopedic clinic and diagnosed as an injury to the distal humerus. The radial pulse and capillary refilling were examined then the arm was carefully placed in 30° of POP back slab .We avoided a tight bandaging. The arm was gently elevated. Analgesia is given to the patients. The patients are sent then to the X-ray department for two views (anteroposterior and lateral views) and for two limbs, Baumann's angle of normal side was recorded. Then when the fracture of the displaced Gartlands type 3 humeral supracondylar regions is confirmed, the patients are admitted to the orthopedic ward for definitive management. In the theater, An initial attempt of closed reduction was done for all our patients at first. All the patients were operated under general anesthesia with supine position .the fracture was manipulated to correct the rotational deformity of distal fragment or lateral tilt and lastly the posterior displacement. the elbow then flexed and by the guide of fluoroscopy two crossed K. wires were introduced one medially and other laterally(we intended to make the crossing in the proximal fragment rather than in the distal fragment or at the fracture site). the elbow then extend as possible to get a lateral view and from the anteroposterior view at freeze screen picture, Baumann's angle was evaluated and compared with that of normal side and if it was accepted(the difference between the two was less than 4 degrees) ,Wires would be bent and cut to facilitate future removal , the operation would finished and the elbow then immobilized in 90degrees flexion with P.O.P. back slab and sling , other wise we will shift to open reduction and internal fixation. Successful closed reduction was achieved for 36 cases. So In rest 36 cases, open reduction was required. Open reduction by the posterior approach was done by the same pin construct. We prefer posterior approach over lateral as it gives a good exposure of fracture site. Additionally we gave pre-operative antibiotics (either cefatoxime alone or combination of ampicilline, cloxacilline and gentamicine according to what antibiotic available in the hospital) with induction of anesthesia. Postoperatively, back slab was removed after a period of 3 weeks, at the end of which active assisted mobilization was started. Wires were removed on the appearance of callus, which were 3 weeks for closed pinning and approximately 5 weeks for open pinning. Patients were examined on 5th day, 10th day, 3 weeks, 6 weeks and 3 months, 6 months, 9 months, one year and 18 month for assessment of nerve injury, stiffness, deformity, elbow range of motion and infection.

The Results

The following data were used for all patients in our study:-name, age, sex, date of injury, date of presentation, cause of injury (just simple fall or fall from height), and any history of previous surgery .On examination, we put following point in consideration: - which limb is injured, vascular injury, nerve injury. X-ray findings were recorded in an anteroposterior view and lateral view. Any varus malalignment or valgus malalignment were noticed. Treatment whether closed reduction with Percutaneous pinning:-1- POP cast and elevation; for how long? 2- Back slab and elevation; for how long? 3- Time of union or open reduction and internal fixation:-1-Type of fixation.2- Intra-operative complications.3- post-operative complications for both methods.

In this study the results were as following: Sex 50(69%) males and 20(31%) females and the male to female ratio was 2.5:1, regarding the side of the injury, left side was in 45cases (62.6%) and in the right side 27 case (37, 5). Regarding the cause of injury: 28(38.8%) cases were due simple fall and 44(61.1%) cases due to fall from height. We divided the cases into two groups; group one included the cases who were treated by closed reduction and percutaneous pinning (36 cases). Group two included the cases that were treated by open reduction and internal fixation (36 cases). The operation was performed on the first day in 42 cases (58, 3%), between 4 and 7 days following trauma in 25 cases (34, 7%), and between the 8 and 10 day 5 cases (7%). In this study all the cases were treated are type 3 Gartlands classification. The cases were followed up according to the **modified scoring system of Flynn et al**^(18, 21) which are 1-the time of union. 2-iattrogenic neurovascular injury. 3-the range of motion, 4- the infection rate^(18, 21) as in table no. 1. The mean union time depending on clinical and radiological signs of group one was 4 weeks while that of group two was 7 weeks. The mean of score regarding range of motion in elbow joints in group one was 160⁰ and that of group two was 140⁰. The prognosis was Excellent for 27 patients (17 with CR&PP and 10 with OR& IF), Good for 22 patients (12 with CR&PP and 10 with OR&IF), Fair for 17 patients (6 with CR&PP and 11 with OR&IF), poor for 6 patients (1 with CR&PP and 5 with OR&IF) as in table no. 2. The score was directly proportional to the Baumann, s angle. There is a relation between the prognosis and type of treatment, there is better higher results with closed reduction and Percutaneous pinning method than with open reduction and internal fixation method. There is no relation between the side of injury and gender of patient with the score. The final outcome of supracondylar fractures was directly proportional with the quality of reduction and type of treatment. So fractures treated by closed reduction and percutaneous pinning is associated with better outcome than those fractures treated by open reduction and internal fixation. Infection following treatment of displaced supracondylar humeral fractures is almost always as a pin track infection which resolved with oral antibiotic treatment .Deep infection and osteomyelitis are rare. Table (1): the relation between the parameters used modified scoring system of Flynn et al.

| Parameters | state | Score | state | Score | state | Score |
|------------------------------------------|--------|-------|---------|-------|--------|-------|
| 1-range of (movement at elbow) extension | 0-180 | 3 | 0-140 | 2 | 0-<100 | 1 |
| 2- time of union in weeks | 3-5 | 3 | 6-8 | 2 | <8 | 1 |
| 3- iatrogenic neurovascular injury | absent | 2 | Present | 1 | | |
| 4-the infection | absent | 2 | present | 1 | | |

Table 2 shows the scoring system for each method of treatment.

| Scoring | CR&PP | OR&IF |
|-----------|-------|-------|
| Excellent | 17 | 10 |
| Good | 12 | 10 |
| Fair | 6 | 11 |
| Poor | 1 | 5 |

Table 3 shows the prognosis of each scoring System.

| The score | The prognosis |
|-----------|---------------|
| 9-10 | Excellent |
| 7-8 | Good |
| 6-5 | Fair |
| 4 | Poor |

Table 4 shows the postoperative complication .

| Type of complication | Patient treated by CR&PP | | Patient treated by OR&IF | |
|----------------------------|--------------------------|---------|--------------------------|---------|
| | number | percent | number | percent |
| 1-loss of extension | 8 | 28% | 18 | 50% |
| 2-infection | 2 | 4,5% | 6 | 17% |
| 3-iatrogenic nerve injury: | 1 | 3% | 3 | 9% |
| 4 vascular injury | 0 | 0% | 0 | 0% |
| 5-Malunion: | 0 | 0% | 0 | 0% |

Discussion

The goal of treatment of a pediatric supracondylar fracture is to restore alignment to a position where there is no varus malalignment and the anterior humeral line intersects the capitular ossification center ⁽⁸⁾. Significant controversy remains over the results of CR&PP versus OR&IF treatment of supracondylar humeral fractures ⁽⁶⁾.

In this study, the sample was 72 cases with male to female ratio 3:2(mean age was 7.5 years), 36 patients was treated closed reduction and Percutaneous pinning , 36 patients treated by open reduction and internal fixation and All are followed up for two years. The Percutaneous surgical approach to these fractures certainly plays a major role in achieving such low rates of infection.

E. Ippolito et al and Williams et al are among the researchers advocating only closed reduction and plaster application. this study agrees with our on conclusion but differs in scoring system (Ippolito scoring system) (19,20,21,22).

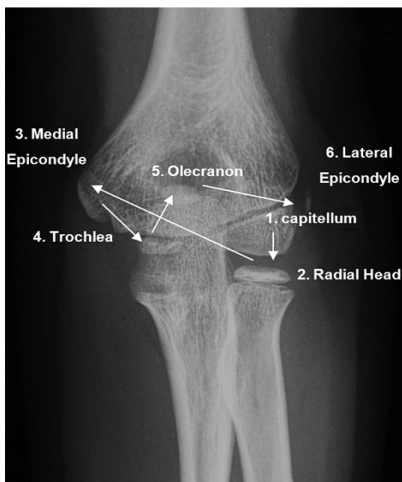
On the other hand Kurer et al have advocated open reduction internal fixation to achieve good results. This study disagreed with our in conclusion and in exclusion criteria which involve devascularised limb and open fractures which is not involved in our ⁽²³⁾.

However, most of the studies strongly favours closed reduction and Percutaneous pinning as the most successful modality of treatment. Excellent work by Barbara Minkowitz et al and Gordon JE, Patton CM, Luhmann SJ, Bassett GS, Schoenecker PL.in their study" Fracture stability after pinning of displaced supracondylar distal humerus fractures in children". have conclusively proved that closed Percutaneous pinning is the best treatment option for type 3 supracondylar fracture .they reach to a same results of our Although there are differences' in number of sample , age of patients and scoring system ^(18,23,24).

Various treatment modalities have been described for the treatment of this fracture. Flynn s et al study of 124 cases of Supracondylar fractures of the humerus in children are advocates only closed reduction and pinning .In their study with mean age of 5 years and with scores which less than our but we used same scoring system but with higher result ^(19,21).

We concluded that Closed reduction and cross Percutaneous pinning for displaced supracondylar humerus fractures in children is superior to open reduction and internal

fixation method in that it shortens the average time for healing and it offers a good functional factors with minimum risk of infection ,safe, cost and time effective method and gives stable fixation with excellent outcome.



Figure(1), Anteroposterior view of normal elbow joint

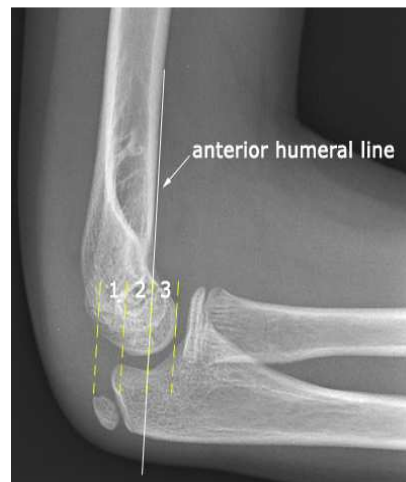
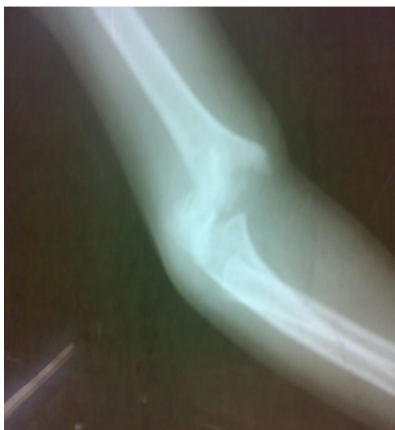
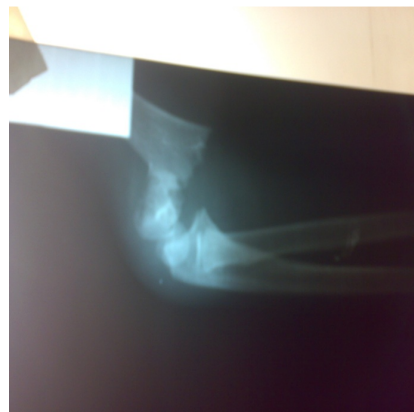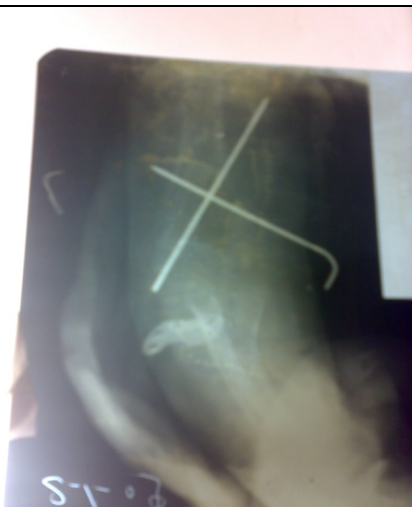Figure (2) Lateral view of normal elbow joint



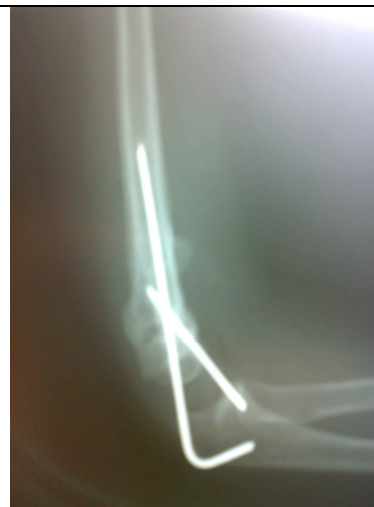figure(3) supracondylar fracture anteroposterior view group 1



Figure(4), supracondylar fracture lateral view group1



Figure(5), Postoperative, anteroposterior view of supracondylar fracture group 1



Figure(6), Postoperative lateral view of supracondylar fracture group 2

References

- 1-Louis Solomon,David J.Warwick,Selvzdur Nayagam,Apley, s system of orthopedics and fracture 8th edition, ARNOLD,newyourk,USA ,Apley, s system of orthopedics and fracture 8th edition, churchilstone ,UK,2001, 596-599.
- 2- S.TERRY CANAL ,MD ,Campell, s operative orthopedics' MOSBY, PENSELVANIA,Campell, s operative orthopedic vol.4.MOSBY,newyork,USA,2003, 437-1451.
- 3-American Academy of orthopedic surgeons OKU orthopedic knowledge updated 7 home study Syllabus; Nibraska ,USA,2002, 543-551.
- 4- American Academy of orthopedic surgeons OKU orthopedic knowledge updated 8 home study Syllabus; Nibraska ,USA 2005, 705-707.
- 5_ American Academy of orthopedic surgeons OKU orthopedic knowledge updated home study Syllabus; Nibraska ,USA 2007, 876-881.
- 6_LYNN T.STAHELI M.D.pediatric orthopedic secrets, ANLY & ELFUS INC.,philadelephia, ninth edition,1998,142-144.
- 7-MARK R.BRINKER M.D.review of orthopedic trauma, third dition,W.B.SAUNDERS COMPANY, philadelephia, 2003,422-426.
- 8- ANN M.R. AGUR ,ARTHUR F. DALLEY ,LIPPINCOTT WILLIAMS &WILKINS PHILADELIPHIA eleventh edition section 6, 2005, 505-509.
- 9- Richard s.snell MD, PHD, clinical anatomy for medical students 6th edition 2003, 551-554.
- 10-Mohhamed H. AL.Obaidi, ,adnan E.AL.Kelabi,,Ali M.AL.shidedi,F.R.C.S. department of orthopedic ,college of medicine percutaneous pinning of extension type supracondylar fractures, Kufa medical journal June 2001,81-86.
11. Pirone AM, Graham HK, Krajbich JI Kurer. Management of displaced extension type supracondylar fractures of the humerus in children, J Bone Joint Surg 1988; 70A : 641.
- 12-Oh CW, Park BC, Kim PT, Park IH, Kyung HS, Ihn JC. Completely displaced supracondylar humerus fractures in children results of open reduction versus closed reduction. J Orthop Sci 2003; 8 (2): 137-41.
- 13-Graves SC, Beaty JH. Supracondylar fractures of the humerus in children : treatment by closed reduction and pinning. Orthop Trans 1989; 13 : 540.
- 14-Beaty JH, Kasser JR. Fractures about the elbow. Instr Course Lect 1995; 44 : 199-215.
- 15-Wilkins KE. Supracondylar fractures : What's new? J Pediatr Orthop B 1997; 6 : 110-6.
- 16-Zionts LE, et al. Torsional strength of pin configurations used to fix supracondylar fracture of the humerus in children J Bone Joint Surg 1994; 76 (2).

- 17-Lee SS, Mahar AT, Miessen D, et al. Displaced pediatric supracondylar humerus fracture : biomechanical analysis of percutaneous pinning techniques. J Pediatr Orthop 2002; 22 : 440-3.
- 18- Flynn et al Supracondylar fractures of the humerus in children : treatment by closed reduction and pinning. Orthop Trans 2006;23 : 687-692
- 19-Supracondylar Humeral Fractures in Children Reza Omid, MD1, Paul D. Choi, MD1 and David L. Skaggs, MD1 Childrens Orthopaedic Center, Childrens Hospital Los Angeles, 2003,4650 Sunset Boulevard, MS 69, Los Angeles, CA 90027 .
- 20- Sibinski M, Sharma H, Bennet GC. Early versus delayed treatment of extension type-3 supracondylar fractures of the humerus in children. J Bone Joint Surg Br. 2006;88:380-389.
- 21-3. Flynn JC, Matthews JG, Benoit RL. Blind pinning of displaced supracondylar fractures of the humerus in children. Sixteen years' experience with long-term follow-up. J Bone Joint Surg Am. 1974;56:263-72.
- 22- E. Ippolito et al and Williams Management of displaced extension type supracondylar fractures of the humerus in children, J Bone Joint Surg 1998; 722A : 731.
- 23- Kurer et al, Iyengar SR, Hoffinger SA, Townsend DR. Early versus delayed reduction and pinning of type III displaced supracondylar fractures of the humerus in children: a comparative study. J Orthop Trauma. 1999;13:51-5.
- 24- Barbara Minkowitz et, Gordon JE, Patton CM, Luhmann SJ, Bassett GS, Schoenecker PL. Fracture stability after pinning of displaced supracondylar distal humerus fractures in children. J Pediatric Orthopedic. 2001;21:313-8.
- 25-Pirone AM, Graham HK, Krajchich JI. Management of displaced extension-type supracondylar fractures of the humerus in children. J Bone Joint Surg Am. 1988;70:641-50. Erratum in: J Bone Joint Surg Am. 1988;70:1114.