

The protective effect of vitamins A, D3 and E on testicular damage induced by ketoconazole in male mice

Rafid Muhammed Ali* Ahmed Thayer Alwan* Mphed Qasim Mohammed**

*Coll. of pharmacy / Univ. of Kufa **Coll. of education and pure sciences/ Univ. of Basra

email: r_wasfi@yahoo.com

(Received 21 October 2015, Accepted 13 December 2015)

Abstract

The study was aimed to evaluate the protective effect of the combination of multivitamins AD₃E against the testicular injury induced by using of ketoconazole in male mice. Eighteen adults male albino mice (*Mus musculus*) weighing about 25 gm and aged 60 days were utilized in this study. Animals were kept in same environmental conditions, and divided into three equal groups. Control group has been given olive oil (0.2 ml) orally by gastric gavage tube, and at the same time given normal saline (0.125 ml) injected intra peritoneally once daily for 10 successive days and consider as placebo. T1 group treated with ketoconazole 100mg/kg BW administered orally plus intra-peritoneal injection of (Vitol-140[®]) a combination of vitamins AD₃E in a dose of 400,000 IU/kg BW vitamin A, 200,000 IU/kg BW vitamin D₃, and 100mg/kg BW of vitamin E once daily for 10 successive days. T2 group were treated with ketoconazole alone in a dose of 100mg/kg BW given orally for 10 successive days. After 10 days animals were sacrificed, orchietomy was performed, and the testis was processed for histopathological examinations with light microscope after staining with (H&E) stain. Calculation of spermatogonia, primary and secondary cells were counted for 20 seminiferous tubules in treated and control groups. In T2 group there was massive destruction of the testicular tissue characterized by abnormal splintered architecture of the tissue. The cellular mass and density of the tubules were suppressed accompanied by a suppression of spermatogenesis process within the seminiferous tubules, with vacuolation of spermatogonia and presence of multinucleated spermatid giant cells. Also there was few number of Leydig cells between the seminiferous tubules in compared with control group. While in T1 group there was complete spermatogenesis within the seminiferous tubules. There were normal spermatogonia, primary and secondary spermatocytes and spermatid. Also there were a high numbers of Leydig cells between the seminiferous tubules, and the fields resemble that of control group. The number of primary and secondary spermatogonia was registered a significant difference between control and the treatment groups in all studied parameter (spermatogonia, the primary and the secondary cells). The mean number of spermatogonia in control group was significantly higher than (T2) group while no significant differences between control and the (T1) group. The mean number of primary and secondary spermatocyte show significant difference between control and (T2) groups. also there was a significant difference between (T1) and (T2) groups.

In conclusion the ketoconazole caused severe damage to the testicular tissue in mice which can be reversed by administration of multivitamins AD₃E.

Key words: Protective effect, vitamins AD₃E, testicular damage, mice, ketoconazole.

التأثير الوقائي للفيتامينات (أ، د₃ ، هـ) على الضرر الخصوي المحدث بالكيوتوكونازول في ذكور الفئران

رافد محمد علي* احمد ثاير علوان* مفيد قاسم محمد**
*كلية الصيدلة / جامعة الكوفة **كلية التربية للعلوم الصرفة / جامعة البصرة

الخلاصة

تهدف الدراسة إلى تقييم التأثير الوقائي لمزيج من الفيتامينات (AD_3E) ضد إصابة الخصية الناجمة من استخدام الكيتوكونازول في ذكور الفئران. واستخدمت في هذه الدراسة 18 من الفئران الذكور البالغة من نوع ألبينو (موس موسكولوس) وزنها حوالي 25 جرام والذي تتراوح أعمارها حوالي 60 يوماً. وضعت الحيوانات تحت نفس الظروف البيئية. وقسمت إلى ثلاث مجموعات متساوية. مجموعة السيطرة وقد أعطيت زيت الزيتون (0.2 مل) عن طريق الفم باستخدام أنبوب المعدة ، وفي نفس الوقت أعطيت المحلول الملحي الفسلجي (0.125 مل) بواسطة الحقن الخلي (داخل البريتوني) مرة واحدة يومياً لمدة 10 أيام متتالية واعتبرت مجموعة السيطرة الموهة. مجموعة المعالجة T1 وأعطيت عقار الكيتوكونازول 100 ملغم/كغم من وزن الجسم عن طريق الفم بالإضافة إلى الحقن الخلي لعقار® (Vitol-140) وهو مزيج من الفيتامينات AD_3E وبجرعة 400,000 وحدة دولية/كغم و 200,000 وحدة دولية/كغم من وزن الجسم لفيتامين (د3)، و 100 ملغم/كغم من وزن الجسم من فيتامين (هـ) مرة واحدة يومياً لمدة 10 أيام متتالية. وبعد 10 أيام تم التضحية بالحيوانات ، وإجراء عملية إزالة الخصى ، وتمت معالجة الخصية لغرض إجراء الفحوصات النسيجية باستخدام المجهر الضوئي بعد صبغها بصيغة الهيماتوكسلين ايسين. وجرى حساب الخلايا المولدة للنفث الأولية والثانوية في 20 نبيب منوي لكل من مجموعة السيطرة ومجاميع المعالجة. اظهرت النتائج ان مجموعة المعالجة T2 كانت تعاني من تدمير واسع النطاق لأنسجة الخصية تميز بتغيير الشكل الهندسي لنسيج الخصية. وقلة كثافة الكتلة الخلوية داخل الأنابيب المنوية مصحوبة بقلة تكوين الحيوانات المنوية داخل النبيبات المنوية ، مع تفجي الخلايا المولدة للنفث ووجود الخلايا المولدة للنفث العملاقة. كما كان هناك عدد قليل من خلايا ليديك Leydig (الخلايا بين النبيبات المنوية) مقارنة مع مجموعة السيطرة . بينما في مجموعة المعالجة (T1) كان هناك عملية توليد النفث وجدت كاملة داخل النبيبات المنوية. وكانت هناك خلايا مولدة للنفث طبيعية ، وخلايا اولية وثانوية طبيعية مع وجود اعداد كبيرة من خلايا ليديك ما بين النبيبات المنوية وكان المقطع مشابه للنسيج الطبيعي. سجلت اعداد الخلايا المولدة للنفث الاولية والثانوية فروقات معنوية عالية بين مجموعة السيطرة ومجاميع المعالجة. وكان معدل اعداد الخلايا المولدة للنفث في مجموعة السيطرة اعلى معنويًا من مجموعة المعالجة (T2) بينما لا يوجد فرق معنوي بين مجموعة السيطرة والمجموعة (T1). بينما يوجد فرق معنوي بين مجموعة السيطرة والمجموعة (T2) في عدد الخلايا الاولية والثانوية كما يوجد فرق بين مجموعتي المعالجة. نستنتج من ذلك ان الكيتوكونازول قد سبب تحطيم شديد لنسيج الخصية والذي يمكن عكسه باستخدام مجموعة الفيتامينات AD_3E .

الكلمات المفتاحية: التأثير الوقائي ، الفيتامينات (أ،د3،هـ) ، الضرر الخصوي ، فئران ، كيتوكونازول.

Introduction

Azole antifungals are broadly divided into imidazoles and triazoles. Both of them are structurally related compounds, have similar mechanism of action and antifungal spectrum. Azoles impair ergosterol synthesis by inhibiting 14α -demethylase enzyme. Ketoconazole (KET) is a prototype drug among azoles used topically for treatment dermatophytosis and use orally for treatment of oral, esophageal and vulvovaginal candidiasis (1). It is an antifungal drug that is a member of imidazole drug family (2). Ketoconazole is also used as an anticancer agent in the treatment of advanced prostate cancer. It has been shown to induce a dose-dependent decrease in serum testosterone levels in human being and in rats. The N-deacetyl KET is the major metabolite which undergoes further metabolism by the flavin-containing mono-oxygenase to form a potentially toxic reactive metabolite. It is reported also that KET inhibits C17-20 lyase which blocks the conversion of 17α -hydroxyprogesterone to andostenedione. It is found to decrease serum testosterone levels with no significant increase in serum

luteinizing hormone (LH) levels, and make suppresses negative feedback mechanisms in the pituitary by suppressing regulatory changes in LH and follicle stimulating hormone (FSH) secretion. Oligospermia and azoospermia have been reported at the therapeutic doses of KET. Ketoconazole was seen to make reduction in both testicular and epididymal weights as well as with depletion in the quality of epididymal sperm (sperm count and motility). It was induced testicular toxicity which further confirmed by histological alteration in the testis (3). Vitamin A (retinol) is required for maintenance of adult mammalian spermatogenesis in adult rodents, vitamin A withdrawal is followed by a loss of differentiated germ cells within the seminiferous epithelium and disrupted spermatogenesis that can be restored by vitamin A replacement. The process of spermatogenesis is influenced by both intrinsic and extrinsic factors, including vitamin A (retinol). Vitamin A is required for the maintenance of mammalian spermatogenesis, and most germ cells are lost

in vitamin A deficient (VAD) adult rodents. Vitamin A deficiency results in spermatogenic arrest at the stage of undifferentiated spermatogonia and preleptotene spermatocytes in rats or types A spermatogonia in mice, and retinol replacement results in the complete recovery of spermatogenesis (4). Vitamin A is critical for normal and continual sperm production, is clearly involved in type A spermatogonia proliferation, allows their differentiation into B spermatogonia and plays a major role for the entry into the meiotic process (5). Vitamin E (VE), a well-known antioxidant, plays an important role in scavenging free oxygen radicals and stabilizing the cell membranes. A number of studies have shown that VE pretreatment significantly protects testes against oxidative damage (6). Alpha (α -tocopherol (vitamin E) is one of eight forms of vitamin E. Vitamin E when administered before torsion of the spermatic cord in rats, provided significant protection against acute testicular injury (7). It has been recognized since the 1940s that vitamin E (α -tocopherol) is a powerful lipophilic antioxidant that is absolutely vital for the maintenance of mammalian spermatogenesis. It is present in particularly high amounts in Sertoli cells and spermatocytes and to a lesser extent round spermatids (8). The D vitamins are a group of sterols that have a hormone-like function. The active molecule, 1,25-dihydroxycholecalciferol (1,25-diOH-D₃), binds to intracellular receptor proteins. The 1,25-diOH-D₃-receptor complex interacts with DNA in the nucleus of target cells in a manner similar to that of vitamin A, and either selectively stimulates gene expression or specifically represses gene transcription. The most prominent actions of 1,25-diOH-D₃ are to regulate the plasma levels of calcium and phosphorus (9). Vitamin D is a steroid prohormone yielding the active hormone calcitriol, which regulates calcium and phosphate metabolism; deficiency leads to rickets and osteomalacia. It has a role in controlling cell differentiation and insulin secretion (10).

Materials and methods

Materials

Materials were used in this study included: 1.Ketoconazole tablets 200mg (Kenazole[®], pharma international, Jordan). 2.Combination of vitamins which are vitamin A 80,000 IU (retinol palmitate), vitamin D₃40,000 IU (cholecalciferol) and vitamin E 20 mg (alpha-tocopherol acetate) per 1ml (Vitol-140[®] oily solution (Interchemie, Holland)). 3.Olive oil 4.Mortar and pestle 5.Sensitive balance 6.Beaker 7.Gastric gavage tube 8.Syringes 9.Stirrer.

Experimental animals

Eighteen adults male laboratory albino mice (*Mus musculus*) weighing about 25 gm and aged 60 days were utilized in this study. Animals were kept in animal house of Pharmacy College, University of Kufa, under the same environmental conditions; same day and night intervals, same foods supplementation and water were given ad libitum.

Preparation of doses

Ketoconazole

Ketoconazole tablet weighing 300mg (containing a 200 of ketoconazole as active ingredient) were grinded manually by using ceramic mortar and pestle to convert the tablet to fine powder state. The calculated doses from the ketoconazole powder were suspended in 20 ml of olive oil, and 0.2 ml of the suspension (containing 2.5mg of ketoconazole) were administered for each animal orally once daily by gastric gavage tube.

Vitamins AD₃E

Vitol-140[®] (Interchemie, Holland), which contain vitamins A, D₃, and E in oily solution for parenteral injection were purchased from veterinary clinic. One ml of Vitol-140 contains 20mg of Vit. E, 80000 IU of Vit. A, and 40000 IU of Vit. D. Each animal were given 0.125 ml of Vitol-140 IP daily (once a day) for 10 days.

Experimental design

Animals were divided randomly into three groups (Two treated groups T1&T2, and control group): Each group consists of 6 animals.

Control group

Has been given olive oil (0.2 ml) orally by gastric gavage tube, and at the same time given normal saline (0.125 ml) injected

intraperitoneally once daily for 10 successive days and consider as placebo.

Group (T₁)

Treated with Ketoconazole 100mg/kg BW administered orally by gastric gavage tube plus intra-peritoneal injection of (Vitol-140[®]) a combination of vitamins which are vitamin A (retinol palmitate) in a dose of 400,000 IU/kg BW, vitamin D₃ (cholecalciferol) in a dose of 200,000 IU/kg BW, and vitamin E (alpha-tocopherol acetate) in a dose of 100mg/kg BW once daily for 10 successive days.

Group (T₂)

Treated with Ketoconazole alone in a dose of 100mg/kg body weight. The drug was administered orally by gastric gavage tube once daily for 10 successive days at the same time.

Histopathological examinations

After completion of 10 days of treatment which are the course of treatment. The

animals were sacrificed after anesthesia with chloroform, orchiectomy was performed, and the testis was processed for histopathological examinations. The tissues were processed and paraffin blocks were prepared as per standard protocols. Five-micron-thick sections were obtained and stained with Haematoxyline and Eosin (H&E) stain for light microscope examination.

Calculation of spermatogonia, primary and secondary cells

Microscopical cross sections of the testis were examined using light microscope and the number of spermatogonia, primary and secondary cells were counted for 20 seminiferous tubules in treated and control groups.

Statistical analysis

Results data were analyzed using analysis of variance ANOVA by using SPSS program.

Results

Histopathological Study

In testis cross section fields of ketoconazole treated group (T₂) there was a massive destruction of the testicular tissue confirmed by abnormal splintered architecture of the tissue, separation between the seminiferous tubules and presence of spaces between cells. The cellular mass and density of the tubules were suppressed accompanied by a suppression of spermatogenesis process within the seminiferous tubules also was seen, with vacuolation of spermatogonia and presence of multinucleated spermatid giant cells. Also there was few number of Leydig cells between the seminiferous tubules. Congestion of the blood vessels in the testicular tissues were seen also (Fig. 1), in compared with control group (Fig. 2). While in ketoconazole and multivitamin treated group (T₁) there was complete spermatogenesis within the seminiferous tubules. There were normal spermatogonia, primary and secondary spermatocytes and spermatid. Also there were a high numbers of Leydig cells between the seminiferous tubules, and the fields resemble that of control group (Fig. 3 and 4).

Numerical Study

After counting the number of spermatogonia, the number of primary and secondary cells in 20 seminiferous tubules, found a significant differences ($p < 0.05$) between the control group and the treatment groups in all studied parameter (spermatogonia, the primary and the secondary cells) (Fig. 5, 6, and 7). Result in fig. (5) showed significant ($p < 0.05$) difference in the mean number of spermatogonia in control compared with ketoconazole treated group while the result also showed no significant differences between control and the vitamin treated group (T₁) compared with ketoconazole treated group (T₂). The result in fig. (6) showed significant differences ($p < 0.05$) in the mean number of primary spermatocyte between the control group and treated groups. The result also showed significant differences ($p < 0.05$) between (T₁) and (T₂) group. Result in fig. (7) showed significant differences ($p < 0.05$) in the mean number of secondary spermatocyte between the control group and (T₂) group. The result showed ($p < 0.05$) significant differences between (T₁) and (T₂) groups.

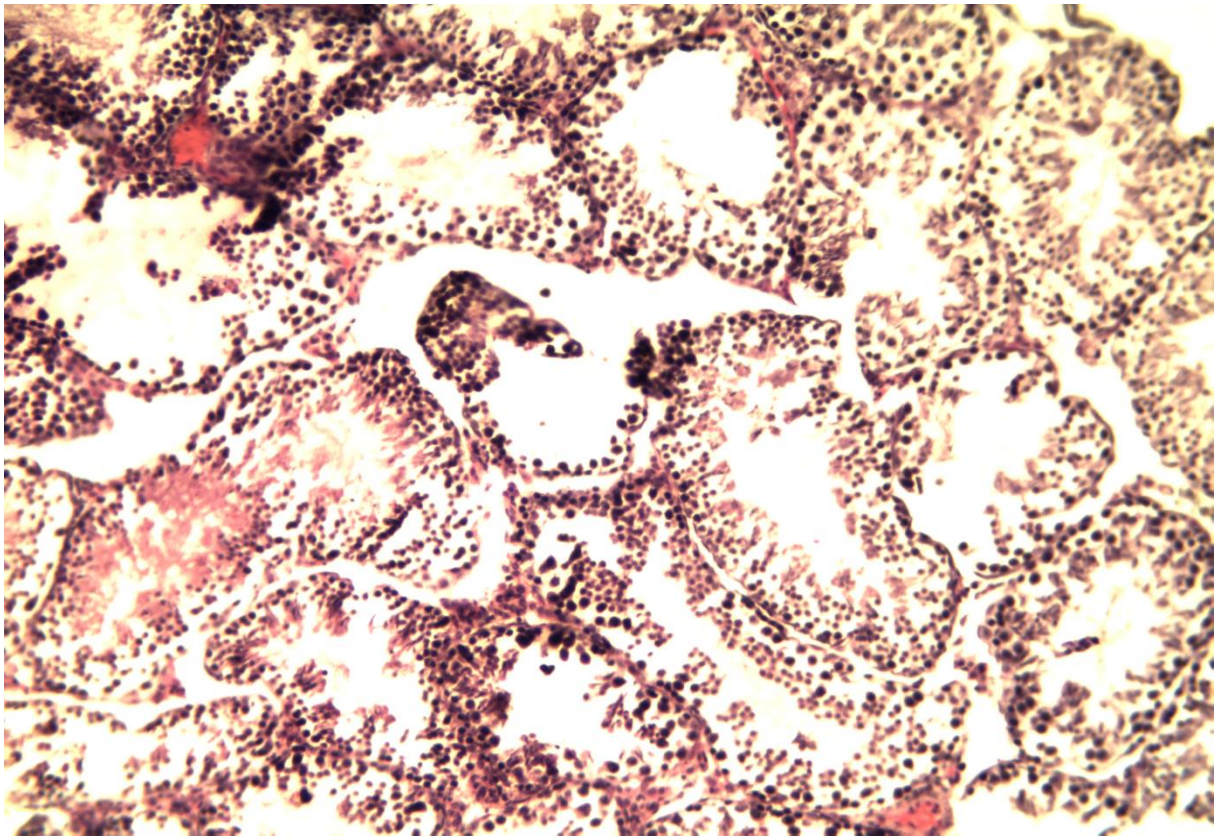


Fig. (1): Cross section of male mouse testis treated with ketoconazole drug show destruction of the architecture of testicular tissue, suppression of the spermatogenesis within the seminiferous tubules (H&E stain X10).

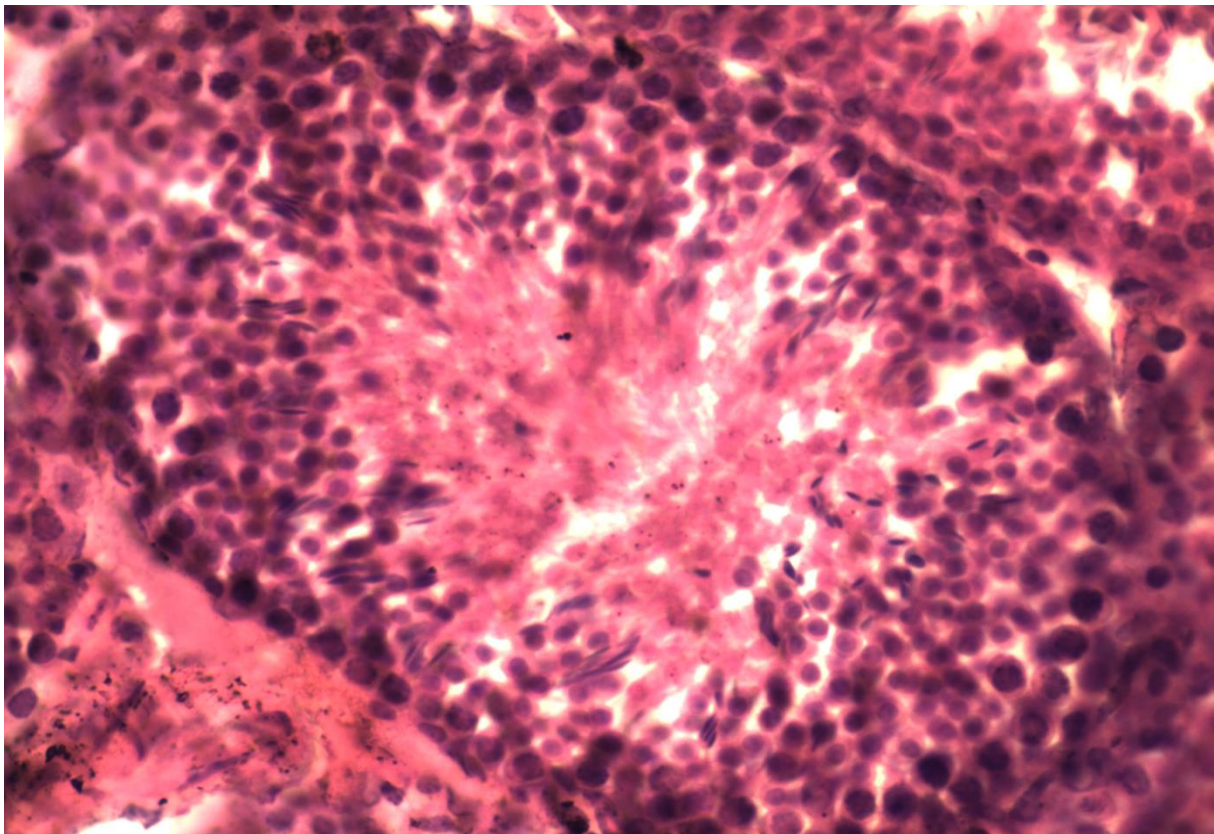


Fig.(2): Cross section of male mouse testis of control group (treated with olive oil only) sees the normal spermatogenesis process and spermatogonia (H&E stain X40).

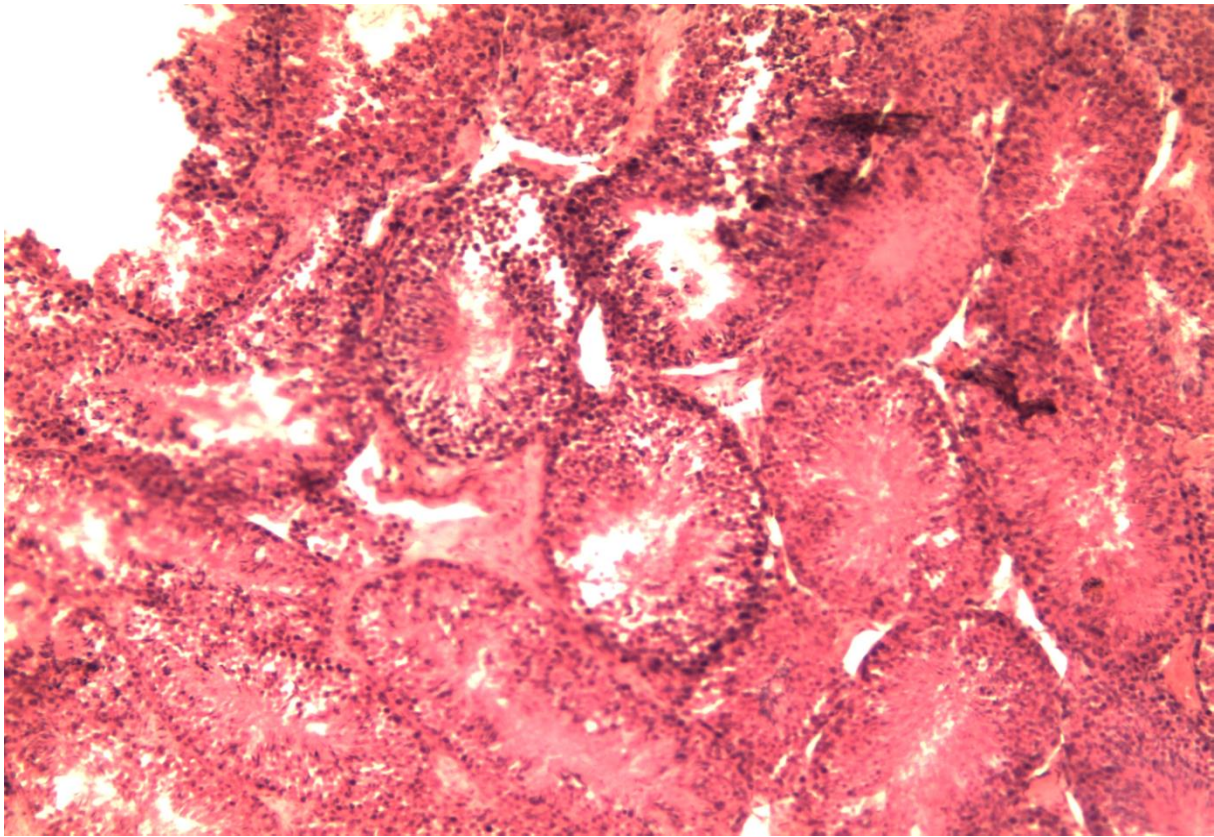


Fig. (3): Cross section of male mouse testis treated with ketoconazole and multivitamins show the normal architecture of testicular tissue, (H&E stain X10).

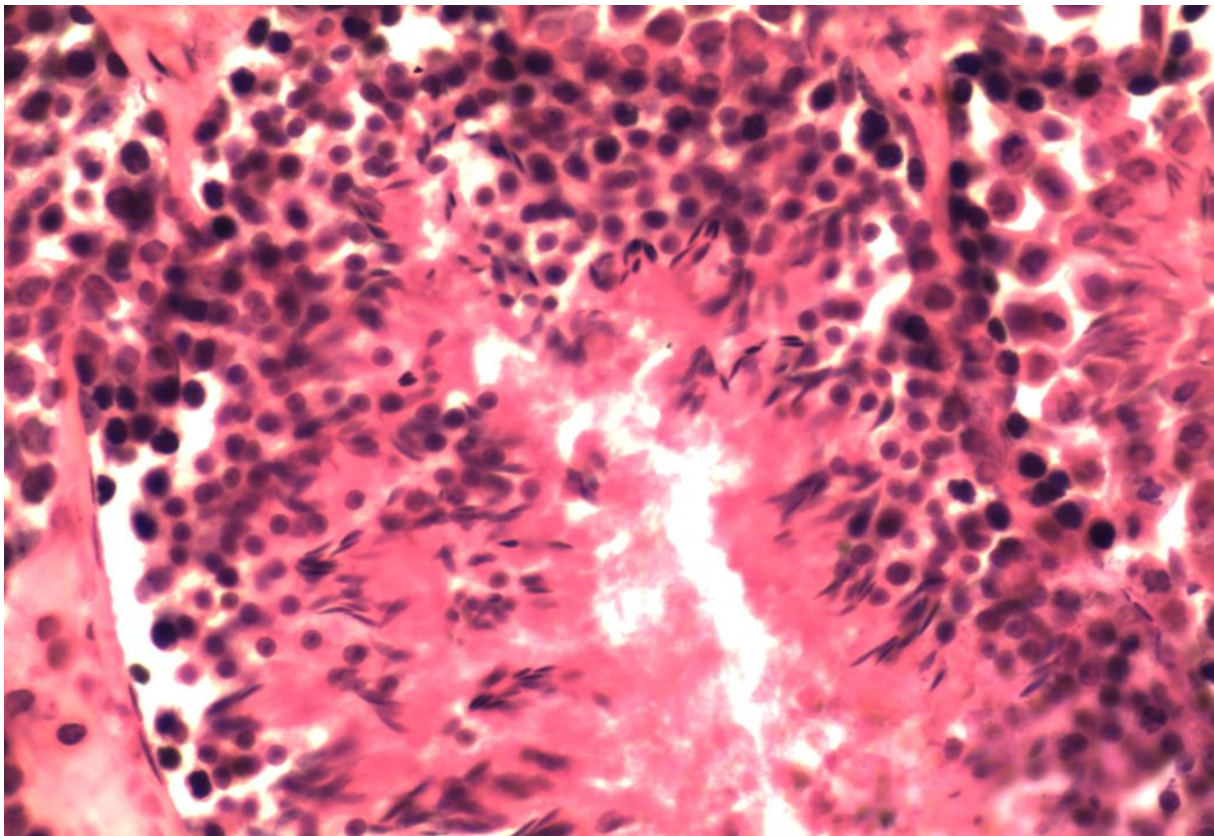


Fig. (4): Cross section of male mouse testis treated with ketoconazole and multivitamins show the seminiferous tubule with normal spermatogonea, primary and secondary spermatocytes and normal spermatids (H&E stain X40).

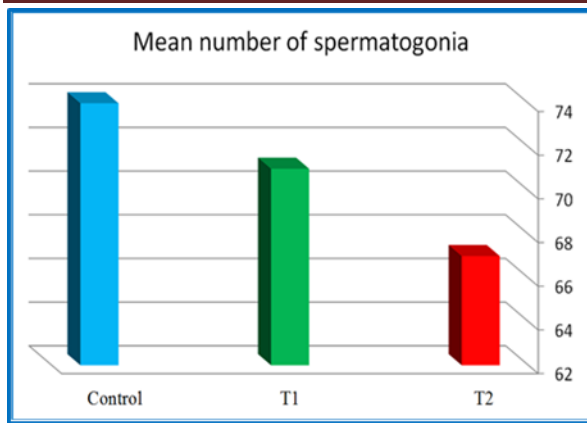


Fig. (5): The mean number of spermatogonia of male mouse, in three groups: Control (given olive oil), T1 (given Ketoconazole + Multivitamins), T2 (given Ketoconazole) (n=6).

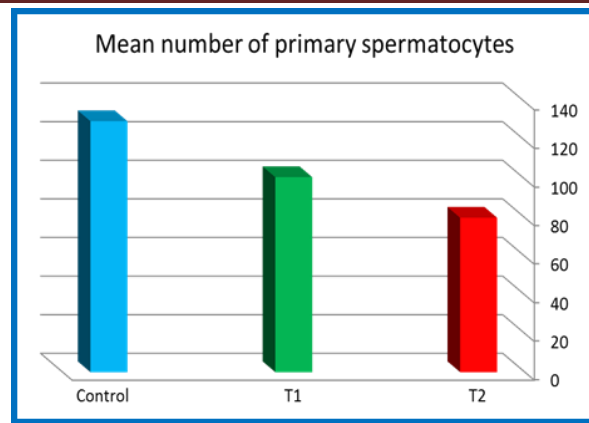


Fig. (6): The mean number of primary spermatocyte of male mouse, in three groups: Control (given olive oil), T1 (given Ketoconazole + Multivitamins), T2 (given Ketoconazole) (n=6).

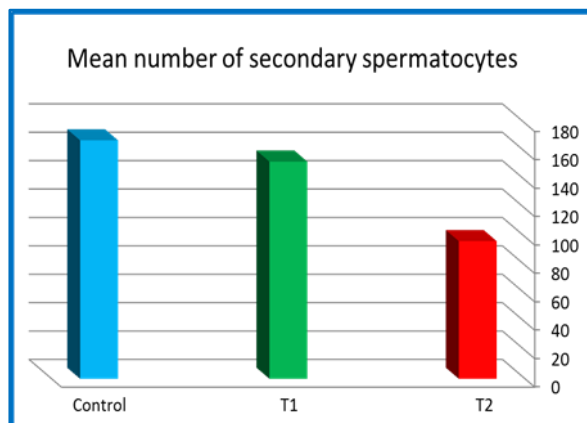


Fig. (7): The mean number of secondary spermatocyte of male mouse, in three groups: Control (given olive oil), T1(given Ketoconazole + Multivitamins), T2 (given Ketoconazole) (n=6).

Discussion

The main functions of the testis are synthesis of sex hormones and production of spermatozoa. Steroidogenesis is performed by Leydig cells of the interstitium, whereas spermatogenesis occurs inside the seminiferous tubules. Ketoconazole, a broad-spectrum antifungal imidazole agent, interferes with cytochrome P-450 enzyme systems in several organs (testis, ovary, adrenal gland, kidney, liver). It inhibits cholesterol synthesis by a dose-dependent. The steroidogenesis is inhibited by its action on the C17-20 lyase, the cholesterol side-chain cleavage enzyme and the 17 alpha-

hydroxylase. In gonads it inhibits aromatase and inhibits adrenocortical steroid biosynthesis. This anti-androgenic effect may be useful in the management of metastatic prostate carcinoma and in testotoxicosis. Its anticortisol effect may be useful in most Cushing's syndromes, where drug control of hypercortisolism is suitable for patients undergoing surgery, as well as those in whom more definitive treatment is delayed. Its usefulness as inhibitor of vitamin D or mineralocorticoids is need more investigations (11), since it found an synergistic activity between ketoconazole and vitamin D for treatment of prostate cancer (12). Ketoconazole shows very good efficacy in tinea versicolor. With respect to systemic treatment of severe and widespread tinea versicolor. Previously the drug of first choice, ketoconazole should no longer be used systemically. In 2013, the FDA issued a warning with respect to the administration of oral ketoconazole (marketed as Nizoral®). Oral ketoconazole is therefore not to be used as first-line therapy in any fungal infection. The rationale behind this is potential adverse effects affecting the adrenal glands and potentially fatal liver damage. There is also a risk of cardiac arrhythmias due to interactions with drugs such as dofetilide, quinidine, pimozide, and cisapride (13). Our study showed that the treatment of male mouse with ketoconazole (KET) alone in a

dose of 100mg/kg body weight orally (once a day) for 10 successive days (T1), had a toxic effect on the testes. This result is in agreement with many documented studies established the presence of adverse effects of KET on the male reproductive system in both humans and animals. Significantly, KET is reported to decrease the weight of male reproductive organs, especially the testes, reduction of epididymis and accessory sex organ weights, and to reduce epididymal sperm concentration and serum testosterone levels, spermatid retention in the seminiferous tubules, decrease of testosterone and increases of estradiol, luteinizing hormone (LH) and follicular stimulating hormone (FSH) (14, 15). As it appear from the present results, there is a significant decrease in spermatogonia and primary and secondary spermatocyte ;many studies are indicated the effect of ketoconazole in the testes (16). Showed that administrating of ketoconazole caused testicular damage and decrease in testosterone level. A single oral dose of 400 mg ketoconazole, administered orally to 5 young men induced a drop in serum and saliva testosterone into the range of hypogonadism (17), meanwhile this may related to the ability of ketoconazole to reduce steroidogenesis. (18) showed that ketoconazole is rather more effective as an inhibitor of steroidogenesis in vitro in testicular cells. While, (3) has also reported damage to rat testis induced by KET intraperitoneal (i.p.) injection (i.e., atrophy of seminiferous tubules, degeneration of Sertoli and germ cells, and sloughing of germ cells). Results of (T2) group when multivitamin are given further to the KET indicate the beneficial effect of the vitamins (E, D₃ and A) in reducing the harmful effect of KET on the testis of male mouse. The anti-oxidant vitamin E plays an important role in the endogenous defense mechanism, since its deficiency is responsible for increased tissue injury caused by oxidative stress (19). Vitamin E is protect the rat testis from testicular damage caused by intraperitoneal aluminum sulfate administration (20), cadmium given orally or intra-peritoneally (21, 22), cypermethrin intoxication in mice

after 14 days (23), also it has protective effect against oxidative damage caused by formaldehyde (6), stabilizing the free radicals produced during cryptorchidism, and reducing morphological testicular alterations (24). Vitamin E is a potential antioxidative agent, and as it is fat-soluble, it is found in biological membranes (16, 22). α -Tocopherol is a powerful antioxidant that prevents oxidation of polyunsaturated fats found in membranes and stabilizes peroxy radicals (24). It inhibits the production of reactive oxygen species so that it effectively prevents germ-cell damage and destruction resulting from this oxidation process. This protective effect of vitamin E could be the result of direct free radical scavenger properties. It could also react with membrane phospholipid bilayers to break the chain reaction initiated by ROS. The improvement of the activities of antioxidant systems might be one of the results of the free radical scavenging effect of vitamin E (6). Vitamin A playing a fundamental role in different processes in the body such as vision and the growth and differentiation of numerous types of cell. It has long been recognized to be essential for spermatogenesis and for maturation of spermatozoa in the epididymis. Vitamin A (retinol) and its derivative (retinoic acid) (the active form of vitamin A), are clearly involved in the regulation of testicular functions in rodents. An excess of vitamin A leads to testicular lesions and spermatogenic disorders, and a deficiency induces early cessation of spermatogenesis and adversely affects testosterone secretion. Retinoid also appear to be necessary for the proliferation and differentiation of a spermatogonia, and for spermiogenesis. In addition, vitamin A deficiency leads to atrophy of the accessory sex organs after decreased testosterone production. Retinoid appear to exert an action on the three main testicular types of cell (Sertoli, germinal and Leydig cells), as they act on the signaling pathways and Sertoli cell metabolism, and modify numerous factors secreted in Sertoli cells. Deficiency of it has resulted into two actions; the direct degeneration and abnormalities of germ cells; and the breakdown and disruption of inter-Sertoli cell tight junctions which also

lead to the degeneration of these spermatogenic cells (5, 25, 26). Although the many adverse symptoms of vitamin A deficiency (VAD) in animals can be reversed by supplementing the diet with all-trans-retinoic acid (ATRA), the animals are still blind and the males remain sterile. The gene ablation studies indicate that ATRA, not retinol, is the active retinoid functioning in normal spermatogenesis. However, dietary retinol is clearly required, probably because the supplemented ATRA cannot efficiently cross the Sertoli cell barrier, which is formed from specialized junctions in the Sertoli cells and results in sequestering the meiotic and post-meiotic cells from the circulation (27). Earlier it was thought that vitamin A in a form of (retinol) exerts action in the testis but the (retinoic acid) not did, that mean injection of physiological doses of retinol, and not of retinoic acid, does restore the normal spermatogenesis in vitamin A-deficient rats. Recently showed that spermatogenesis can be re-initiated by supplementation of retinoic acid, injected repeatedly at very high doses, indicating that the blood–testis barrier inhibits the passage of retinoic acid circulating towards the germ cells, and that the Sertoli cells synthesize retinoic acid from circulating retinol. This contention is supported by the fact that the passage of radioactive retinoic acid into the testis is inhibited compared with the passage of retinoic acid into other tissues (25). Retinoic acid found initiating meiosis (28). Sertoli cells are the main site of retinoic acid synthesis. Thus, the enzymes allowing retinol oxidation into retinoic acid (alcoholdehydrogenase and retinal dehydrogenase) are essentially located in the Sertoli cells. These cells may then distribute the retinoic acid to their neighbors, notably to germ cells. Furthermore, production of retinol acid by Sertoli cells increases during testicular development. Sertoli cells are also the main site of retinol storage (25). Vitamin D has been well-known for its function in maintaining calcium and phosphorus homeostasis and promoting bone mineralization. There is some evidence that in addition to sex steroid hormones, the classic regulators of human reproduction,

vitamin D also modulates reproductive processes in women and men. The two main forms of vitamin D are: vitamin D₃ or cholecalciferol, which is formed in the skin after exposure to sunlight or ultraviolet light, and ergocalciferol or vitamin D₂ which is obtained by irradiation of plants or plant materials or foods. The differences are situated in the side chain. Vitamin D₃ is about 4 times as potent as vitamin D₂. Vitamin D₃ is synthesized in the skin during summer months or it is obtained from nutritional sources, especially fatty fish such as herring and mackerel. Limitations are age, a pigmented skin, sunscreen use and clothing. Vitamin D₃ or cholecalciferol is hydroxylated in the liver into 25-hydroxyvitamin D₃ (25(OH)D) and subsequently in the kidney into 1,25-dihydroxyvitamin D₃ (1,25(OH)₂D). This is the active metabolite, which stimulates the calcium absorption from the gut. When 1, 25 (OH)₂D is sufficiently available 24, 25, dihydroxyvitamin D (24,25(OH)₂D) is formed in the kidney, which is further catabolized. The vitamin D metabolites are bound in the circulation to vitamin D binding protein which has a high affinity to 25(OH)D, 24,25, (OH)₂D and 1,25(OH)₂D and has a high homology to albumin. The active metabolite 1, 25 (OH)₂D enters the cell and binds to the vitamin D receptor. This complex forms a heterodimer with the retinoid receptor and binds to a vitamin D responsive element on a responsive gene, such as that of osteocalcin, calcium binding protein or 24-hydroxylase. This is followed by transcription and translation and proteins are formed such as the calcium binding protein or osteocalcin. The classic effect of 1, 25 (OH)₂D on active calcium transport occurs in the intestinal cell. Calcium enters the cell through membrane proteins. In the intestinal cell, 1,25, (OH)₂D binds to the vitamin D receptor and the calcium binding protein is synthesized and this regulates the active transport through the cell. The calcium is transported to the extracellular fluid by an ATP dependent mechanism (29). From animal and human studies, it is evident that vitamin D (VD) is important for optimal male reproductive function. Some of the VD effects are

presumably mediated locally by the presence of vitamin D receptors (VDR) and the VD metabolizing enzymes in adult male germ cells, Leydig cells, and male reproductive tract, while other actions may be influenced by the systemic effects of VD serum levels. The low expression of VDR and VD metabolizing enzymes in spermatozoa from infertile men compared with normal men supports a role for the local VD metabolism and may have functional consequences. Most of the VD effects in the testes appear to be mediated through estrogen biosynthesis, but other candidate genes involved in calcium homeostasis, endocrine function, and cell cycle control may be involved. An association between serum 25-OHD3 and testosterone production remains to be proven. Moreover, both local VD metabolism and serum levels of 25-OHD3 may have a direct effect on sperm motility in both animal and humans even after considering the indirect effect mediated by calcium homeostasis. The effects on sperm motility may be mediated mainly in epididymis rather than the testes (30). Vitamin D signaling has a positive effect on semen quality, increases estrogen responsiveness and differentiates germ cell

tumors. Interestingly, functional animal models show that vitamin D is important for estrogen signaling and sperm motility, while cross-sectional studies support the positive association between serum 25-hydroxy-vitamin D level and sperm motility in both fertile and infertile men (31). The vitamin D receptor (VDR) and vitamin D metabolizing enzymes are found in reproductive tissues of women and men. Vdr knockout mice have significant gonadal insufficiency, decreased sperm count and motility, and histological abnormalities of testis, ovary and uterus. In men, vitamin D is positively associated with semen quality and androgen status. Moreover, vitamin D treatment might increase testosterone levels. In vitamin D-deficient male rats, it has been shown that although capable of reproducing, animals have a 45% reduction in successful matings as well as a decreased overall fertility rate that is reduced by 73% when compared with controls. The testes of vitamin D-deficient rats showed incomplete spermatogenesis and degenerative changes. The replacement of calcium alone in vitamin D-depleted animals was enough to restore fertility in male rats (32).

References

- 1-Shanbhag TV, Shenoy S, Nayak V (2014) Pharmacology for Dentistry 2nd Ed. ELSEVIER comp. pp: 343.
- 2-Kinobe RT, Dercho RA, Vlahakis JZ, Brien JF, Szarek WA, Nakatsu K (2006) Inhibition of the enzymatic activity of hemeoxygenases by azole-based antifungal drugs. *J Pharmacol Exp Ther*; 319(1):277–84.
- 3-Amin A (2008) Ketoconazole-induced testicular damage in rats reduced by Gentiana extract. *Experimental and Toxicologic Pathology* 59: 377–384.
- 4-Li H, Palczewski K, Baehr W, Clagett-Dame M (2011) Vitamin A deficiency results in meiotic failure and accumulation of undifferentiated spermatogonia in prepubertal mouse testis. *Biology of reproduction* 84,336–341.
- 5-Hogarth CA, Griswold MD (2010) The key role of vitamin A in spermatogenesis. *J Clin Invest* 120: 956-962.
- 6-Zhou D, Qiu1 S, Zhang J, Tian H, Wang H (2006) The protective effect of vitamin E against oxidative damage caused by formaldehyde in the testes of adult rats. *Asian J Androl*; 8 (5): 584–588.
- 7-Ranade AV, Tripathi Y, Rajalakshmi R, Vinodini NA, Soubhagya RN, Nayanatara AK, Rekha DK, Kumari M (2011) Effect of vitamin E administration on histopathological changes in rat testes following torsion and detorsion. *Singapore Med J*; 52(10) : 742-746.
- 8-Aitken RJ, Roman SD (2008) Antioxidant systems and oxidative stress in the testes In: Yan Cheng C. (ed.) molecular mechanisms in spermatogenesis. Landes bioscience and springer science business media. pp:156.
- 9-Harvey RA, Ferrier DR (2014) Lippincott's illustrated reviews: biochemistry 6thed. Lippincott Williams & Wilkins, a Wolters Kluwer business. pp:382,386.
- 10-Bender DA (2015) Micronutrients: vitamins & minerals. in: Rodwell V.W. et.al.(ed.) Harper's Illustrated Biochemistry 30thed. The McGraw-Hill Education.pp:547,562.
- 11-Miossec P, Archambeaud-Mouveroux F, Teissier MP (1997) Inhibition of steroidogenesis by ketoconazole. Therapeutic uses. *Ann Endocrinol (Paris)*; 58 (6): 494-502. (Abstract) (Article in French).
- 12-Peehl DM, Seto E, Feldman D (2001) Rationale for combination ketoconazole/ vitamin D treatment of prostate cancer. *Urology*; 58(2 Suppl 1):123-6.

- 13-Nenoff P, Kruger C, Paasch U, Ginter-Hanselmayer G (2015) Mycology-an update Part 3: Dermatomycoses: topical and systemic therapy. *J DtschDermatol Ges.*;13(5):387-411.
- 14-Shin JH, Moon HJ, Kang IH, Kim TS, Kim IY, Park IS, Kim HS, Jeung EB, Han SY (2006) Repeated 28-day oral toxicity study of ketoconazole in rats based on the draft protocol for the "Enhanced OECD Test Guideline No. 407" to detect endocrine effects. *Arch Toxicol.*; 80 (12): 797-803.
- 15-Iamsaard S, Burawat J, Kanla P, Arun S, Sukhorum W, Sripanidkulchai B, Uabundit N, Wattathorn J, Hipkaeo W, Fongmoon D, Kondo H (2014) Antioxidant activity and protective effect of Clitoriaternatea flower extract on testicular damage induced by ketoconazole in rats. *J Zhejiang UnivSci B.*;15(6):548-555.
- 16-Guerdi k, Hacene F, Chettoum A, Latreche A, Sahraoui L, Boukhris N, Tahraoui A (2013) Administering Ketoconazole (25mg/kg) for 14 days in male wistar rat provokes testicular damage accompanied by changes in testosterone levels and immune function. *Rev. Sci. Technol. Synthèse.* (27):82-88.
- 17-Schurmeyer T, Nieschlag E (1984) Effect of ketoconazole and other imidazole fungicides on testosterone biosynthesis. *Actaendocrinologica*; 105: 275-280.
- 18-Lambert A, Mitchell R, Robertson WR (1986) The effect of ketoconazole on adrenal and testicular steroidogenesis in vitro. *Biochem. Pharmacology*; 355 (22): 3999-4004.
- 19-Schneider C (2005) Chemistry and biology of vitamin E. *Mol. Nutr. Food Res.*; 49,7-30.
- 20-Kutlubay R, Oguz EO, Can B, Guven MC, Sınık Z, Tuncay OL (2007) Vitamin E Protection from Testicular Damage Caused by Intraperitoneal Aluminium. *International Journal of Toxicology*, 26:297-306.
- 21-Yang HS, Han DK, Kim JR, Sim JC (2006) Effects of a-tocopherol on cadmium-induced toxicity in rat testis and spermatogenesis. *J Korean Med Sci*; 21: 445-51.
- 22-Rajendar B, Bharavi K, Rao1 GS, Kishore PVS, Kumar PR, Satish Kumar CSV, Kumar DS (2011) Protective effect of α -tocopherol on biochemical and histological alterations induced by cadmium in rat testes. *Indian J Physiol Pharmacol*; 55 (3): 213-220.
- 23-Al-Shaikh TM, Elfayoumi RI (2013) Protective effects of vitamin E against testicular enzymes toxicity induced by cypermethrin in mice. *Int J Pharm Bio Sci*; 4(2): (B) 942 - 953.
- 24-Villasenor RMV, Ojeda I, Gutierrez-Perez O, Saldana MC, Osvaldo Cuevas O, Maria DS Castaneda JCR (2011) Protective effect of a-tocopherol on damage to rat testes by experimental cryptorchidism. *Int. J. Exp. Path.*, 92, 131-139.
- 25-Livera G, Rouiller-Fabre V, Pairault C, Levacher C, Habert R (2002) Regulation and perturbation of testicular functions by vitamin A. *Reproduction.*; 124(2):173-180.
- 26-Chung SSW, Wolgemuth DJ (2004) Role of retinoid signaling in the regulation of spermatogenesis. *Cytogenet Genome Res.*; 105(0): 189-202.
- 27-Wolgemuth DJ, Chung SSW (2007) Retinoid signaling during spermatogenesis as revealed by genetic and metabolic manipulations of retinoic acid receptor alpha. *SocReprodFertil Suppl.*; 63: 11-23.
- 28-Griswold MD, Hogarth CA, Bowles J, Koopman P (2012) Initiating meiosis: The case for retinoic acid. *Biology of Reproduction*; 86(2):35, 1-7.
- 29-Lips P (2006) Vitamin D physiology. *Progress in Biophysics and Molecular Biology* 92 (2006) 4-8.
- 30-Jensen MB (2012) Vitamin D metabolism, sex hormones, and male reproductive function. *Reproduction.* 2012;144(2):135-52.
- 31-Jensen MB (2014) Vitamin D and male reproduction. *Nat Rev Endocrinol.*;10(3):175-86.
- 32-Lerchbaum E, Obermayer-Pietsch B (2012) Vitamin D and fertility: a systematic review. *Eur J Endocrinol.*;166 (5):765-78.