

The effect of low level laser therapy on tendon healing in male rats

Hayder Hussain Abid

Thaier Alwan Abid

College of Vet. Med. / Univ. of Al-Qadisiya

email: thalwan@yahoo.com

(Received 8 January 2015, Accepted 25 February 2015)

Abstract

The study was focused to evaluate the efficacy of low level laser therapy on healing of injured Achilles tendon in rats. Ninety adult male Wistar rats weighing 240 ± 20 gm, 10-12 wks. old were used. Animals were divided into three main equal groups; control and two laser treatment groups. Each main group was divided into two equal subgroups; 1-Crushing tendon group, 2-Tendon cutting and anastomosis. Percutaneous crushing of Achilles tendon 1 cm above the hock joint was performed by using artery forceps in 45 rats (15 control, 15 for 4 J/cm^2 , and 15 for 8 J/cm^2). Completely transverse sever (by scalpel) of Achilles tendon 1 cm above the hock joint was performed in another 45 rats. The cutting tendon was suturing by (modified Kessler technique) using 0/5 silk suture material, and the skin was closed by 0/4 silk simple interrupted suture. GaAlAs diode laser with a wave length of (660 nm) were used for the laser treatment which started immediately after suturing or crushing of tendon, and daily repeated (once a day) for 14 consecutive days. Two doses 4 J/cm^2 and 8 J/cm^2 were used (30 rats for each dose). Control group 30 rats were left without treatment. Specimens of healed tendons (1 cm in length) were taken after (14, 21, and 28) days post injury for histopathological examination by light microscopy after processing and staining with H&E stain to evaluate the healing process. The histopathological findings suggest the favorable qualitative pattern of the newly synthesized collagen, significant number of tenocyte, absence of inflammatory cells and stimulate synthesis of angiogenesis of the regenerating tendons. However, energy density of 8 J/cm^2 was more effective to healing process than 4 J/cm^2 , by presence of more collagen deposition, significant number of tenocyte, less inflammatory cells and more capillaries were seen. In conclusion, the laser wave length 660 nm in the two doses used in this study was promote healing process in injured Achilles tendon, further the energy density of 8 J/cm^2 was seen the better in stimulation and maturation of injured Achilles tendon compare with 4 J/cm^2 dose.

Key words: LLLT, Achilles tendon, tendon healing, rats.

تأثير العلاج بالليزر واطئ الطاقة على التئام الوتر في ذكور الجرذان

حيدر حسين عبد ثاير علوان عبد
كلية الطب البيطري / جامعة القادسية

الخلاصة

تركزت الدراسة حول تقييم فاعلية العلاج بالليزر واطئ الطاقة على التئام وتر اكليس في الجرذان. استخدم تسعون جرذ ذكر بالغ (ويستر) اوزانها 240 ± 20 غم واعمارها 10-12 اسبوع. قسمت الحيوانات الى ثلاث مجاميع رئيسية (مجموعة سيطرة ومجموعتين معاملة بالليزر)، كل مجموعة رئيسية قسمت الى مجموعتين تحتية متساوية (1- مجموعة سحق الوتر 2- مجموعة قطع الوتر والتحامه). جرى سحق وتر اكليس في 45 جرذ (15 لمجموعة السيطرة، 15 لمجموعة الليزر 4 جول/سم²، 15 لمجموعة الليزر 8 جول/سم²) على مسافة 1 سم اعلى مفصل العرقوب وذلك باستخدام الملقط الشرياني. و جرى قطع الوتر بالمشروط عند نفس المكان في 45 جرذ اخر، ثم اجريت خياطة الوتر المقطوع باستخدام تقنية كسلر المطورة وباستخدام خيط الحرير 0/5 واغلق جرح الجلد بخيط الحرير 0/4 وبالتقنية البسيطة المتقطعة. للمعالجة بالليزر استخدم الليزر الثنائي نوع GaAlAs بطول موجي 660 نانو متر وبدئت المعالجة مباشرة بعد عملية سحق الوتر او خياطته لمرة واحدة في اليوم واستمرت يوميا لمدة 14 يوم متتالية واستخدمت جرعتان 4 جول/سم² و 8 جول/سم² (30 جرذ لكل جرعة). ومجموعة السيطرة (30 جرذ) تركت بدون معالجة بالليزر. اخذت نماذج من الوتر الملتئم بطول 1 سم

للفتترات 14 ، و 21 ، و 28 يوم بعد اذى الوتر لغرض الفحص النسيجي المرضي بالمجهر الضوئي لتقييم عملية الالتئام بعد معاملتها وصبغها بصبغة الهيماتوكسلين ايوسين. اظهرت نتائج الفحص النسيجي المرضي تكوين نمط نوعي مفرح من الغراوين الجديد مع اعداد معنوية من خلايا الوتر وغياب للخلايا الالتهابية وتحفيز تصنيع التخليق الوعائي للأوتار المجردة. على الرغم من ان الجرعة 8 جول/سم² كانت اكثر تأثيرا لعملية الالتئام من الجرعة 4 جول/سم² وذلك بوجود ترسيب اكثر من الغراوين ووجود اعداد معنوية من خلايا الوتر وخلايا التهابية اقل واوعية شعرية اكثر. نستنتج من الدراسة ان الليزر ذي الطول الموجي 660 نانو متر وفي الجرعتين المستخدمتين في هذه الدراسة قد عزز عملية الالتئام في وتر اكيلس اضافة الى ان الجرعة 8 جول/سم² كانت افضل في تحفيز ونضوج التئام وتر اكيلس مقارنة مع الجرعة 4 جول/سم².
الكلمات المفتاحية: الليزر واطئ الطاقة ، وتر اكيلس ، التئام الوتر ، الجرذان.

Introduction

Tendons are fibrous connective tissues that connect muscles to bone. Each muscle at least has two tendons, one at the distal end, and the second at the proximal end. It act to convey the muscular forces to the bone and move the joints, further to it is supporting the skeleton during movement. Also, they act as shock absorbers to prevent damage to muscles and stabilize joints (1). Tendons are stronger than muscles (units/area), and while the tensile strength of tendons is resemble to that of bone tissue, tendons are slightly flexible and extensible (2). The tendon rupture is a significant injury event in the most physically active of people. More than 75% of ruptures are related to athletic activity (especially in men), and the incidence is increasing in the western world in particular, in association with greater sports participation (3). Further to the athletic injuries, tendon injuries in human being can be acute or chronic, and are caused by intrinsic or extrinsic factors, either alone or in combination. For that this condition associated with multiple disorders, including inflammatory conditions, autoimmune disorders, and collagen abnormalities (4).

In extraordinary equine athletes (with the differences between types of activity like racing on the flat or over hurdles), up to 30% of racehorses are affected with partial and complete forelimb superficial digital flexor tendon injuries, additional to (23–67%) re-rupture rates, besides long recovery periods (up to 18 months) (5). The etiology of Achilles tendon injuries in dogs is usually traumatic. Depending on the trauma, the severity of the lesion may vary considerably, leading to stretching, small or partial lacerations or a complete rupture. The nature of the trauma influences the type of tendon injury and may result in acute rupture of the tendon with partial or complete loss of

integrity of the structure, sometimes with exposure of tendon ends (like hunting accident) (6). In addition, weakening or rupture of the tendon structure can occur secondarily to systemic diseases (like Cushing's disease) or to iatrogenic etiologies (7). Three different types of breakage, based on anatomical location and the severity of the lesion of the Achilles tendon: Type 1 is a complete rupture, Type 2 has three subtypes for partial rupture with a lengthened Achilles tendon system and Type 3 is a tendinosis or peritendinosis (8). The healing of tendon is considering a highly complex process with interaction between blood and tissue-derived cells, inflammatory mediators and matrix molecules. In general the indication of the healing and repair process is to achieve hemostasis, tissue integrity and load-bearing capacity. The healing of tendon occurs by both extrinsic cells from the blood supply and intrinsic cells from the ruptured tendon and paratenon (9). Tendon healing occurs in three overlapping phases. The inflammatory phase is begin immediately following the injury, the erythrocyte and inflammatory cells, especially neutrophils, enter the site of injury in first 24 hours, monocytes and macrophage predominant and phagocytosis of necrotic materials occur, vasoactive and chemotactic substance are released with increased vascular permeability occur, initiation of angiogenesis, stimulation of tenocyte proliferation, and recruitment a lot of inflammatory cells (10). Tenocyte gradually migrate to the site of the wound and type III collagen synthesis is begin. The proliferation phase is beginning few days post injury, the synthesis of type III collagen peak during this phase and last for a few weeks, the content of the water and the concentration of the glycosaminoglycan concentrations remain highly through this

phase (11). Approximately six weeks, the remodeling phase commences, with decrease cellularity, collagen and decrease glycosaminoglycan synthesis. The remodeling phase can be divided into consolidation and maturation stages, the consolidation stage begins after six weeks and continues for ten weeks, in this period, the repair tissue changes from cellular to fibrous, and also, through this period the tenocyte stays with high metabolism, the tenocyte and collagen fibers become aligned in the direction of the stress (12). Higher proportion of type I collagen is synthesized through this phase (13). Post ten week the maturation stage occurs, with gradual change of the fibrous tissue to scar like tendon tissue over the course of one year. Through the latter half of this stage, the metabolism of tenocyte and vascularity of tendon declines (14). The Achilles tendon in human is the largest tendon in the body. It is the general tendon of the gastrocnemius and soleus muscles. These muscles insert into the most posterior aspect of the calcaneus in man (15). It is of central developmental importance to the human being, enabling the movement on feet (16). In dogs the Achilles tendon originates from different muscle-tendon units that conjoin at the heel, the gastrocnemius tendon, the superficial digital flexor tendon, and the general tendon of the biceps femoris, gracilis and semitendinosus muscles (8, 17). Achilles tendon is selected as a model of tendon healing in experimental animals like rats, because it is large, near the skin and easy to access, which makes it easy to undergo surgical techniques (18).

The rupture of the Achilles tendon can take weeks or even months to fully heal (19); one reason for this is due to the low blood supply to this tendon (20). Due to the slow healing process, the rupture of the Achilles tendon is considered a serious injury and has drawn the attention of researchers, who have utilized a variety of methods, including the application of ultrasound, electrical stimulation, and low-level laser (LLL), to accelerate the repair process (21). Low level laser therapy has shown promising results with respect to fibroblast proliferation, collagen synthesis, and tissue repair (22).

However, LLLT also was reported to reduce elongation and increase stiffness in tendons (23). LLLT has attracted considerable attention because of its success in tissue repair and its broad spectrum of applications, but there is controversy about the protocols for the use of LLLT (24). This study aimed to assess if LLLT is effective for the treatment of tendon healing and determine the relevance of irradiation parameters to outcome, and the validity of current dosage recommendations for the treatment of tendon healing.

Materials and methods

Ninety adult male Wistar rats weighing 240 ± 20 gm, and 10-12 wks. old were used. Animals were divided into three main equal groups (control and two laser treatment groups' 4 J/cm^2 and 8 J/cm^2). Each main group was divided into two subgroups; 1-Crushing tendon group (blunt trauma). 2-Tendon cutting and anastomosis (sever trauma). The animals were kept in plastic cages with a metal top, in same normal laboratory conditions (room temperature $20-24^\circ\text{C}$ and humidity 60%) and were fed a solid diet, and water were given ad libitum. The rats were anesthetized with a mixture of ketamine (50 mg/kg. BW) and xylazine (10 mg/kg. BW), given by intramuscular injection (25). Tendon injury (crushing tendon or tendon cutting and suturing) was induced in the left Achilles tendon of each animal. The skin over left Achilles tendon was prepared for aseptic surgery (shaved, and disinfected, with 70% alcohols, followed by 2.5 Tr. of Iodine). Percutaneous crushing of Achilles tendon, 1 cm above the hock joint was performed by using artery forceps in 45 rats (15 control, 15 of 4 J/cm^2 , and 15 for 8 J/cm^2) (Fig. 1). Completely transverse severed of Achilles tendon 1 cm above the hock joint was performed by scalpel in another 45 rats after making 2 cm length longitudinal skin incision on the lateroposterior side of the leg (Fig. 2). The cutting tendon was sutured by modified Kessler technique (26) using 0/5 silk suture material (Fig. 3). After that the skin incision was closed with simple interrupted suturing using 0/4 silk suture material.

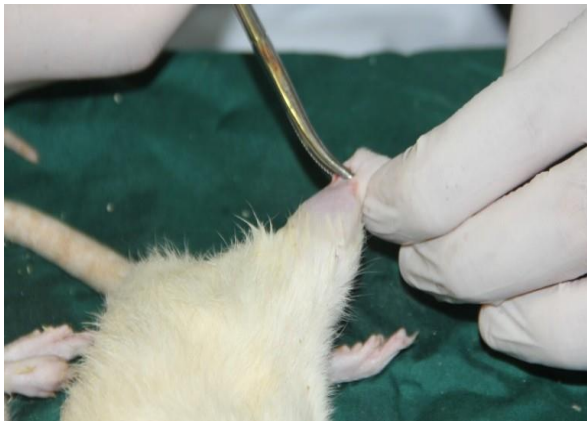


Fig. (1) Crushing of Achilles tendon.

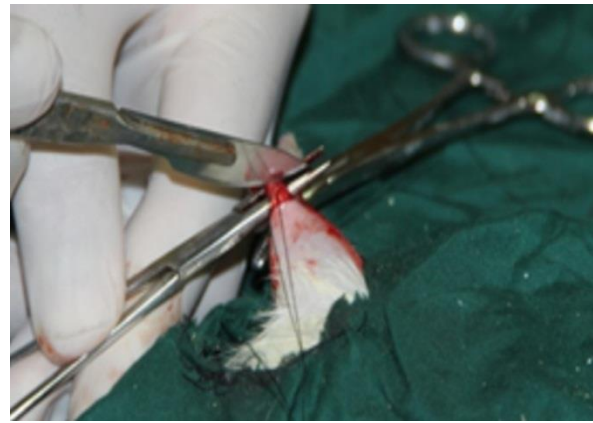


Fig. (2) Severed of Achilles tendon by scalpel.

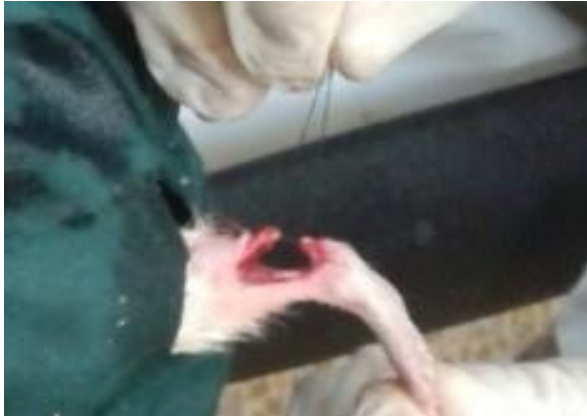

Fig. (3) Suturing of the cutting tendon.

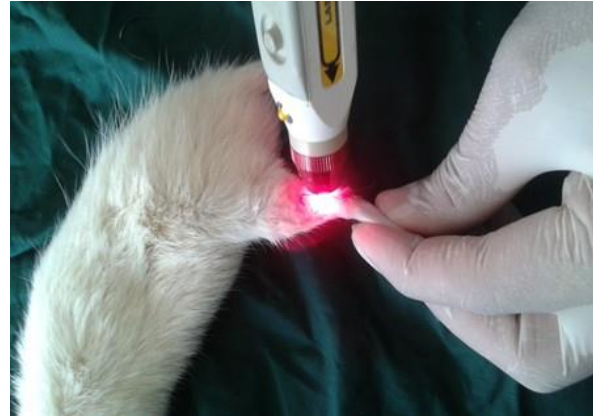

Fig. (4) Laser irradiation.

Laser treatment

The laser treatment was started immediately after suturing the tendon injury in all treated animals (60 rats), and daily repeated (once a day) for fourteen consecutive days. Treatment sessions were conducted on each animal at the same time of day as the first laser application. The laser probe was placed in direct contact with the animal on only one treatment point at the injury site and positioned perpendicularly to the Achilles tendon (Fig. 4). The diode laser used was Gallium Aluminum Arsenide Laser (GaAlAs) (Omega laser system limited UK) with a wave length of (660 nm) power (50 mw) pulsing rate (146 HZ) and spot size (0.5

cm). Two doses (energy density) 4 J / cm^2 and 8 J / cm^2 were used (30 rats) for each dose (15 rats for crushing and 15 rats for cutting tendon). Control group (30 rats were left without treatment, 15 rats for crushing tendon and 15 rats for cutting tendon). After making general anaesthesia to the animals, specimens of healed tendons (1 cm in length) were taken after (14, 21, 28) days post injury from all groups. The specimens were preserved in 10% buffer formalin solution and send for histopathological examination after staining with Hematoxylin and Eosin stain to evaluate the progress of healing process.

Results

In crushing tendon control group, 14 days post crushing (PC): There was modest and slow healing process. The inflammatory process still active typified by presence of numerous inflammatory cells seen infiltrated between the bundles of the collagen fibers around several buds of newly formed blood vessels. The bundles of collagen fibers were

longitudinally oriented, and also there were crimped collagen fibers with limited tenocytes which have elongated spindle shape nucleus (Fig. 5). After 21 days (PC): The healing process remains modest. The inflammation was subsiding; the inflammatory cells were seen in the epitendon area. The collagen fiber

longitudinally oriented and the crimped collagen fibers were also seen in the crushed area compared with the normal tendon above and below the site of crushing (Fig. 6). The tenocytes were insignificant in number which have elongated and spindle nucleus shape. Mild healing process still was seen. After 28 days (PC); No inflammatory signs were seen between the tendon fibers except in epitendon area. The collagen fibers resemble the normal in shape and orientation with an undulation. The tenocytes numbers more than normal were seen with hyper chromic elongated nucleus (Fig. 7).

In control group of tendon cutting and anastomosis, 14 days post operation (PO): A powerful inflammatory process were seen characterized by presence of plentiful inflammatory cells, many newly formed blood vessels, and weak splintered mesh of collagen fibers oriented in multi directions were seen at the site of anastomosis (Fig. 8). At 21 days (PO): A dominant healing process were observed categorized with a thick and dense net of collagen fibers oriented in multi directions where observed at the site of anastomosis, with voluminous newly rete of blood vessels and scanty inflammatory cells which has been seen. Necrosis around the suture material was seen also (Fig. 9). At 28 days (PO): The healing process has little progress. Dense collagen fibers networks oriented in one direction were seen at the site of anastomosis, with newly rete of blood vessels and the inflammatory cells were also seen (Fig. 10).

In 4J/cm² laser treatment crushing tendon group at 14 days post crushing (PC), a vigorous healing proses was observed. There was irregular arrangement of collagens fibers, numerous existences of tenocytes between the collagen fibers marketed with hyper chromic round enlarged nucleus (Fig. 11). Also a lot of network of inflammatory cells, with presence of hemorrhage were seen, in compare with control in the same period of observation (14 days). At 21 days (PO), regular arrangement of collagen was seen with profound presence of tenocytes between the collagen fibers. No signs of inflammation (Fig. 12) in compare with control of the same time of reading, and the

reading of 14 days of the same technique. In 8J/cm², 14 days (PO), there was more dense irregularly arranged collagen fiber with a marked increase of tenocytes (hyper cellularity of tenocytes) between the collagen fibers, newly developed capillary vessels, less inflammatory cells, no hemorrhage was seen, in compare with the control and the crushing 4J/cm² groups in the same period (14 days) (Fig. 13). At the 21th day (PO), there were denser collagen fibers, increased cellularity of tenocytes which have large nucleus in compare with the control and the crushing 4J/cm² groups in the same period (21 days) of observation and the previous reading in the same technique, with no signs of inflammation in the tendon, more inflammatory signs at epitendon with the presence of fibrous tissue and adhesion present (Fig. 14). In both doses of 4J/cm², and 8J/cm², at 28 days (PO) were seem like each other and show resemble changes which including complete healing process, characterized by regular parallel arrangement of collagen fibers, presence of numerous of tenocytes, which have normal nucleus size, no inflammatory signs, and the epitendon show more fibrous tissue with scanty solitary inflammatory cells (Fig. 15 and 16).

In 4J/cm² cutting tendon and anastomosis, at 14 days (PO), there was extremely marked increased cellularity of tenocytes which have large nucleus, massive collagens fiber with random arrangement of direction (Fig. 17), with plentiful members of newly capillaries have one direction (Fig. 18) and no signs of inflammation were seen in compare with control tendon cutting and anastomosis group at same time (14 days). At the 21th day (PO), although there was a large number of tenocytes but it was less than what found in previous reading of the same technique at 14 days, and the collagen fiber were seen more arranged, the reorientation with the long axis become clearer (Fig. 19). Less dense and no capillaries were seen between the collagen mass. At 28 days (PO); The evenly arranged (reorientation) collagen fiber, the less density of tenocytes was less than of 21 days of same technique, the nucleus of tenocytes were small and elongated, the collagen become parallel to the long axis of the tendon were

the main characters of this time (Fig. 20), also there was difficult to distinguish the site of anastomosis of the two ends of the severed tendon.

In $8\text{J}/\text{cm}^2$ cutting tendon and anastomosis, at 14 days (PO); Abundant massive collections of collagen fibers arranged in multidirectional orientations were seen, with hyper cellularity of tenocytes which have round large nucleus. The site of anastomosis was filled with multiple waves of uneven collagen. Numerous newly capillaries were seen directed with the long axis of the

tendon. No signs of inflammation were seen (Fig. 21). At the 21th day (PO): The collagen fibers were become denser and more arranged. Although there was hyper cellularity but it was less than what observed in the same technique at 14 days. The tenocytes seen have large round to oval nucleus and taking deep pigments (Fig. 22). At the 28th day (PO); The collagen fibers become parallel to each other. Although there was hyper cellularity, but the tenocyte has spindle elongated nucleus, and no signs of inflammation were observed (Fig. 23).

Fig.(5,6,7): Longitudinal sections of rat Achilles tendon of control group crushing tendon.

Fig.(8,9,10): Longitudinal sections of rat Achilles tendon of control group tendon cutting and anastomosis.

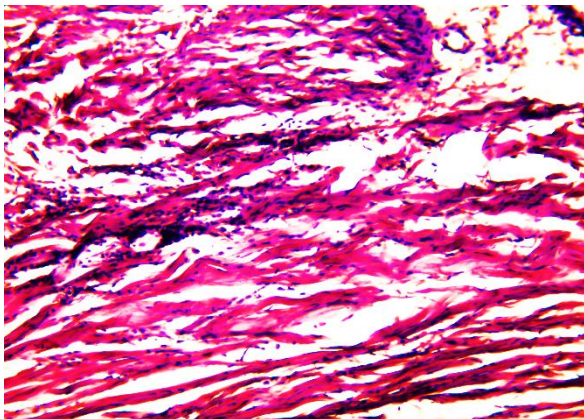


Fig. (5): 14 days (PC): Inflammatory cells are seen around newly formed blood vessels. Crimped collagen fibers with limited tenocytes also seen. (H&E Stain X10).

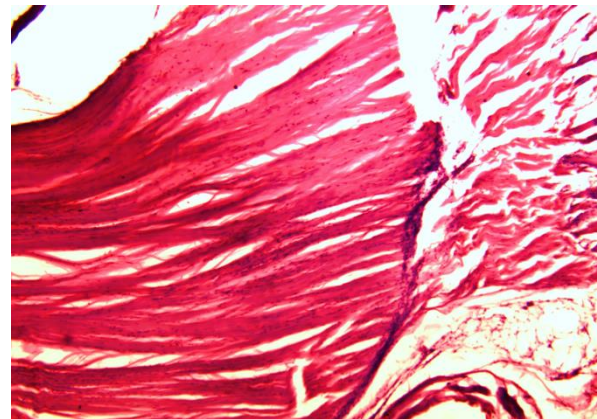


Fig. (6): 21 days (PC): The inflammation is subside. Crimped collagen fibers are seen in the crushed area compared with the normal tendon to the left (H&E Stain X4).

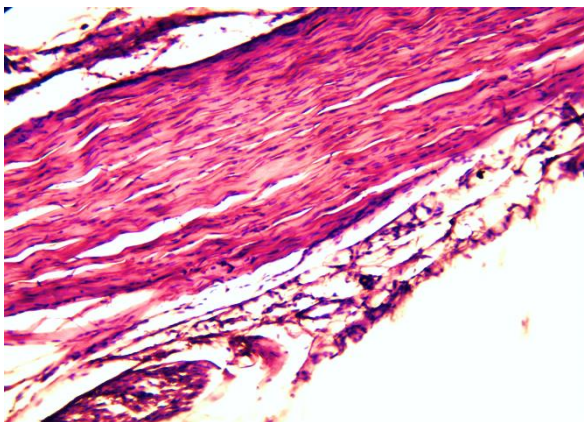


Fig. (7): 28 days (PC): No inflammatory signs are seen except in epitendon area. The collagen fibers resemble the normal with an undulation, and more tenocytes with hyper chromic elongated nucleus (H&E Stain X10).

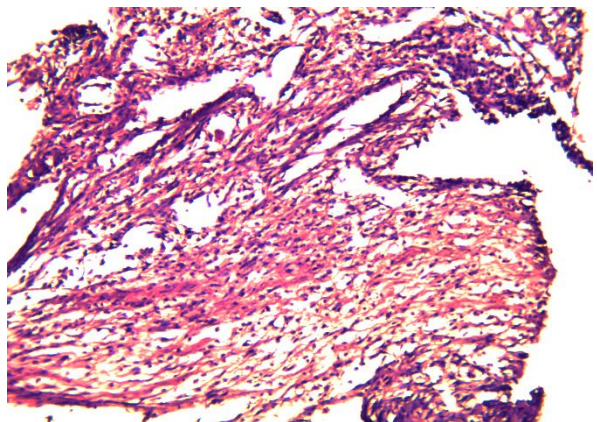


Fig. (8): 14 days (PO): Plentiful inflammatory cells are seen, many newly formed blood vessels, weak splintered mesh of collagen fibers oriented in multi directions seen at the site of anastomosis (H&E Stain X10).

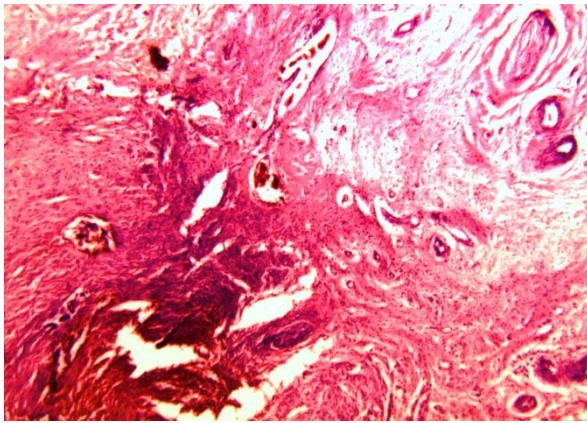


Fig. (9): 21 days (PO): Show thick and dense collagen fibers oriented in multi directions, newly blood vessels and scanty inflammatory cells at the site of anastomosis, and necrosis around the suture material (H&E Stain X5).

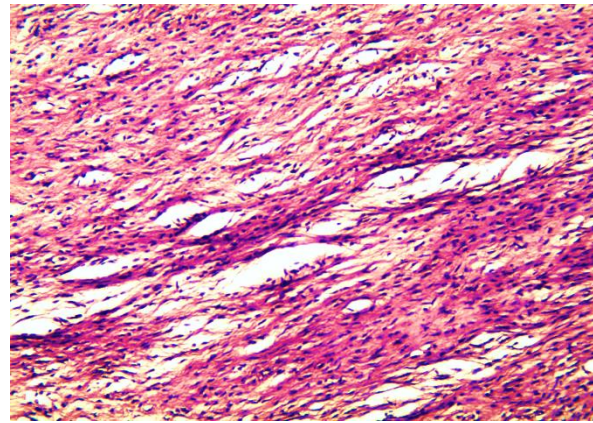


Fig. (10): 28 days (PO): Show dense collagen fibers oriented in one direction at the site of anastomosis, newly rete of blood vessels and inflammatory cells also seen. (H&E Stain X10)

Longitudinal sections of rat Achilles tendon: Crushing tendon -laser treatment groups. Fig. (11,12, and 15) 4J/cm², Fig. (13,14, and 16) 8J/cm².

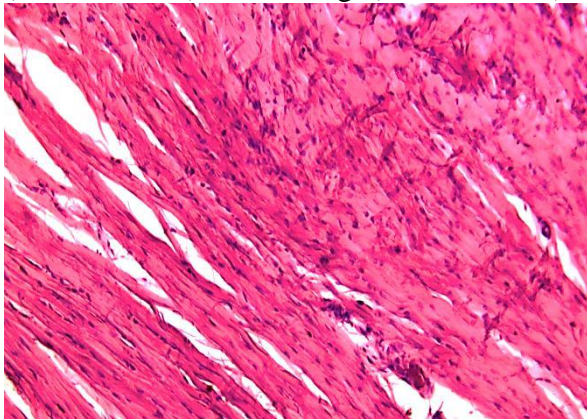


Fig. (11): 14 days (PC): Show irregular arrangement of collagens fibers invaded with numerous existence of tenocytes, with a lot of inflammatory cells (H&E Stain X10).

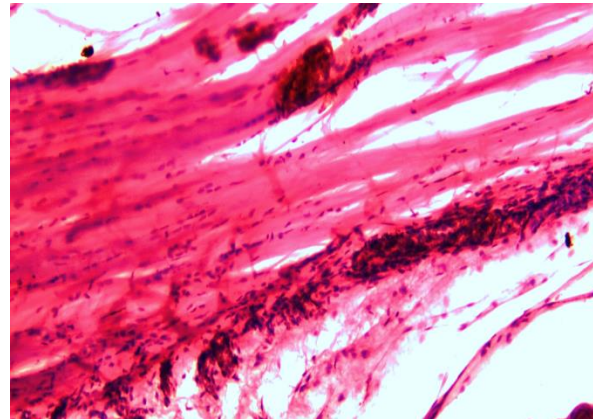


Fig. (12): 21 days (PC): Show regular arrangement of collagen fibers with profound presence of tenocytes. No signs of inflammation. (H&E Stain X10).

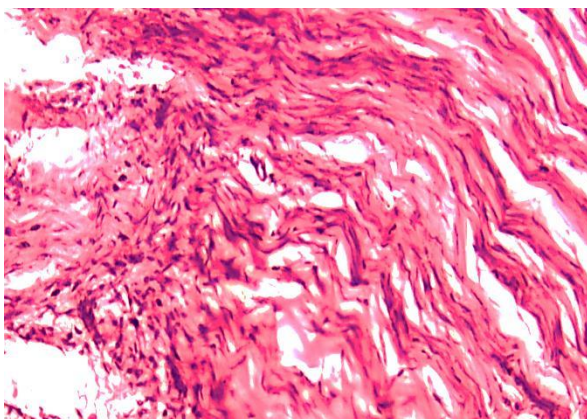


Fig. (13): 14 days (PC): Show more dense irregularly collagen fibers with hypercellularity of tenocytes, newly developed capillary vessels, less inflammatory cells, and no hemorrhage (H&E Stain X10).

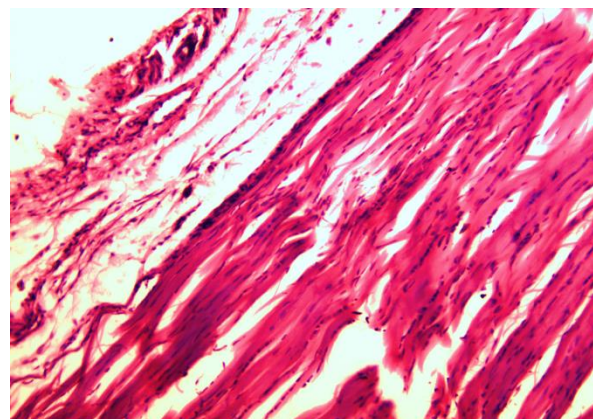


Fig. (14): 21 days (PC): Show denser collagen fibers, tenocytes hyper cellularity. No inflammation in the tendon, but more at epitendon, presence of fibrous tissue and adhesion (H&E Stain X5).

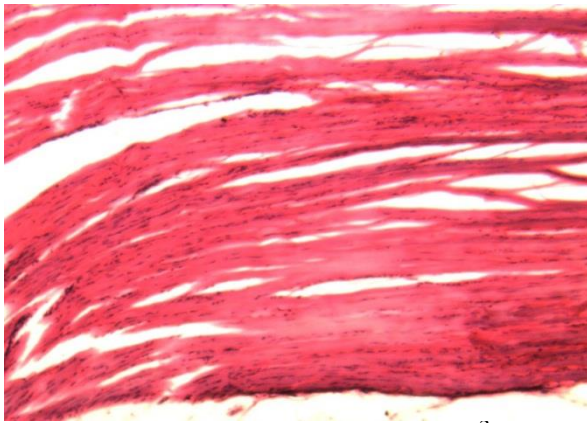


Fig. (15): 28 days (PC) of $4\text{J}/\text{cm}^2$: Show regular parallel arrangement of collagen fibers, presence of numerous tenocytes have normal nucleus size, and no inflammatory signs (H&E Stain X5).

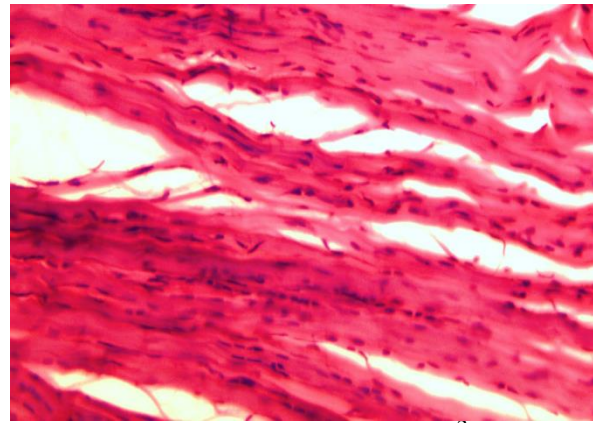


Fig. (16): 28 days (PC) of $8\text{J}/\text{cm}^2$: Regular parallel arrangement of collagen fibers are seen, presence of numerous tenocytes have normal size of nucleus, no inflammatory signs (H&E Stain X10).

Longitudinal sections of rat Achilles tendon: Cutting tendon and anastomosis -laser treatment groups. Fig. (17,18,19 and 20) $4\text{J}/\text{cm}^2$, Fig. (21,22, and 23) $8\text{J}/\text{cm}^2$.

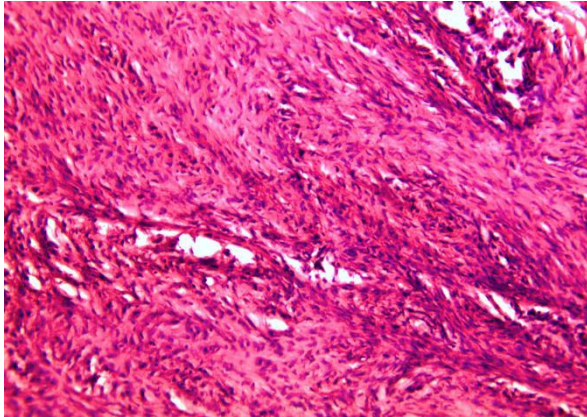


Fig. (17): 14 days (PO): Show marked tenocytes cellularity, massive collagen fibers arranged in multi directions, with plentiful newly capillaries of one direction (H&E Stain X10).

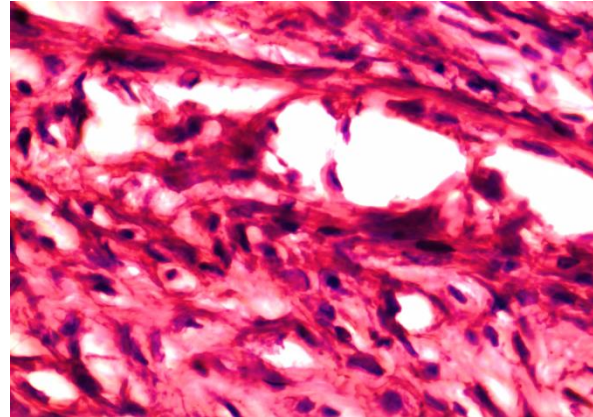


Fig. (18): 14 days (PO): Demonstrate the hyper cellularity of tenocytes have large nucleus, besides the inflammatory cells and newly formed blood vessels (H&E Stain X40)

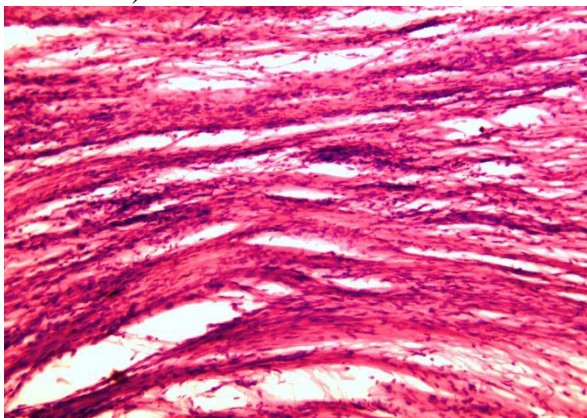


Fig. (19): 21 days (PO): The collagen fiber are seen more arranged, and reoriented with the long axis of the tendon. The tenocytes less than that of 14 days. (H&E Stain X5).

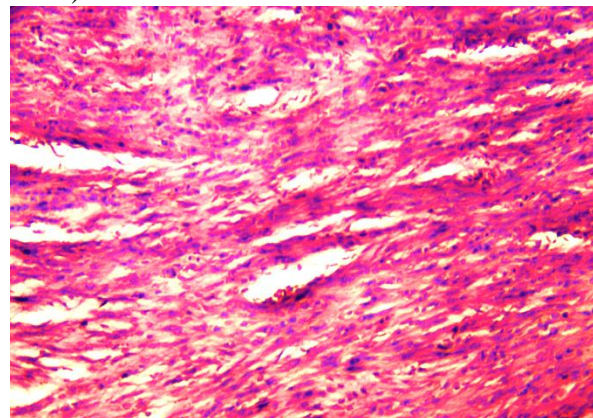
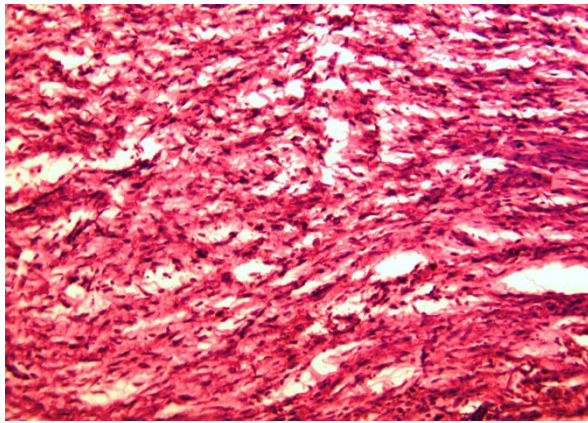
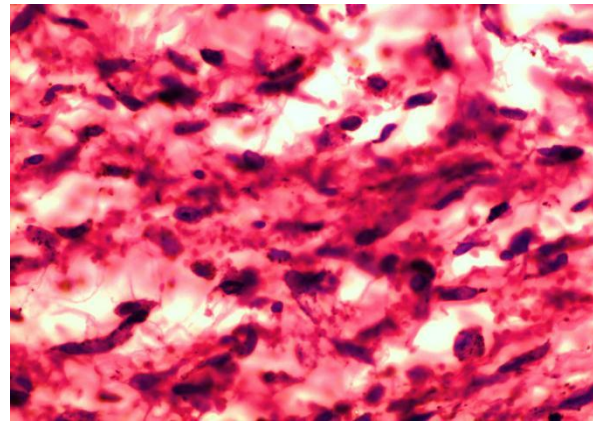


Fig. (20):28 days (PO): Collagen fibers seen reoriented with axis of tendon, and difficult to distinguish the site of anastomosis. Tenocytes less than of 21 days (H&E Stain X10).

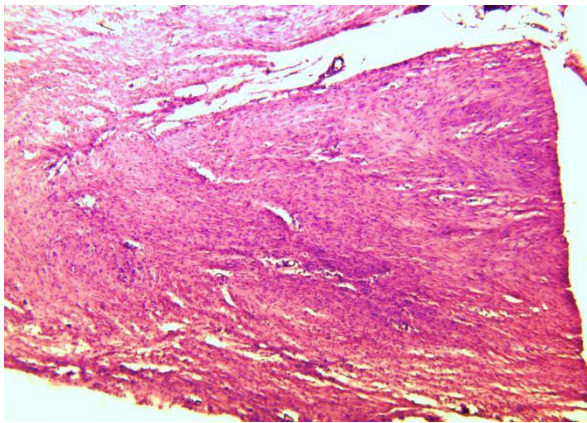


A

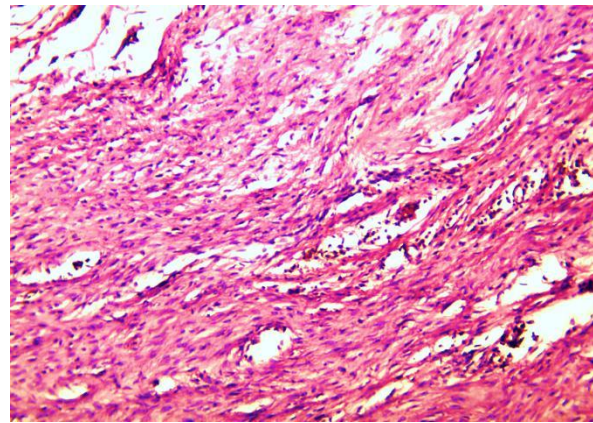


B

Fig. (21): 14 days (PO) 8J /cm²: A; Show abundant massive collections of uneven collagen fibers arranged in multidirection filling the site of anastomosis, with hyper cellularity of tenocytes. No signs of inflammation are seen. (H&E Stain X5). B; Show tenocyte have round large nucleus. (H&E Stain X40).

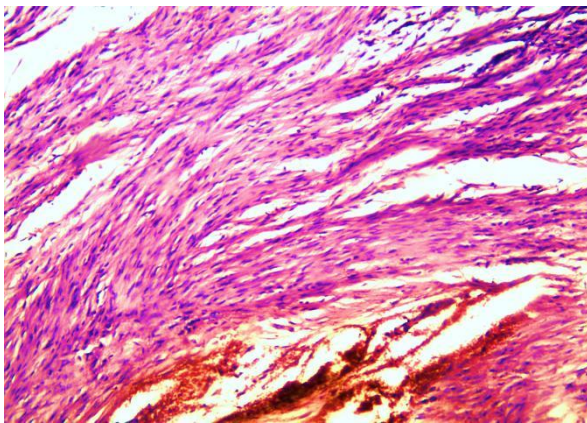


A

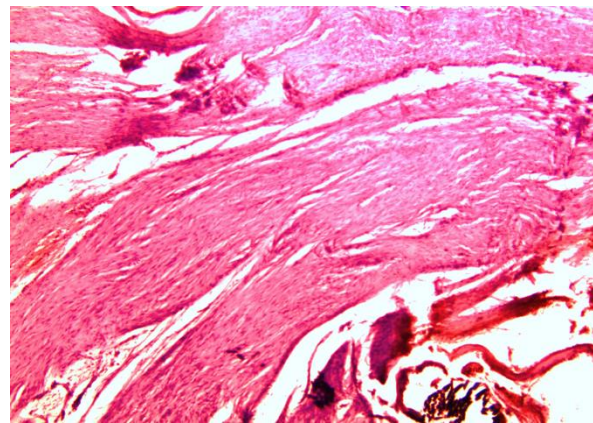


B

Fig. (22): 21 days (PO) 8J /cm²: A, and B; The collagen become more dense and more arranged, although there is hyper cellularity but it is less than 14 days, the tenocyte have large round to oval nucleus taking deep pigment. (H&E Stain X5).



A



B

Fig. (23): 28 days (PO) 8J /cm²: A, and B; The collagen fibers become parallel to each other, although there is hyper cellularity, but the tenocyte has spindle elongated nucleus, no signs of inflammation (H&E Stain X5).

Discussion

The healing of the transverse sectioned tendons is slow, take months for remodeling, and the complete regeneration of tendon is not achieved for a long time. The tissue replacing the defect remains hyper cellular, the diameter of the collagen fibrils become smaller than the original, and the biomechanical strength is significantly lower than the normal tendon. Tendon healing, even when successful, does not result in normal tendon (27), that make seeking for techniques to accelerate and improve this type of healing is mandatory. Low level laser therapy (LLLT) is one technique used to enhance healing process in general. It has shown promising results with respect to fibroblast proliferation, collagen synthesis, and tissue repair (22, 28). In laser treatment $4\text{J}/\text{cm}^2$ crushing groups vigorous healing proses is seen, the collagen fibers arrangement converted from irregular at (14 days) to regular at (21 days), with numerous existences of hyper chromic round enlarged nucleus hyperactive tenocytes between the collagen fibers, this result is in agreement with (28) and with (29) whom find the LLLT reducing the number of fibroblasts initially and improving the quality of tendon repair later, and after 14 days post treatment cause mature collagen fibers disposed in clusters aligned with the edge of the wound. Also this result is in agreement with (30) found a significant increase in fibroblast cell proliferation after laser irradiation. In laser treatment $8\text{J}/\text{cm}^2$ 14 days post operation there was more dense irregularly arranged collagen fiber with a marked increase of tenocytes (hyper cellularity of tenocytes) between the collagen fibers, newly developed capillary vessels, while after 21 days in same groups revealed there were denser collagen fibers, increased cellularity of tenocytes which have large nucleus in compare with the control and the crushing $4\text{J}/\text{cm}^2$ groups in the same period (21 days) of observation and the previous reading in the same technique, this result is corresponding with (19), demonstrated that the 632.8-nm laser (He-Ne) produced a higher deposition of collagen, increasing the tensile strength of completely severed and surgically repaired

rat tendons. Also this result is confirmed with (31), using GaAlAs laser with a wavelength of 904 nm, their results showed viability of tenocytes increased significantly at the energy density of 0.5 and $1\text{ J}/\text{cm}^2$, and also increased the proliferation of tenocytes and synthesis of collagen. In both laser doses $4\text{J}/\text{cm}^2$, and $8\text{J}/\text{cm}^2$, at 28 days post crushing were seem like each other and show resemble changes which including; complete healing process, characterized by regular parallel arrangement of collagen fibers, presence of numerous tenocytes which have normal size of nucleus, this result is in agreement with (24) whom find the low intensity laser therapy was effective in the improvement of collagen fibers organization of the calcaneus tendon after undergoing to lesion. At 14 days post operation in $4\text{J}/\text{cm}^2$, in laser treatment cutting and anastomosis there was extremely marked increased cellularity of tenocytes which have large nucleus, massive collagens fiber with random arrangement of direction, while after 21 days appear there was a large number of tenocytes but it was less than what found in previous reading of the same technique at 14 days, and the collagen fiber were seen more arranged, the reorientation with the long axis become clearer, although after 28 days revealed the evenly arranged (reorientation) collagen fiber, less density of tenocytes (less than of 21 days of same technique), the nucleus of tenocytes were small and elongated, the collagen become parallel to the long axis of the tendon were the main characters of this time, these results are corresponding with (32) reported that some wavelengths (632 nm, 820–830 nm, and 904 nm) tended to stimulate the fibroblastic metabolism more efficiently, and consequently, facilitating the mechanisms during which LLLT accelerated collagen realignment. Although 14 days after cutting and anastomosis in laser treatment $8\text{J}/\text{cm}^2$ show abundant massive collections of collagen fibers arranged in multidirectional orientations were seen, with hyper cellularity of tenocytes which have round large nucleus. The site of anastomosis was filled with multiple waves of uneven collagen, but after 21 days appear the collagen fibers were

become denser and more arranged, although there was hyper cellularity but it was less than what observed in the same technique at 14 days, in 28 days after cutting and anastomosis in same group the collagen fibers become parallel to each other, although there was hyper cellularity, but the tenocyte has spindle elongated nucleus, and no signs of inflammation were observed. The LLLT reduce the inflammation, and prevents fibrosis in rat after muscle injury (33, 34), also these results are compatible with (35) in rabbit were the LLLT cause more collagen synthesis, and with (21) demonstrated that laser irradiation could promote porcine tenocyte proliferation and up-regulation of type I collagen and decorin. This study chose to stimulate the initial phase of the healing process, remodeling it at an early stage because the strength of the healed tissue increases significantly in this phase, and to reduce and beneficial modulate the early inflammatory process as attested by some authors who demonstrated the anti-inflammatory effect of laser in the initial healing phase (33, 34). The Low-level laser therapy (LLLT) is considered to act in a bio modulatory manner through light absorption by photoreceptors, which stimulates cells and modulates inflammatory processes (36) also, it stimulates tenocyte migration (37). Both doses are seen effective but $8\text{J}/\text{cm}^2$ is better.

The LLLT delivered at low doses tends to work better than the same wavelength delivered at high levels. In general, fluences of red or NIR as low as 3 or $5\text{J}/\text{cm}^2$ will be beneficial in vivo, but a large dose like 50 or $100\text{J}/\text{cm}^2$ will lose the beneficial effect and may even become detrimental. The molecular and cellular mechanisms LLLT suggest that photons are absorbed by the mitochondria; they stimulate more ATP production and low levels of ROS, NO release in low amounts (38). The Laser has three reactions: 1) photodynamic action on membranes accompanied by intracellular calcium increase and cell stimulation; 2) photo reactivation of Cu-Zn superoxide dismutase; and 3) superoxide dismutase photolysis of the metal complexes of NO with release of this vasodilator (39, 40).

In conclusion: The vigorous of the healing process is related to the degree of injury. The more healing process is seen in the cutting and anastomosis groups. The laser are used in this study accelerate the tendon healing, and shortening the time need to reach the complete healing and maturation. The both doses (4 and $8\text{J}/\text{cm}^2$) used are effective, act in stimulating and enhance the healing process of the tendon. The dose of $8\text{J}/\text{cm}^2$ is given better stimulation effect than the $4\text{J}/\text{cm}^2$.

References

- 1-Kannus P (2000) Structure of the tendon connective tissue. *Scand J Med Sci Sports*. 10: 312–320.
- 2-Sharma P, Maffulli N (2006) Biology of tendon injury: healing, modeling and remodeling. *J Musculoskelet Neuronal Interact*. 6(2):181-190.
- 3-Nyyssonen T, Luthje P, Kroger (2008) The increasing incidence and difference in sex distribution of Achilles tendon rupture in Finland in 1987–1999. *Scand J Surg*. 97:272–275.
- 4-Tafari SA, Daly N (2001) Achilles tendon trauma. In: McGlamry ED, Banks AS, Downey MS, editors. McGlamry's comprehensive textbook of foot and ankle surgery. 3rd edition. Baltimore (MD): William and Wilkins. p. 1706–23, chapter 52, part 2.
- 5-Patterson-Kane JC, Firth EC (2008) The pathobiology of exercise-induced superficial digital flexor tendon injury in Thoroughbred racehorses. *The Veterinary Journal* 181: 79-89.
- 6-Clark DM (2001) Tendon lesion and its treatment. In: Bojrab M J (ed.), *Disease Mechanisms in Small Animal*. Giralddi, Bologna. 1414–1418.
- 7-Montgomery R, Fitch R (2003) Muscle and tendon disorders. In, Slatter D (ed.), *Textbook of Small Animal Surgery*. 3rd ed. Saunders, Philadelphia. 2266–2267.
- 8-Fahie MA (2005) Healing, diagnosis, repair, and rehabilitation of tendon conditions. *Veterinary Clinics Small Animal Practice*. 35: 1195–1211.
- 9-Kajikawa Y, Morihara T, Watanabe N, Sakamoto H, Matsuda K, Kobayashi M, Oshima Y, Yoshida A, Kawata M, Kubo T (2007) GFP chimeric models exhibited a biphasic pattern of mesenchymal cell invasion in tendon healing. *J. Cell Physiol*. 210: 684-691
- 10-Sharma P, Maffulli N (2005) Basic biology of tendon injury and healing. *Surgeon*, 3 (5): 309-316
- 11-Oakes BW (2003) Tissue healing and repair: Tendons and ligaments. In: frontera W, Editor,

- Rehabilitation of Sport Injuries: Scientific Basis. Boston: Blackwell science. p. 56-98.
- 12-Tilman LJ, Chasan NP (1996) Properties of dense connective tissue and wound healing. In: Hertling D, Kessler RM (eds.) *Management of Common Musculoskeletal Disorders: Physical Therapy Principles and Methods*. 3rd ed. Philadelphia: Lippincott. P 8-21.
 - 13-Abrahamsson SO (1991) Matrix metabolism and healing in the flexor tendons. Experimental studies on rabbit tendon. *Scand J plast Reconst. surg Hand Surg Suppl.* 23: 1-51.
 - 14-Amiel D, Akeson W, Harwood FL, Frank CB (1983) Stress deprivation effect on metabolic turnover of the medial collateral ligament collagen. A comparison between nine and 12 weeks immobilization. *J. Clin Orthop.* 172: 165-70.
 - 15-Humble R N, Nugent L L (2001) Achilles' tendonitis. An overview under conditioning model. *J.Clin.Podiatr Med.Surg.* 18: 233-54.
 - 16-Malvankar S, Khan WS (2011) Evolution of the Achilles tendon: The athlete's Achilles heel, *Foot* 21:193–197.
 - 17-Lamb CR, Duvernois A (2005) Ultrasonographic anatomy of the normal canine calcaneal tendon. *Veterinary Radiology and Ultrasound* 46: 326–330.
 - 18-Buso NC (2006) Avaliação da ação do laser arseneto de galio— 904 nm no processo de reparação do tendão de Aquiles em ratos (Evaluation of the action of gallium arsenide on the regeneration of Achilles tendons in rats). Dissertation. Instituto de Pesquisa e Desenvolvimento da Universidade do Vale do Paraíba.
 - 19-Enwemeka CS, Reddy K (2000) The biological effects of laser therapy and other physical modalities on connective tissue repair processes. *J. Laser Ther.* 12: 22–30.
 - 20-Sharma P, Maffulli N (2005) Tendon injury and tendinopathy: healing and repair. *J. Bone Joint Surg. Am.* 87: 187-202.
 - 21-Chen CH, Tsai JL, Wang YH, et al (2009) Low-level laser irradiation promotes cell proliferation and mRNA expression of type I collagen and decorin in porcine Achilles tendon fibroblasts in vitro. *J. Orthop. Res. Off Publ. Orthop. Res. Soc.* 27:646–650.
 - 22-Elwakil T F (2007) An in-vivo experimental evaluation of He-Ne laser photostimulation in healing Achilles tendons. *J. Lasers Med. Sci.* 22(1): 53–59.
 - 23-Ng GYF, Fung DTC, Leung MCP, Guo X (2004) Comparison of single and multiple applications of GaAlAs laser on rat medial collateral ligament repair. *J. Lasers Surg Med.* 34: 285-9.
 - 24-Oliveira FS, Pinfildi CE, Parizoto NA, Liebano RE, Bossini PS, Garcia EB, Ferreira LM (2009) Effect of low level laser therapy (830 nm) with different therapy regimes on the process of tissue repair in partial lesion calcaneus tendon. *J. Lasers Surg Med.* 41: 271–276.
 - 25-Gaertner DJ, Hallman TM, Hankenson FC, Batchelder MA (2008) Anesthesia and analgesia for laboratory rodents (Chapter 10). In: Fish RE, Brown MJ, Danneman PJ, and Karas AZ, (eds.), *Anesthesia and Analgesia in Laboratory Animals*. 2nd ed. American College of Laboratory Animal Medicine Series (AP), Elsevier Inc. Pp 239-297.
 - 26-Rawson S, Cartmell S, Wong J (2013) Suture techniques for tendon repair; a comparative review. *Muscles, Ligaments and Tendons Journal*, 3 (3): 220-228.
 - 27-Oryan A, Moshiri A, Meimandi-Parizi A (2012) Short and long terms healing of the experimentally transverse sectioned tendon in rabbits. *Sports Medicine, Arthroscopy, Rehabilitation, Therapy & Technology*, 4 (14): 1-10.
 - 28-Guerra Fda R, Vieira CP, Almeida MS, Oliveira LP, de Aro AA, Pimentel ER (2013) LLLT improves tendon healing through increase of MMP activity and collagen synthesis *Lasers Med Sci.* 28(5):1281-1288.
 - 29-Casalechi HL, Nicolau RA, Casalechi VL, Silveira LJr, De Paula AM, Pacheco MT (2009) The effects of low-level light emitting diode on the repair process of Achilles tendon therapy in rats. *J. Lasers Med Sci.* 24: 659–665.
 - 30-Almeida-Lopes L, Rigau J, Zangaro RA, Guidugli-Neto J, Jaeger MM (2001) Comparison of the low level laser therapy effects on cultured human gingival fibroblasts proliferation using different irradiance and same fluence. *J. Laser Surg Med.* 29: 179–184.
 - 31-Chen MH, Huang YC, Sun JS, Chao YH, Chen MH (2015) Second messengers mediating the proliferation and collagen synthesis of tenocytes induced by low-level laser irradiation. *Lasers Med Sci.* 30(1):263-272.
 - 32-Bjorndal JM, Couppe C, Ljunggren AE (2001) Low level laser therapy for tendinopathy. Evidence of a dose-response pattern. *Phys. Ther. Rev.* 6: 91–99.
 - 33-Assis L, Moretti A I S, Abrahao T B, Cury V, Souza H P, Hamblin M R, Parizotto N A (2012) Low-Level Laser Therapy (808 nm) reduces inflammatory response and oxidative stress in rat tibialis anterior muscle after cryolesion. *Lasers Surg Med.* 44(9): 726–735.
 - 34-Assis L, Moretti A L S, Abrahao T B, Souza H P, Hamblin M R, Parizotto N A (2013) Low-level laser therapy (808 nm) contributes to muscle regeneration and prevents fibrosis in rat tibialis anterior muscle after cryolesion. *Lasers Med Sci.* 28(3): 947–955.
 - 35-Reddy GK, Stehno-Bittel L, Enwemeka CS (1998) Laser photostimulation of collagen production in healing rabbit Achilles tendons. *J. Lasers Surg Med.* 22(5): 281–287.
 - 36-Karu T (2008) Mitochondrial signaling in mammalian cells activated by red and near-IR radiation. *Photochem Photobiol* 84(5):1091–1099.

- 37-Tsai W C, Hsu C C, Pang J H S, Lin M S, Chen Y H, Liang F C (2012) Low-Level Laser Irradiation stimulates tenocyte migration with up-regulation of Dynamin II expression. PLoS ONE 7(5): e38235.
- 38-Huang Y Y, Chen A C H, Carroll J D, Hamblin M R (2009) Biphasic dose response in low level light therapy. Dose-Response, 7:358–383.
- 39-Vladimirov Y A, Osipov A N, Klebanov G I (2004) Photobiological principles of therapeutic applications of laser radiation. Biochemistry (Moscow 69(1): 81-90. Translated from Biokhimiya Vol. 69, No. 1, 2004, pp. 103-113. Original Russian Text Copyright © 2004 by Vladimirov, Osipov, Klebanov.
- 40-Hamblin M R, Demidova T N (2006) Mechanisms of low level light therapy. Proc. of SPIE Vol. 6140 614001-1, Mechanisms for Low-Light Therapy, edited by Michael R. Hamblin, Ronald W. Waynant, Juanita Anders, Proc. of SPIE Vol. 6140, 614001, (2006) • 1605 7422/06/\$15