

## Detection of parasitic infections and their pathological changes in wild pigeons in Duhok province

Lokman Tieb Omer Mahdi Ali Abdulla Dyar Adil Morad

Coll. of Vet. Med. / Univ. of Duhok,

email: [dyaradil@yahoo.com](mailto:dyaradil@yahoo.com)

(Received 24 December 2014, Accepted 1 February 2015)

### Abstract

The study aimed to detect the external and internal parasites and its association with intestinal pathological changes in wild pigeons at Sumel region-Duhok Governorate. Samples of skin (plumage), intestinal contents, and intestinal tissue were taken from 100 adult pigeons from March to August 2012 for detection of parasites and for histopathological examination. Results were showed that, 6 (6 %) pigeons feather samples were found positive for external parasites (*Columbicola columbae*), 22 (22%) of fecal samples were found positive for internal parasites (*Raillietina tetragona*), whereas no trematod and nematode were found. A total of 19 (19%) infected pigeons were appeared pathological changes in intestine, which are manifested by mild catarrhal inflammation and excessive mucoid masses. In conclusion we found that the wild pigeons infested with parasites, and acting as a reservoir and spreading of parasites to other avian populations including poultry.

**Key words:** Wild pigeons, parasites, pathological changes.

### تحديد الاصابات الطفيلية وتغيراتها المرضية في الحمام البري في مدينة دهوك

لقمان طيب عمر مهدي علي عبدالله ديار عادل مراد  
كلية الطب البيطري / جامعه دهوك

### الخلاصة

تهدف الدراسة الى الكشف عن الطفيليات الخارجية والداخلية في الحمام البري في منطقة سميل في محافظة دهوك ، والكشف عن التغيرات النسيجية المرضية في الأمعاء المصابة لها ، بدأت الدراسة في اذار 2012 الى اب 2012 حيث اخذت عينات من الريش ومحتويات الامعاء ونسيج الامعاء من 100 طائر حمام بالغ وذلك للكشف عن الطفيليات وللدراسة النسيجية المرضية ، اظهرت النتائج اصابه 6 % من الطيور المفحوصة بالطفيليات الخارجية في عينات الريش نوع كولمبيكولا كولمبي و 22 % منها مصابه بالطفيليات الداخلية (ريليتينا تتراكونا) في حين لا جود للمثقبوات و الخيطيات. و اظهرت ان 19 % من الطيور المصابة كان بها تغيرات مرضية نسيجية في الامعاء ، التي تمثلت بالالتهاب النزلي الشديد و وجود كتل مخاطينية غزيرة. نستنتج من الدراسة ان الحمام البري مبتلى بالطفيليات ويعمل كخازن لهذه الطفيليات ويساعد على نشرها الى تجمعات الطيور الاخرى وبضمنها الدواجن.

**الكلمات المفتاحية:** الحمام البري ، الطفيليات ، التغيرات النسيجية المرضية.

### Introduction

Pigeons (Order Columbiformes) are ubiquitous birds and can be found in virtually every town and city around the globe, *Columba livia* is a species that descends from wild rock pigeons (1). Pigeons are wild distribution except for the poles. Pigeons live beside with humans and other animal species in the nature and they are bred as source of food, hobby, symbol and for experimental aims (2, 3). Three species of pigeons were included viz, stock dove (*Columba oenas*), rock mountain dove (*C. livia*), and collared

doves (*Streptopelia decaocto*). The Prevalence rate of these three species are 22%, 17.5% and 10%, respectively, high infection rates were reported in squabs of all birds of the three groups (4). Another study, presence of 17 species or genera of internal worm in ducks and 12 species in geese. The most common nematode recovered in ducks and geese was *Capillaria* represented with 38.75% in ducks and 42.5% in geese, while the common trematode species were *Noticotylus attenuatus* found with 10% in

ducks and 17.5% in geese. *Raillietina* represented with 22.5% and 50% in ducks and geese respectively as a major cestodes genus recovered (5). On the other hand three types of helminthes, in the digestive tract of starling birds were reported, one of each: cestodes *Choanotaenia musculosa*, Acanthocephalae *plagiorhynchus* sp., trematodes *Brachylaema fuscum* and one type of helminthes (nematodes) *Diplotrriaena tricuspis* was identified in the body cavity of these birds too. Prevalence rates with these helminthes were 92.3%, 30.7%, 12.3% and 56.9% respectively (6). Pigeons can carry fleas, ticks, mites, and other parasites (7, 8). They have a role in spreading some zoonosis to people portends it as potential carrier of zoonotic parasites or, encephalitis, histoplasmosis, Newcastle disease, ornithosis, cryptococcosis, coccidiosis, toxoplasmosis, pseudotuberculosis, and salmonellosis as well as being a reservoir of many parasitic disease for poultry (9, 10). Various parasites significantly impede pigeon growth, development and productivity. It at times result to death of birds especially the squabs (11). Therefore the aims of the study was to detect the infestation of wild pigeon with parasites and its interaction with man and other domestic and wild birds.

## Materials and methods

### Study area:

The pigeons of this study were housed in two faculties (Agriculture and Veterinary Medicine) at University of Duhok which located in Sumel district, west of Duhok City, Kurdistan Region, Iraq. A total of 100 Adults different aged pigeons were captured with a fine mesh net at different times between March and August 2012. Thereafter, the pigeons were caged and taken to the animal house at the faculty of Veterinary Medicine.

### Sample collection:

The pigeons were grossly inspected for the detection, collection and identification of ecto- parasites, and set loose immediately after that any ectoparasites found were collected from the skin and/or plumage were preserved in 70% of alcohol. In many cases,

it was possible to identify these species depending on their distinctive characteristics, and hence determine their prevalence and intensities, by directly examination under low-power objectives identified by using an Olympics microscope. Whole of pigeon body were opened by surgical scissor and scalpel with blade. The cadaver of each pigeon was eviscerated. This process involved complete separation of the digestive tract (from esophagus to cloaca). The content and scrapings from the mucosa of each anatomical part were examined. Helminthes from each bird were collected and put in a sterile Petri dish, cleaned in saline, their numbers counted, and initially identified with the help of a dissecting microscope and then preserved in 70% ethanol for subsequent processing. Also recording any macroscopic and pathological lesions, after that small pieces of small intestine were taken and preserved in small plastic tube contains 50 ml of (10%) formalin then sent to the pathology laboratory in Veterinary Duhok Research Center.

### Pathological examination:

The postmortem lesions were recorded from such birds and the specimens from the lesions in different part of intestine were collected, fixed in 10 % neutral buffered formalin. Tissues were dehydrated in different concentration of ethanol, cleared in xylene and embedded in paraffin wax at melting point 56-58°C for preparation of paraffin block. Section were made at 5 micrometers with rotary microtome (leice, Germany), then slides were stained with H & E Stain according to (12).

## Results

### A-Parasite detection

Out of 100 pigeons examined, only 6/100 (6%) were seen infested with one type of ectoparasites (*Columbicola columbae*) while 22/100 (22%) were infected with one species of endoparasite (cestoda) (*Raillietina tetragona*) (fig. 1).

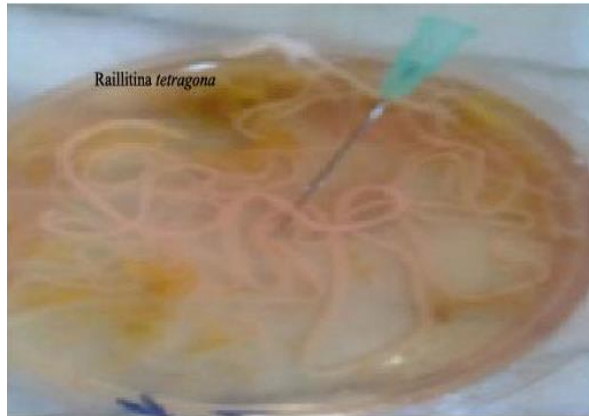### B-Pathological lesions

19/100(19%) of examined biopsy were detected pathological lesions.

### 1-Macroscopically examination

The principle cross lesions of affected parts of intestine especially duodenum showing number of long parasite inside the lumen of intestine, the intestinal wall thin, dilation and contains watery or creamy and excessive amounts of mucous with gas.

### 2-Microscopical examination

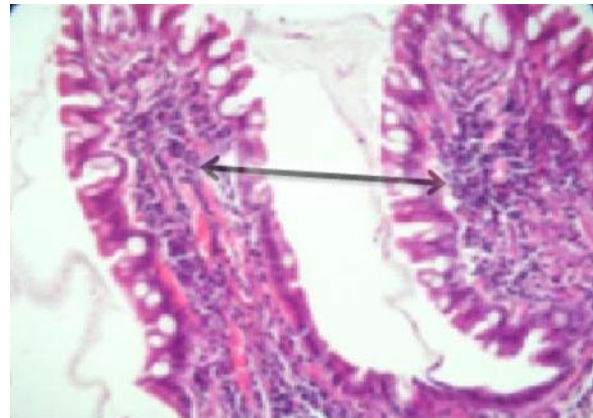


**Fig. (1):** Showing the interanl parasite (*Raillietina tetragona*) has been takeoff from small intestine.

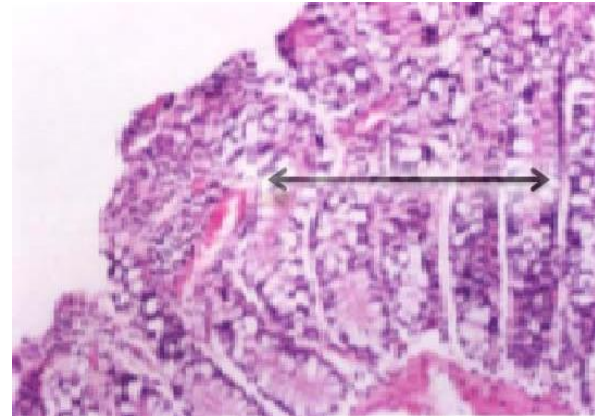
### Discussion

Parasites are emerging as a significant avian pathogen on a global scale, both ecologically and economically. However, important gaps remain in our understanding of its epidemiology and pathogenicity in wild populations, particularly in non-native hosts. The present study demonstrated a total of 2 species of parasites which included 1 species of ectoparasite (*Columbicola columbae*), and 1 species of cestod (*Raillietina tetragona*) of making the first record of wild pigeon's parasites in Duhok city. (13) were recorded that different types of parasites twenty eight species in his study about rock pigeons in Iraq which differ from our study was due to collecting specimens of living pigeons from different location of country. While in present study two types of parasites were found this due to specimens collected at same location, as well as (14) reported about racing pigeons never detected *Raillietina tetragona*. While others (15, and 16) were reported in domesticated pigeons that results of (*Raillietina tetragona*) which is less than present study results while different species

Result of histopathological examination of infected organ showing a mild catarrhal enteritis associated with thickening of mucosal layer by goblet cells, a lamina propria infiltrated by number of inflammatory cells mainly lymphocytes and hetrophiles as well as congestion of blood vessels (fig. 2 and 3).



**Fig. (2):** Histopathological section of intestine show infiltration of lymphocytes in the lamina propria (arrow) (H & E Stain X40).



**Fig. (3):** Histopathological section of intestine indicate thickening of mucosal layer and presence of mild catarrhal enteritis (arrow) (H & E Stain X40).

of (ecto and endo) parasites were recorded. These result may be due to abundance and presence of intermediate host (like ants, cockroaches, beetles, earth worms and some mollusks), the host species and its feeding habits and other climate factors like temperature (as it may effect on the presence of intermediate hosts) and other geographical factors (17), (18). Furthermore (19) were

reported different types of ectoparasite, the total numbers of infection in birds were 80% (70% in feral pigeon and 10% in domestic pigeon), in which is higher than present study due to near living habit. While (20) showed that result of *Raillietina tetragona* in rock doves is (22.6%) which is similar to our study. In Conclusion, that the wild pigeons infested with parasites, and acting as a reservoir and spreading of parasites to other avian populations including poultry.

Furthermore carrier for many intestinal infections and constitute a continuum subject of infection by a diversified community of endoparasites as well as infestation by ectoparasites. Prevent of arriving pigeons from around the poultry farms as well as from food and water handling facilities is an essential factor for the effective control of pigeon parasites and diseases. Through applies good biosecurity.

## References

- 1-Marques SM, Quadros RM, Da-Silva CJ Baldo M (2007) Parasites of pigeons (*Columba livia*) in urban areas of langes, Southern Brazil. *Parasitol Latinoam.* 62: 183-187.
- 2-Cooper JE (1984) A veterinary approach to pigeons. *J. Small Anim. Pract.* 25:505-516.
- 3-Harlin RW (1994) Pigeons The veterinary clinics of North America. *Small Anim. Pract.* 24:157-173.
- 4-Al-Bakry HS (2009) Prevalence of avian trichomoniasis in different species of pigeons in Mosul. *Iraqi Veterinary Sciences Journal.* 23 (2).
- 5-Al-Tae AF, Mohammed RG, Mohammed NH (2011) Diagnosis of some helminthic eggs in feces of ducks and geese in Ninevah governorate, Iraq. *Iraqi Veterinary Sciences Journal.* 25 (1).
- 6-Saeed ARKh, Zaman ASI, Amjed F B (2003) Preliminary investigations for the parasitic helminthes of the starling *Sternus Vulgaris* in AL-Rashdia district (Baghdad) *Bull. Iraq nat. Hist. Mus.* 10 (1):89-95.
- 7-Balicka-RamisA, Tomza-Marciniak A, Pilarczyk B, Wieczorek-Dabrowska M, Bakowska (2007) Intestinal parasites of parrot's.
- 8-Adang K L, Oniye S J, Ezealor A U, Abduand P A, Ajanusi O J (2008). Ectoparasites of domesticated pigeon(*Columba livia domestica*, *Linnaeus*), *Res.J Parasitol.*,3:79-84.
- 9-Kaminjolo J S, Tikasingh E S, Ferdinand G A A (1988). Parasites of the common pigeon (*Columba Livia*) from the environs of port of Spain, Trinidad. *Bull. Anim. Health Prod. Afr.*, 36:194-195.
- 10-Piaseki T (2006) Evaluation of urban pigeon (*Columba Livia furbana*) health status in relation to their threat to human. *Medycyna Weterynaryjna* 62:531-535.
- 11-Mohammad H R, Saeid F E, Norouzi A, Mohammad M D, Hadi R S (2011) Research 4(1):18-23,Issn: 1993-5412
- 12-Luna LG (1968) Manual of histological staining methods of the Armed Forces Institute of Pathology, 3<sup>rd</sup> ed. McGraw-Hill, New York. Pp 34.
- 13-Shlemon Al-Barwari, Isam S (2012) The Parasitic Communities of the Rock Pigeon *Columba livia* from Iraq: Component and Importance. (*Turkiye Parazit Derg* 2012;36:232-9).
- 14-Ali MB, Ali LM, Mostafa R (2012) Pathological study of parasitism in racing pigeons: An indication of its effects on community health. *African Journal of Biotechnology.* 11(59), pp.12364-12370.
- 15-Natala AJ, Asema dahum ND, Okubanjo. OO, Ulayi BM, Owolabi YH, Jato ID, Yusuf K. (2009) A survey of parasites of domesticated pigeon (*Columba livia domestica*).*international journal of soft computing* 4(4):148-150
- 16-Msoffe PLM, Muhairwa AP, Chiwanga GH, Kassuku AA (2010) A study of ecto and endoparasites of domestic pigeons in Morogoro Municipality, Tanzania. *Afr. J. Agric. Res.* 5: 264-267.
- 17-Mustafa FA (1984) Epidemic study on some cestode infecting the elementary canal of pigeons. *M. Sc. Theses, Coll. Sci., Univ. Basrah.* 113p.
- 18-Soulsby EJJ (1986) Helminthes, arthropods and protozoa of domesticated animals. 6th ed. Bailliere Tindal, London UK. 805.
- 19-Al-Shuaabi MM (2007) Study of prevalence ectoparasites in pigeon (feral & domestic) in Al-Anbar city. *Andar agriculture science journal.* issue (2).
- 20-Mohammad RZ, Ameen AA, Shobrak MY (2012) Tape worms of rock dove and domestic chicken in Taif area. *Journal of the Egyptian Society of Parasitology, Vol.42, No.3*