

**Turmeric extract ointment and diode laser for treatment of open wound****Hajar Fadhil Abdul-zahra, MSc and Thaier Alwan Abid, PhD****Department of Surgery and Obstetric / College of Veterinary Medicine / University of Al-Qadisiyah / Ad Diwaniyah-IRAQ - Correspondence: Abid TA, Thaier.abid@qu.edu.iq****Abstract:**

The study was aim to evaluate the effects of topical application of 20% turmeric extract ointment and $8\text{J}/\text{cm}^2$, 660nm λ diode laser therapy in treatment of open wounds in mice model. Thirty adult male mice, approximately weighing (50g), and aged (60-70 days) were utilized and randomly divided into two equal groups. Mice were anesthetized by IM injection mixture of Ketamine and Xylazine (80 mg/kg BW of Ketamine and 10 mg/kg BW of Xylazine). Animals were prepared for aseptic surgery, and then made two parallel vertical circular full thickness (0.5 cm) skin incisions on the back of each animal. G1 (control group) left without treatment. G2 (turmeric extract ointment + diode laser treatment group), in which the cranial wounds were treated with a topical application of $200\text{ mg} / \text{cm}^2$ of 20% turmeric extract ointment in addition to $8\text{J}/\text{cm}^2$, 660nm λ diode laser treatment once daily for 7 successive days post wounding (PW), and the caudal wound was left without treatment as a control in the same animal. Wounds were evaluated both grossly and histopathological. For histopathological assessment, specimens were taken after 7, 14 and 21 days PW. Grossly at 7, and 14 days, the size of the treated wounds in the treated group were significantly $P < 0.05$ smaller than that of the control group and control wounds of the same animal, whereas the readings converged at 21 days. Microscopically; G1 on day 7 exhibited thin early re-epithelialization of epidermal layers, the dermis had developed new blood vessels, infiltration of inflammatory cells, and the dermo-epidermal interface had vacuolations. At 14 days, the epidermis developed stratum corneum hyperkeratosis, thin irregularly arranged re-epithelialized layers. Acantholysis, inflammatory cells, blood vessels, accumulation of fibroblasts and thick evenly collagen fibers in the dermis. G2 at 7 days PW displayed hyper cellular well-regenerated epithelial layers, and accumulation of collagen fibers, inflammatory cells, and fibroblasts in the dermis. At 14 days PW, thick well-differentiated epidermal layers resting on clear basement membrane were seen. In the dermis there were dense mature collagen fibers, numerous hair follicles and sebaceous glands. At 21 days PW, the regenerated epidermis was laying on the foundation membrane, giving it its typical look. The dermis layer also had a large number of hair follicles that are at various stages of development along with collagen fibers, and fibroblasts. Used of 20% turmeric extract ointment with diode laser had a synergistic effect on the healing of open skin wounds.

Key Words: Turmeric, curcumin, diode laser, wound healing**Introduction**

To repair skin wounds after injury, the epidermal barrier and tissue architecture require intricate and well-coordinated interactions between various cells (1). The wound healing is a multi-stage achievement that requires the activation, recruitment of numerous cell types as keratinocytes, endothelial cells, fibroblast, inflammatory cells, and macrophage which

appear to be central to this process (2). Open wounds cause significant tissue injury, are polluted, or are infected; they are left to heal entirely through contraction and epithelialization (healing by second intention). The benefit of healing by second intention is that it enables steady, progressive tissue debridement during the initial stages of wound



debridement. Open wounds provide for the best wound drainage (3). A complex process called healing can be broken down into at least three ongoing and overlapping stages: an inflammatory response, a proliferation phase leading to tissue restoration, and eventually tissue remodeling (4). The inflammatory stage starts with platelet aggregation and fibrin clot formation, which restores hemostasis and supplies an extracellular matrix for cell movement (5). Numerous mediators secreted from damaged tissue cells and capillaries, activated platelets and their cytokines, and hemostasis byproducts all serve to initiate this phase (6). After the inflammatory phase, the succeeding proliferative phase lasts for about 2 to 3 weeks and is characterized by the development of granulation tissue and epithelization (7). In the second step, epithelial tissues are produced over the wound site a part of the re-epithelization phase, which also involves contraction of the wound edges pulling together to decrease the defect (8). Compared with closed wounds, open wounds have a different epithelization process. After a bed of granulation tissue has developed, epithelization takes place in open wounds. Before epithelization begins, there is a latent phase of around 4 to 5 days. In closed wounds, epithelization may be finished in 48 hours as the epithelium migrates through the fibrin clot (3). A reduction in cell density and an increase in collagen organization in the granulation tissue that forms a scar are the hallmarks of the remodeling phase of wound healing (9). Myofibroblasts are crucial for the contraction of the wound and the development of scars during the remodeling phase (10). Photobiomodulation therapy (PBMT) or low level laser treatment (LLLT) is a sort of phototherapy that aids in the stimulation of wound healing in a number of clinical contexts. When utilized at the proper wavelength, intensity, and dose, LLLT can accelerate tissue repair (11). Because it encourages quicker restoration of structural and

functional integrity and better regeneration, LLLT is effective in treating open wounds (12). By increasing tissue oxygenation, morph-functional activity, and noticeably widening the microcirculation bed, the LLLT emission expedited the functional recovery of the injured area (13). By reducing inflammation and expediting the proliferative and maturation phase, laser stimulation improved the regeneration of damaged epidermis and the healing of damaged striated muscle (14). It may alleviate inflammation-related pain by lowering prostaglandin E2, TNF-, neutrophil granulocyte influx into cells, oxidative stress, edema, and bleeding (15). LLLT accelerates the healing of wounds by enhancing fibroblast biological activity and differentiation as well as reducing inflammation (16). After laser therapy, the hydroxyproline content, fibroblast count, collagen fiber density, and skin layer thickness all saw substantial improvements. A considerable proportion of hydroxyproline, which is infrequently found elsewhere, is present in collagen (17). The scientific name for turmeric is *Curcuma longa*, and it is a member of the ginger family, Zingiberaceae. A chemical known as curcumin is one of the most crucial elements. Curcumin molecule has garnered a lot of attention; the mechanisms underlying wound healing are intricate and have long presented difficulties to researchers studying wound healing (18). Curcumin, known chemically as diferuloylmethane or 1,7-bis (4-hydroxy-3-methoxyphenyl)-1, 6-heptadiene-3, 5-dione, is a naturally occurring low molecular weight polyphenolic phytoconstituents (19). Treatment with curcumin accelerates the healing of both healthy and damaged wounds by reducing the amount of time needed for healing, boosting collagen deposition, and increasing fibroblast and vascular density. The advantages of curcumin and its potential to be created as a strong nontoxic medication for treating skin problems (20). In recent years, it has been more



important than ever to research curcumin and its pharmacological effects (21).

The purpose of this study was to determine the role of topical application of 20% turmeric

extract ointment and diode laser in treatment of open wounds.

Materials and Methods

Thirty (30) adult male mice (50 gm weight), aged (60-70 days) were used and divided into two equal groups. After general anesthesia with Ketamine (80 mg/kg BW) and Xylazine (10 mg/kg BW) intramuscularly and animals were prepared for aseptic surgery, two vertical open circular full-thickness (0.5 cm in diameter) skin incisions on the back of the animals were made (22). One incision was treated and the other was left without treatment as a control in the same animal. Animals were housed in standard laboratory settings (room temperature 20–24 °C and humidity 60%). Solid food and water were available and provided at all times. G1 (Control group); did not receive any treatment and the wounds left to heal by second intention. G2 (Laser and Turmeric treatment group); The cranial wounds were treated with a topical application of 200 mg / cm² of 20% turmeric extract ointment in addition to 8J/cm², 660nm λ diode laser treatment once daily for 7 successive days PW. The study was conducted according to the national guidelines for the Care and Use of Laboratory Animals. All protocols were approved by the High Committee for Review and Approval of Research Proposals of the Faculty in the University of Al-Qadisiyah College of Veterinary Medicine.

Turmeric extraction and ointment preparation:

Extraction methods:

Using the traditional extraction method and the Soxhlet apparatus, turmeric was extracted. Turmeric (*Curcuma longa*) dried rhizomes were purchased from the local markets. Rhizomes were grinding in a dry grinder for 20 minutes. The grinding powder was then put through a sieve with a mesh size of 212 microns to nearly

completely remove any coarse fibers. For the extraction, 250 grams (g) of sieved turmeric powder were used. To come into contact with new solvent condensed from the solvent reservoir, 50 g of the sieved turmeric powder were taken and placed in the extraction thimble (which serves as filter paper) each time. The round bottom distillation flask was filled with a total of 500 milliliters of ethanol 99% as a solvent. The ethanol in the flask evaporated as it was heated, and then it flowed into the condenser and was transformed into a liquid that trickled into the extraction chamber containing the sieved turmeric powder material. The extraction chamber was made to get an overflowing solvent that trickled back down into the boiling flask when the solvent level around the sample surpassed a certain level. The turmeric rhizome powder was extracted at 60 °C for 8 to 12 hours. Upon completion of the extraction procedure, the substance is poured into Petri dishes and let to sit until the alcohol has completely evaporated. The dishes are then placed in an oven set to 50 degrees Celsius to finish drying the substance before being scraped and ground to create the turmeric powdered extract (23).

Ointment preparation methods:

By triturating the extract powder using a mortar and pestle in the base (Vaseline), the ointment was created (24, 25). Five grams of turmeric extract powder and twenty grams of Vaseline were combined in a glass mortar to create a 20% w/w turmeric extract ointment. A little amount of Vaseline was added, and then more amounts of the base were added and triturated with a pestle until the entire 5 gram extract powder was combined with the entire base (20gm Vaseline). Trituration was carried



out gradually by adding more base until it was uniform. To increase the homogeneity of the combination, the mixture was transferred to a container and thoroughly stirred by repeatedly inverting it using a vortex mixer for 10 minutes. In order to be utilized later, the produced ointment was put in a dark container and kept at room temperature until use (24, 26, 27).

Laser treatment:

Laser treatment (8J / cm²) energy density, (660 nm λ) diode laser (Gallium Aluminum Arsenide Laser (GaALAs) (Omega Laser System Limited UK)), achieved immediately after making of open skin wound, and daily repeated once a day, for seven consecutive days. Laser probe was closed and perpendicular on the center of wounds.

Morphometric assessment of the wound healing:

Wounds were examined for changes in skin color, presence of fluids, and presence or absence of infection (28). Using a graduated millimeter measurement ruler, the wound dimensions were directly measured at days 7, and 14. Changes of wound size and wound contraction are used to assess healing process. Earlier on days 0 and 7 the size of circular wound equal to (half diameter)² x 3.14, and at

day 14, when the shape of the wound altered, the size of wound (surface area) was calculated as Length x Width. The wound contraction was measuring by the following formula; Percentage of wound contraction = (wound area on day 0 - wound area on day n / wound area on day 0 X 100) (29, 30). Morphometric data were statistically analyzed, using Least Significant Difference (LSD) test to find out the significance between groups under the level of P<0.05 (31).

Preparation of specimens for histopathological examinations

Specimens of healed skin (wound biopsies) (1 cm³) were taken at 7, 14, and 21 days PW, preserved in 10% neutral buffered formalin solution and sent for processing, staining, and histopathological examination after sectioning in 5 μ m and staining with Hematoxylin and Eosin stain to evaluate the progress of healing process (32,33).

Ethical approval

The study protocol was approved by the College of Veterinary Medicine, University of Al-Qadisiyah, Iraq.

Results

Morphometric assessment of the wound healing:

Clinical evaluation: During the course of the experiment (21 days), all animals were sighted, healthy, and active. Whether the animals received treatment or not, no infection was discovered in any of their wounds and no fatalities were noted. All wound locations were swollen and erythematized within 4 hours of injury, and they continued to do so over the following 24 hours post-wounding (P.W.) with an intensification of inflammatory symptoms. The wound site developed a thick scab due to blood drying out starting on the second P.W. day, and lasting until the seventh P.W. The

entire wound widened, and the borders were raised and red in color. The wound gradually shrank in size until it became a little, circular or linear patch of scar tissue at 21 day.

Surface area (Wound area) (Size of wound):

On day zero, the wound surface area (mm²) in both control and treated animals was (19.62 mm²). At 7, 14, and 21 days the size of wound in treated group was significantly reduced P< 0.05 when compared to control group and control readings in same animal, whereas the readings of G2 at 21 days (1.8 mm²) was became significantly smaller than control and control readings of the same animal (table 1).



Wound contraction: The percentage of wound contraction was significantly increased ($P < 0.05$) in treated group at 7th, 14th, and 21st days as compared with control group. G2 (turmeric and laser treated group) recorded significant decrease of wound size (7.06, 2.75, and 1.8 mm² respectively), and significant percentage of wound contraction (64.02%, 85.98 and 90.82 % respectively) at 7, 14, and 21 days (table 1). The edges of the wounds initially at day 0 were seen clean, and marked sharp (Fig.1), then all the wound became swollen before it returns to the first level. The wounds of G1 at 7th day show no signs of inflammation, little decrease in the size of wound in compare with day 0, and the wound was covered with thin scab. On day 14th the scab was not found, more decrease in the size of wound was occurring, and scar tissue was developed. On 21 day PW, scar tissue was seen on wound site, and more decrease in the size of wound but it still large and obvious. The treated wounds of G2 at the 7th day PW showed little reduction in size in compare with incisions of control in same animal. On 14th day PW the treated incisions show more reduction in size in compare with control incisions, and no scab cover the incisions (Fig.1). On the 21st day PW the treated wounds showed more reduction in size in compare with control of same animal. The shape of incisions sometimes remains circular and other times change to linear (Fig.1).

Histopathological assessment of the wound healing:

Proceeding of edema, vascular proliferation, vascular congestion, infiltration of the inflammatory cells, fibroblast proliferations, and production of granulation tissue, were the histopathologic assessments be made of (28, 34, 35, 36). Wounds of G1 7th day PW showed thin re-epithelialization of epidermal layers covered by crust over the wound site, and characterized by hyperkeratosis, presence of acantholysis caused by inflammation, and the extension of the

epithelial projection from the wound's edges. Newly developed blood vessels, inflammatory cell infiltration (neutrophils and lymphocytes), and vacuolar interface dermatitis were all present in the dermis (vacuolization at the dermoepidermal junction). With strong inflammatory reactions, the separation between the re-epithelialized epidermis layers and dermis layers was clearly visible (Fig.2). At the 14th day, G1 wounds showed a gap or acantholysis between the epidermis and dermis, as well as thin, irregularly arranged re-epithelialized epidermis layers resting on an irregularly arranged stratum basale layer. In the dermis, inflammatory cells had infiltrated and there were clogged blood vessels. In the dermis beneath the incision site, there was also an aggregation of fibroblasts and thick collagen fibers that were organized unevenly (Fig.2). Wounds of G2 at 7th day PW exhibited hyper cellular, well-regenerated epithelial layers that were covered by thick scab. The regenerated epidermis includes the growth and regeneration of various epidermal cells, such as the stratum corneum, stratum granulosum, stratum spinosum, and stratum basal cells, as well as the accumulation of collagen fibers were arranged randomly. The dermis also accumulates inflammatory cells and fibroblasts (hyper cellular infiltration). At 14th day PW, transparent basement membrane was supported by thick, well-differentiated epidermal layers. Four thick layers, including a thick keratin layer, made up the epidermis. Large and hyper chromic, the cells. The dermis was made up of mature, thick collagen fibers. Sebaceous glands and many hair follicles were visible. At 21st day PW, The regenerated epidermis had a typical conventional look with multiple inner invaginations toward the dermis while resting on the basement membrane. Under the newly formed epidermis the dermis compose collagen fibers were uniformly distributed along with fibroblasts, inflammatory cells, and many hair follicles in various stages of development.



Some areas still had scabs covering the dermis and epidermis, which had undergone successful regeneration.

Table (1); Surface area (wound area) and wound contraction.

Periods	Groups	Surface area (mm ²)		Wound contraction %	
		Treated	Control	Treated	Control
0 day	G1, G2	19.62Aa	19.62Aa	0Ja	0Ia
7 days	G1	15.43Ba	15.43Ba	21.3Ia	21.3Ha
	G2	7.06EFb	14.28Ca	64.02Fa	27.23Gb
14 days	G1	12.3Ca	12Da	37.3Ha	38.8Fa
	G2	2.75IJb	9.9Fa	85.98Ba	49.5Db
21 days	G1	6.2Fa	6Ga	68.3Ea	69.4Ca
	G2	1.8Jb	3.6Ia	90.82Aa	81.65Ab
LSD(P<0.05)		1.04		3.16	

- Means with different capital letters in the same column and small letters in the same row are significantly different

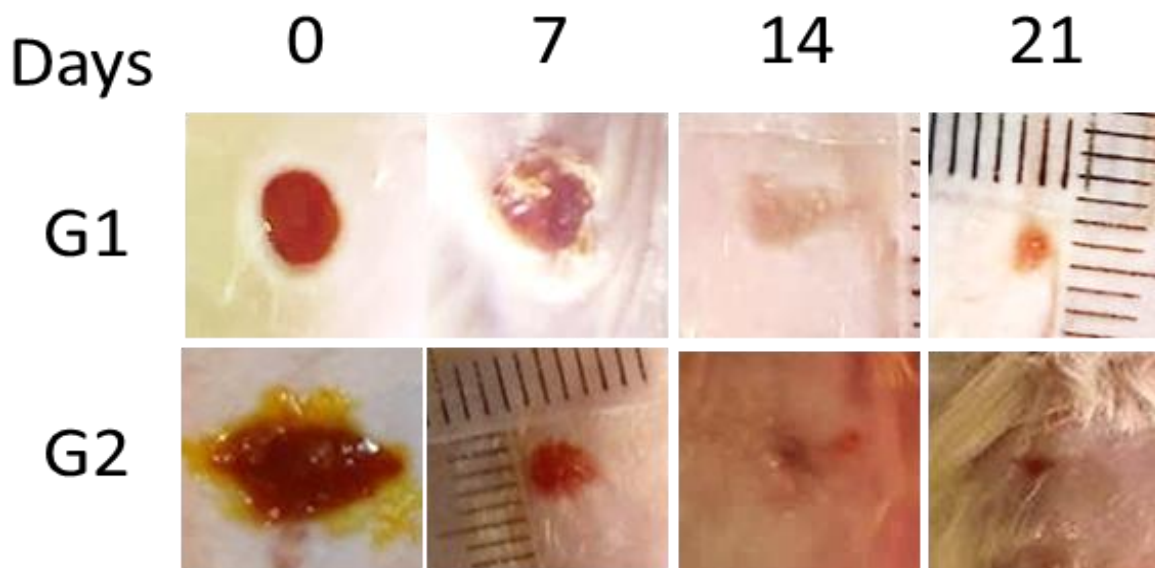


Fig. (1): Gross photographs of control (G1), and treated (G2) illustrate the open 5 mm circular full-thickness skin wounds of mice in various phases of wound healing at 7, 14, and 21 days. On day 0 in both groups see the sharp edges of the circular wounds. On 7th day the wounds were covered with scab, also there was more reduction in size than the 0 day in treated group (G2) than the control (G1). At 14th day G2 show significant decrease in size in compare with control group,



complete epithelialization was occur, more scar tissue. At 21st day more reduction in wound size in the treated group in compare with control. Complete epithelialization was occurring, and less scar tissue was seen.

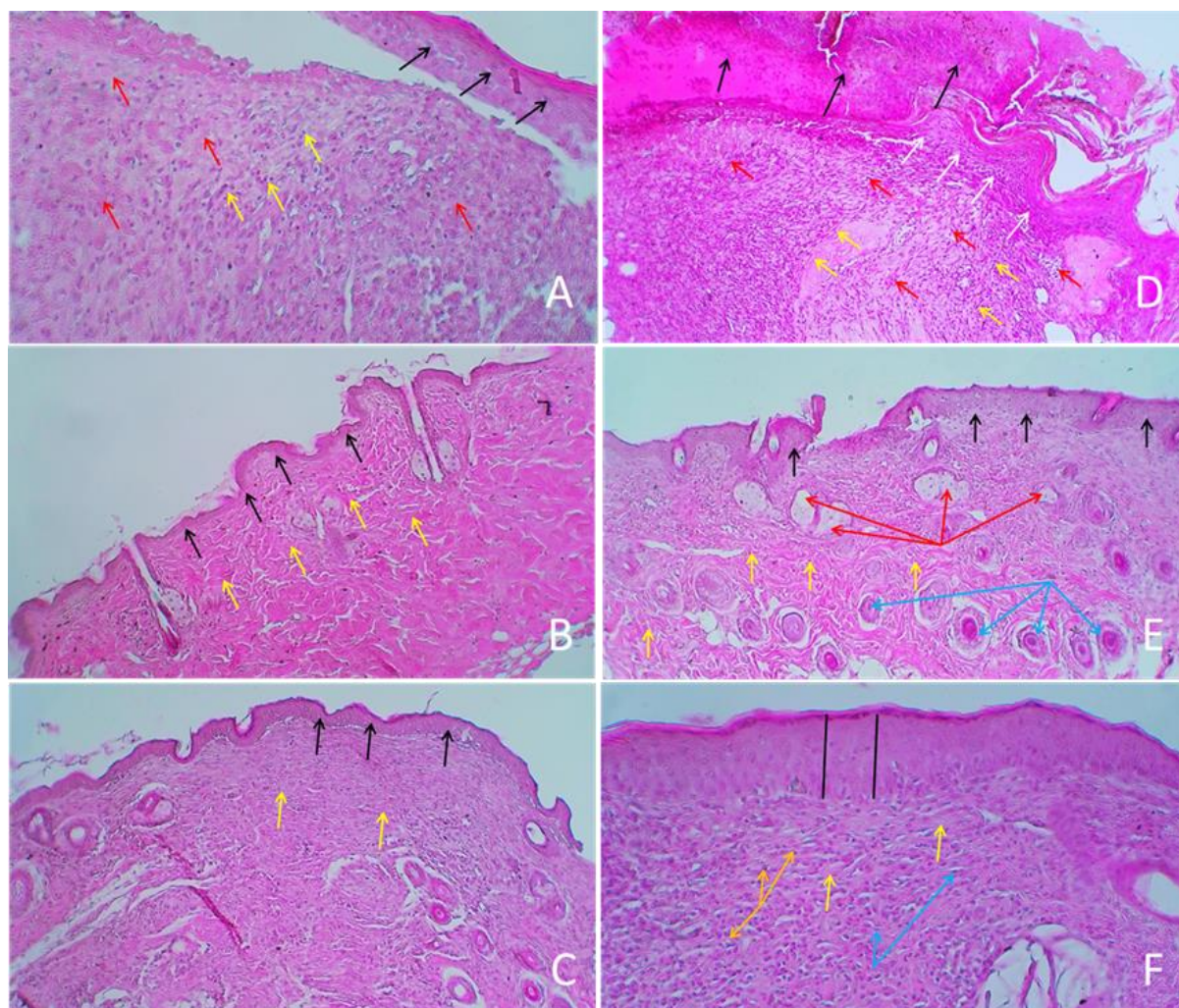


Fig. (2): (A) Untreated wound 7 days PW demonstrate thin de-attached epidermis (black arrows), more inflammatory cells (yellow arrows) and collagen fibers (red arrows). H&E 20X. (B): Untreated wound 14 days PW show thin regeneration of epidermis (black arrows), more wrinkled uneven immature collagen fibers arranged in multidirectional in the dermis (yellow arrows), also there was less inflammatory cells. H&E 10X. (C): Untreated wound 21 days PW show thin regeneration of epidermis (black arrows). The dermis compose of multi-oriented irregular immature granulation tissue representing by irregular bundles of immature collagen fibers (yellow arrows). H&E 10X. (D): Treated wound 7 days PW show thick scab (black arrow) upon regeneration and thickening of epidermis (white arrows) starting from the periphery of the wound, hyper celluler of inflammatory cells (red arrows) and fibroblasts (yellow arrows) in the dermis. H&E 10X. (E): Treated wound 14 days PW show thick well differentiated four epidermal layers (black arrows). The dermis compose from dense even mature collagen fibers (yellow arrows). Plenty hair follicles (blue arrows), and sebaceous glands (red arrows) were seen. H&E 10X. (F):



Treated wound 21 days PW show normal traditional appearance of the regenerated epidermis (demonstrating ordinary thickness) resting on basement membrane (black line). The collagen fibers (yellow arrows) are evenly arranged in dermis layer with, fibroblasts (blue arrows), and infiltration of inflammatory cells (orange arrows).H&E 20X

Discussion

The purpose of the study was to assess the effectiveness of topical turmeric extract administration and diode laser therapy in treating open skin wounds in mice. Skin wound healing requires a specific set of procedures that are arbitrary divided into three overlapping phases. Edema is the first symptom of phase 1, which lasts for 0–7 days and is characterized by inflammation and resorption. To treat the wound, inflammatory cells (neutrophils, followed by macrophages and lymphocytes), which remove injured cells and foreign objects from the wound, then penetrate the area and release growth factors and biochemical substances that stimulate tissue regeneration. Neovascularization and provisional matrix synthesis (3–14 days) are the hallmarks of phase 2, with new blood vessels primarily arising from tissues near the lesion. The earliest component of the provisional matrix, proteoglycan produced by connective tissue cells, is followed by the production of collagen by activated fibroblasts. Early collagen fibers are much thinner and join parallel to blood vessels (perpendicular to the wound surface). During this time, connective tissue contracts, and rodents in particular show the growth of epidermis over the wound surface. Phase 3 is a remodeling phase of the wound that can continue anywhere from 10 days to 6 months. By resorbing early collagen and producing new collagen fibers that are aligned along stress lines, collagen is reformed during this phase, which also sees the destruction of new blood vessels and a reduction in the proteoglycan matrix (37)(38).

Macroscopically and microscopically finding:

Clinical evaluation of the animals revealed that they were healthy and active throughout the 21-day post-wound (PW) monitoring period, with normal wound healing at the surgical site and no clinical signs of infection, highlighting the significant benefits of the 660-nm laser and turmeric extract ointment therapy. All wound regions swelled and erythematized within 4 hours of being injured, and they continued to swell, erythema, and expand in size for the following 24 hours post-injury (PW), suggesting that the inflammatory phase occurred during this time. These signs show that the healing process and the treatment plan are proceeding successfully. At the seventh day, macroscopic inspection of the treated and untreated G2 wounds revealed shed of scabs in most animals, and the wound had barely shrunk in size, our results are in line with those of (39), who observed that the wound scab had nearly completely disappeared but that some fragments remained at day 4. The epithelial lining thickened while the integrity of the epidermis was maintained. There were still many of fibroblast cells along the wound's edge. Day 7 marked the complete disappearance of the wound's scab and the beginning of the epithelial lining's thinning relative to day 4. When compared to the control wound, the treated wound exhibits greater wound size reduction at 14 days, no scab cover incision, and scar tissue formation. At 21 days, the shape of the incision may occasionally alter to a circular or liner. This is in line with the findings of (40) who bound for the importance of moist environment in optimal wound healing. The ointment in this experiment provide the humid environment for the wound. The histological examination of the skin wounds in G2 at 7 days



PW reveals hyper cellular, well-regenerated epithelial layers hidden under a thick scab. In addition to the accumulation of inflammatory cells and fibroblasts in the dermis, the regenerated epidermis includes the formation and regeneration of various cells of the epidermal layers, such as the regeneration of the stratum corneum, stratum granulosum, stratum spinosum, and stratum basal cells. This is a result of the synergistic effect of laser and curcumin on wound healing. According to earlier research (41), laser therapy causes higher collagen deposition, collagen type I to replace collagen type III earlier in laser-treated animals, and myofibroblasts to proliferate more in experimental cutaneous wounds (41,42). Additionally, it agrees with studies by (43, 44) that showed how curcumin altered collagen formation and cell regeneration to promote wound healing. Curcumin's ability to accelerate wound healing may be due to its antioxidant and free-radical scavenging activities, in accordance with (45). At 14 days, G2 was discovered histologically, followed by thick, well-differentiated epidermal layers that rested on transparent basement membrane. The epidermis is made up of four thick layers, including a thick layer of keratin. Large and highly chromic cells were seen. Dense, even fully developed collagen fibers make up the dermis. There were numerous sebaceous glands and hair follicles, this outcome is consistent with findings of (46, 47, 48) who found a thick mature granulation tissue at day 14 following injury that was characterized by compact collagen parallel to the well-formed full epithelial layer and decreasing numbers of fibroblasts and new blood vessels. At day 21 of G2, a histological investigation revealed that the regenerated epidermis, which was resting on the basement membrane and displaying normal thickness, had numerous inner invaginations pointing toward the dermis. Under the newly formed epidermis, in the dermis layer, collagen fibers are uniformly distributed along with fibroblasts,

inflammatory cells, and many hair follicles in various stages of development. These findings show that the four stages of healing were finished on day 21, providing unequivocal proof of the beneficial synergy between the use of laser and curcumin in treating wounds. Additionally, these findings demonstrate the significant antibacterial and anti-inflammatory properties of curcumin extract, and it is advised that further research be done to confirm the efficacy of curcumin in the healing of wounds. Additionally, the laser therapy increased the amount of collagen deposited, which improved cell modulation and differentiation in the wound region. Thus, throughout the epidermal healing process, laser photobiomodulation was able to effect a number of alterations, favoring newly generated collagen fibers to be more ordered and compactly distributed in particular (33). By day 21 following the injury, however, the distinction between the control and treated groups was less pronounced. This result was taken into consideration by (33) since collagen tissue replacement from all groups displayed a similar level of advanced maturation. According to (49), topical medicines are more effective at stimulating wound contraction and healing because they are more readily available at the wound site. The study's findings demonstrated a definite improvement in healing in the experimental groups as compared to the control groups while using turmeric ointment 20% and a combination of turmeric ointment 20% plus diode laser treatment 8J/cm². Mean values of inflammatory cells were higher in the treated group than in the control groups, but they gradually decreased over the course of the four healing intervals, showing that curcumin treatment accelerated the inflammatory response.

Conclusion

Using of diode laser, in combination with 20% turmeric extract ointment has a synergistic beneficial effect on the healing of open skin wound in mice.



Conflict of interest

The study has no conflict of interest

References

- McGee HM, Schmidt BA, Booth CJ, Yancopoulos GD, Valenzuela DM, Murphy AJ, et al. IL-22 promotes fibroblast-mediated wound repair in the skin. *J Invest Dermatol.* 2012;463:1000-1038.
- Rodero MP, Khosrotehrani K. Skin wound healing modulation by macrophage. *J Inter Clin Exp Pathol.* 2010;3:643-653.
- Swaim SF, Henderson JRRA. *Small Animal Wound Management*. 2nd ed. Williams and Wilkins; 1997. p. 27-29. <https://doi.org/10.1111/j.1532-950X.1998.tb00113.x>
- Li J, Chen J, Kirsner R. Pathophysiology of acute wound healing. *J Clin Dermatol.* 2007;25:9-18. <https://doi.org/10.1016/j.clindermatol.2006.09.007>
- Digelmann RF, Evans MC. An overview of acute fibrotic and delayed. *J Front Bio Sci.* 2004;9:283-289. <https://doi.org/10.2741/1184>
- Strodtbeck F. Physiology of wound healing. *J Newborn Infant Nurs Rev.* 2001;1:43-52. <https://doi.org/10.1053/nbin.2001.23176>
- Alam G, Singh MP, Singh A. Wound healing potential of some medicinal plants. *J Inter Pharm Sci Rev Res.* 2011;9:136-145.
- Stadelmann WK, Digenis A, Tobin G. Impediments to wound healing. *J Am Surg.* 1998;176:39-47. [https://doi.org/10.1016/S0002-9610\(98\)00184-6](https://doi.org/10.1016/S0002-9610(98)00184-6)
- Kumar V, Cortran R, Robbins S, editors. *Basic pathology*. 7th ed. Saunders; 2003. p. 873-891.
- Li B, Wang J. Fibroblast and myofibroblasts in wound healing: force generation and measurement. *J Tissue Viability.* 2011;20:108-120. <https://doi.org/10.1016/j.jtv.2009.11.004>
- Hawkins D, Abrahamse H. Effect of multiple exposure of low-level laser therapy on the cellular responses of wounded human skin fibroblasts. *J Photomed Laser Surg.* 2006;24:705-714. <https://doi.org/10.1089/pho.2006.24.705>
- Diwan MF, Abid TA. The effect of different doses of 660 nm laser therapy on open skin wound healing in Wistar rats. *Kufa J Vet Med Sci.* 2016;7:130-137. <https://doi.org/10.36326/kjvs/2016/v7i24340>
- Ihasn FR. Low-level laser therapy accelerates collateral circulation and enhances microcirculation. *J Photomed Laser Surg.* 2005;23:289-294. <https://doi.org/10.1089/pho.2005.23.289>
- Gal P, Vidinsky B, Toporcer T, Mokry M, Mozes T, Longauer F, et al. Histological assessment of the effect of laser irradiation on skin wound healing in rats. *Photomed Laser Surg.* 2006;24:480-488. <https://doi.org/10.1089/pho.2006.24.480>
- Bjorndal JM, Johanson ML, Iversen V, Aimbire F, Lopes-martins RA. Low-level laser therapy in acute pain: a systematic review of possible mechanisms of action and clinical effects in randomized placebo-controlled trials. *J Photomed Laser Surg.* 2006;24:158-167. <https://doi.org/10.1089/pho.2006.24.158>
- Araujo CE, Ribeiro S, Favaro R, Zezell DM, Zorn TM. Ultra-structural and autoradiographical analysis show a faster skin repair in HeNe laser-treated wound. *J Photochem Photobiol B.* 2007;86:87-96. <https://doi.org/10.1016/j.jphotobiol.2006.08.006>
- Nguyen DT, Orgill DP, Murphy GT. The pathophysiologic basis for wound healing and cutaneous regeneration. In: Orgill DP, Blanco C, editors. *Biomaterials for Treating Skin Loss*. Elsevier; 2009. p. 25-57. <https://doi.org/10.1533/9781845695545.1.25>
- Thangapazham RL, Sharma A, Maheshwari RK. Beneficial role of curcumin in skin diseases. *Adv Exp Med Biol.* 2007;595:343-357. https://doi.org/10.1007/978-0-387-46401-5_15
- Gong C, Wu Q, Wang Y, Zhang D, Luo F, Zhao X, et al. A biodegradable hydrogel system containing curcumin encapsulated in micelles for cutaneous wound healing. *Biomaterials.* 2013;34:6377-6387. <https://doi.org/10.1016/j.biomaterials.2013.05.005>
- Campos AC, Groth AK, Branco AB. Assessment and nutritional aspects of wound healing. *Curr Opin Clin Nutr Metab Care.* 2008;11(3):281-284. <https://doi.org/10.1097/MCO.0b013e3282fbd35a>
- Urosevic M, Nikolic L, Gajic I, Nikolic V, Dinic A, Miljkovic V. Curcumin: Biological activities and modern pharmaceutical forms. *Antibiotics (Basel).* 2022;11(2):135. <https://doi.org/10.3390/antibiotics11020135>
- Hawkins D, Abrahamse H. Effect of multiple exposure of low-level laser therapy on the cellular responses of wounded human skin fibroblasts. *J Photomed Laser Surg.* 2006;24:705-714. <https://doi.org/10.1089/pho.2006.24.705>
- Patil SS, Bhasarkar S, Rathod VK. Extraction of curcuminoids from *Curcuma longa*: comparative study between batch extraction and novel three-phase partitioning. *Prep Biochem Biotechnol.*



- 2019;49(4):407-418.<https://doi.org/10.1080/10826068.2019.1575859>
24. Chhetri HP, Yogol NS, Sherchan J, Anupa KC, Mansoor S, Thapa P. Formulation and evaluation of antimicrobial herbal ointment. *Kathmandu Univ J Sci Eng Technol.* 2010;6(1):102-107.<https://doi.org/10.3126/kuset.v6i1.3317>
 25. Sharma S, Singh SP. Dermatological preparations, formulation, and evaluation of various semi-solid dosage forms. *Asian J Pharm Res Dev.* 2014;10:25.
 26. Marriott JF, Wilson KA, Langley CA, Belcher D. *Pharmaceutical Compounding and Dispensing.* 2nd ed. Pharmaceutical Press; 2010. p. 163.
 27. Lane ME. Ointments, pastes, gels, cutaneous patches, and topical sprays. In: Taylor KM, Aulton ME, editors. *Aulton's Pharmaceutics E-Book: The Design and Manufacture of Medicines.* 6th ed. Elsevier Health Sciences; 2022. p. 453-462.
 28. d'Acampora AJ, Vieira DS, Silva MT, Farias DC, Tramonte R. Morphological analysis of three wound-cleaning processes on potentially contaminated wounds in rats. *Acta Cir Bras.* 2006;21:332-340.<https://doi.org/10.1590/S0102-86502006000500011>
 29. Sardari K, Dehgan MM, Mohri M, Emami MR, Mirshahi A, Maleki M, et al. Macroscopic aspects of wound healing (contraction and epithelialization) after topical administration of allicin in dogs. *Comp Clin Pathol.* 2006;15(4):231-235.<https://doi.org/10.1007/s00580-006-0634-2>
 30. Patil MV, Kandhare AD, Bhise SD. Pharmacological evaluation of ethanolic extract of *Daucus carota* Linn root formulated cream on wound healing using excision and incision wound model. *Asian Pac J Trop Biomed.* 2012;2(2):S646-S655.[https://doi.org/10.1016/S2221-1691\(12\)60290-1](https://doi.org/10.1016/S2221-1691(12)60290-1)
 31. Weinberg SL, Abramowitz SK. *Statistics using SPSS: An integrative approach.* Cambridge University Press; 2008.
 32. Luna IG. *Manual of Histology Staining Methods of the Armed Forces Institute & Pathology.* 3rd ed. McGraw-Hill; 1968. p. 34-215.
 33. Estevao LD, Vieira P, Leite AGB, Bulhoes AV, Barcelos LS, Neto J. Morphological evaluation of wound healing events in the excisional wound healing model in rats. *Bio-protocol.* 2019;9(13):e3285.<https://doi.org/10.21769/BioProto.c.3285>
 34. Gal P, Kilik R, Mokry M, et al. Simple method of open skin wound healing model in corticosteroid-treated and diabetic rats: standardization of semi-quantitative and quantitative histological assessments. *Vet Med (Praha).* 2008;53:652-659.<https://doi.org/10.17221/1973-VETMED>
 35. Dancáková L, Vasilenko T, Kováč I, Jakubčová K, Holý M, Revajová V, et al. Low-level laser therapy with 810 nm wavelength improves skin wound healing in rats with streptozotocin-induced diabetes. *Photomed Laser Surg.* 2014;32(4):198-204.<https://doi.org/10.1089/pho.2013.3586>
 36. Gupta A, Kumar P. Assessment of the histological state of the healing wound. *Plast Aesthet Res.* 2015;2:239-242.<https://doi.org/10.4103/2347-9264.158862>
 37. Cañedo-Dorantes L, Cañedo-Ayala M. Skin acute wound healing: a comprehensive review. *Int J Inflamm.* 2019;2019:1-15.<https://doi.org/10.1155/2019/3706315>
 38. Wilkinson HN, Hardman MJ. Wound healing: Cellular mechanisms and pathological outcomes. *Biol. Open.* 2020;10(9):200223.<https://doi.org/10.1098/rsob.200223>
 39. Topaloglu N, Güney M, Yuksel S, Gülsoy M. Antibacterial photodynamic therapy with 808-nm laser and indocyanine green on abrasion wound models. *J Biomed Opt.* 2015;20(2):028003.<https://doi.org/10.1117/1.JBO.20.2.028003>
 40. Atiyeh BS, Ioannovich J, Al-Amm CA, El-Musa KA. Management of acute and chronic open wounds: the importance of a moist environment in optimal wound healing. *Curr Pharm Biotechnol.* 2002;3(3):179-195.<https://doi.org/10.2174/1389201023378283>
 41. Medrado AP, Soares AP, Santos ET, Reis SRA, Andrade ZA. Influence of laser photobiomodulation upon connective tissue remodeling during wound healing. *J Photochem Photobiol B.* 2008;92(3):144-152.<https://doi.org/10.1016/j.jphotobiol.2008.05.008>
 42. Wardlaw JL, Gazzola KM, Wagoner A, Brinkman E, Burt J, Butler R, et al. Laser therapy for incision healing in 9 dogs. *Front Vet Sci.* 2019;5:349.<https://doi.org/10.3389/fvets.2018.00349>
 43. Mani H, Sidhu GS, Kumari R, Gaddipati JP, Seth P, Maheshwari RK. Curcumin differentially regulates TGF- β 1, its receptors, and nitric oxide synthase during impaired wound healing. *Biofactors.* 2002;16(1-2):29-43.<https://doi.org/10.1002/biof.5520160104>
 44. Akbik D, Ghadiri M, Chrzanowski W, Rohanizadeh R. Curcumin as a wound healing agent. *Life Sci.* 2014;116(1):1-7.<https://doi.org/10.1016/j.lfs.2014.08.016>
 45. Asouri M, Ataee R, Ahmadi AA, Amini A, Moshaei MR. Antioxidant and free radical scavenging activities of curcumin. *Asian J Chem.* 2013;25(13):7593-7595.<https://doi.org/10.14233/ajchem.2013.15308>



46. Kulac M, Aktas C, Tulubas F, Uygur R, Kanter M, Erboga M, et al. The effects of topical treatment with curcumin on burn wound healing in rats. *J Mol Histol.* 2013;44(1):83-90.
<https://doi.org/10.1007/s10735-012-9452-9>
47. Kant V, Gopal A, Pathak NN, Kumar P, Tandan SK, Kumar D. Antioxidant and anti-inflammatory potential of curcumin accelerated the cutaneous wound healing in streptozotocin-induced diabetic rats. *Int Immunopharmacol.* 2014;20(2):322-330.
<https://doi.org/10.1016/j.intimp.2014.03.009>
48. Prasad R, Kumar D, Kant V, Tandan SK, Kumar D. Curcumin enhanced cutaneous wound healing by modulating cytokines and transforming growth factor in excision wound model in rats. *Int J Curr Microbiol Appl Sci.* 2017;6:2263-2273.
<https://doi.org/10.20546/ijcmas.2017.607.266>
49. Panchatcharam M, Miriyala S, Gayathri VS, Suguna L. Curcumin improves wound healing by modulating collagen and decreasing reactive oxygen species. *Mol Cell Biochem.* 2006;290(1-2):87-96.
<https://doi.org/10.1007/s11010-006-9170-2>