

Macroanatomical and histological study of kidney in porcupine (*Hystrix cristate*)

Abdularazzaq baqer kadhim

Coll. of Vet. Med./Univ. of Al-Qadisiyah

Email: abdulrazzaq.alrabei@qu.edu.iq

(Received 24/5/2017, Accepted 1/8/2017)

Abstract

Involve this research grossly and histological study of the kidney of porcupine *hystrix cristate*. The study was achieved on ten kidneys from five adult (male and female porcupine (*hystrix cristate*)). They were cautiously dissected and introspect after used the chloroform for anesthesia directly. The macroanatomical studies established the two kidneys of porcupine. the kidneys are located in retroperitoneal region in the posterior part of the abdomen on each side of the lumbar vertebra. The renal papilla are consider end the outer cortex and inner medulla together as show after anatomical distinct regions of kidney. The indicate width of cortex and medulla of right kidney (5.500 ± 0.371) mm, (5.588 ± 0.180) mm respectively while the indicate width of cortex and medulla of left kidney (5.780 ± 1.792) mm, (5.492 ± 0.205) mm. There is no obvious border between the cortex and medulla. The renal corpuscle is sphere-shaped created of glomerulus, which is consist of Bowman's capsule. Proximal complicated thin tubules carctrestic by have widest lumen and internally inside layer by epithelial cells are cuboidal which latent on the basal membrane. This cells described by have ground eosinophile cytoplasm, big center nuclei and the apical surface covered microvilli. as the epithelial lining of low volute tubules have widespread lumen and cuboidal cells have ground cytoplasm was visibly fewer eosinophilic campier that of the upper tubules and the apical surface of the distal complicated tubule was discovered by short microvilli.

Key words: porcupine, *hystrix crestate* ,kidney, cortex ,medulla

Introduction:

Porcupines are rodentian mammals with a blazer of sharp prickles that protect against devourers. The word covers two families, 'the Old World porcupines of family Hystricidae, and the New World porcupines of family Erethizontidae'. As mentionable, both families accustomedness the clade 'Hystricognathi' within the deeply varied order Rodentia and show apparently similar blazer of quills despite this, the two groups are separate from each other and are not intimately related to each other inside Hystricognathi. The Old World porcupines live in southern Europe, Asia, and most of Africa. They are large, earthly, and severely night-time. In taxonomic conditions, they appearance the family Hystricidae. Hystricidae. The North African crested porcupine (*Hystrix cristata*) is the biggest porcupine in the world. The black and white quills the length of the head and back of this spiky mammal can be raised into a crest, hence its common name of crested porcupine (1,2,3). as well as the investigational animals (mouse, rat, guinea pig and monkey) play

vital role for answering many problems in human medicine due to the grossly structure of the kidneys of diverse experimental animals be studied in arrange to understand the anatomically of human kidney (1,2) due to their anatomy and physiology look like with human kidneys (3). The principle function of urinary system is protection liquid and electrolyte homeostasis and the second manger function of this system is the emission of many toxic metabolic waste products chiefly the urea and creatine (4). The kidneys are complex organs take part in important role in elimination of surplus nitrogenous substances, excess water and relation maintenance of osmotic attentiveness of the blood (5,6). The present study be understand morphometric parameters and histology of the normal kidney in porcupine, this help to provide base line information.

Material and Method:

Ten kidneys from five mature (male and female) clinically healthy of (*porcupine*) *hystrix cristate* were collected

from a local hunters in Diwaniyah city. Its weight between 15kg and 20kg. The animals be anaesthetized using chloroform in an inhalation chamber. Excess inhalation anesthetic was administered before each dissection of animals to keep away from spasms and exclusion of glandular products. In this study, left and right kidneys removed from abdomino-sternal approach. The metrical parameters counting (weight, length, width boundary and thickness of both kidneys). The length, width and thickness of the kidneys were deliberate by use digital Vernier calipers. Then the kidneys be

dissected longitudinally to depiction the inner structures later, the thickness of cortex and medulla were predictable with the help of digital Vernier calipers (7). The results were recognized with digital camera HTC. Samples for histology are collected directly after gross examination. The samples were fixed in 10% formalin for about 48 hours. The samples put in 70 in graded sequence of ethyl alcohol, cleared with xylene and embedded in paraffin wax. Sections were cut 4-6 μ thickness, mounted on clean glass slides, and stained with the haematoxylin and Eosin (H &E) for general structure.

Results:

The urinary system of porcupine (*hystrix cristate*) was composed of two kidneys. The kidneys are retroperitoneal organs like bean, red brown in color and positioned in the posterior division of the abdomen on each side of the vertebral column. They are attaching to the posterior edge of the adrenal gland at the escrow side. The right kidney was rostral and craniomedially to the left kidney and the cranial pole of the right kidney had impression of liver on caudal lobe of it. The kidneys together surrounded by a fibro connective smooth capsule and adipose tissue nearby the hilus and sides of each kidney fig (1). Every kidney had cranial, caudal surface medial, lateral border, upper and lower pole. The lateral border was convex in shape at the same time as the medial border was concave fig (2). The mean length, width and thickness of right kidney (20.456 ± 0.850) mm, (14.400 ± 0.830) mm, (8.100 ± 0.450) mm respectively table (1). While the mean length, width and thickness of left kidney (18.300 ± 0.722) mm, (14.394 ± 0.830) mm, (8.194 ± 0.440) mm respectively table (2)". The cross section of kidney appears two anatomical separate regions, the external cortex and internal medulla, together terminate by renal papilla. "The renal cortex is reddish brown in color". The signify width of cortex and medulla of right kidney (5.500 ± 0.371) mm, (5.588 ± 0.180) mm respectively as in table (1) while the mean width of cortex and medulla of left kidney (5.790 ± 1.792) mm, (5.490 ± 0.205) mm correspondingly as in

table (2). "The mean weight of right and left kidney (0.205 ± 1.998) mm. Explanation the kidney consist of external dark red region (cortex) and internal lighter colored region (medulla) there is no plain frontier between the cortex and medulla fig(3). Microscopically the kidney is a composite tubular gland formalized of components of the nephron involve the renal or "Malpighian", the proximal convoluted tubule, the distal convoluted tubule, and the connecting tubule. The renal corpuscle (Malpighian) is a round structure formed of glomerulus, which is enclosed by double walled layers called "Bowman's capsule". Bowman's capsule own two layers visceral and parietal layers fig (5). The inner or visceral layer environs the glomerular capillaries with modified epithelial cells called podocyte. The gap amongst the visceral layer and the parietal layer of the renal corpuscle is called the capsular (urinary) space fig (4). Proximal convoluted tubules is are thin structures carctrestic by have broader lumen and internally lining by cuboidal epithelial cells which relieves on the basement membrane. These cells characterized by own ground eosinophilic cytoplasm, large centrally nuclei and have apical surface enclosed by a brush border called microvilli. "While the epithelial lining of distal convoluted tubules have extensive lumen and cuboidal cells have ground cytoplasm was clearly less eosinophilic than that of the proximal tubules and the apical surface of the distal convoluted tubule was

uncovered by short microvilli". In addition, institute in the cortex are the medullary rays. The medullary rays include the subsequent three types of tubules straight (descending) segments of the proximal tubules, straight (ascending) segments of the distal tubules and the collecting tubules. The straight (descending) of the proximal tubules are much related in the structure to the proximal

convoluted tubules while the straight (ascending) segments of the distal tubules are like to the distal convoluted tubules fig (5). The medulla contains only straight parts of the tubules and Henle loop. Henle loop is the structure consists of (thick and thin descending segments and thin and thick ascending segments as in fig (6).

Table (1): Dimensions of Length, Width, Thickness, Width of Cortex and Medulla of Right Kidney

Kidney length	Kidney width	Kidney thickness	Cortex width	Medulla width
20.456± 0.850 mm	14.400 ±0 .830 Mm	8.200±0.450 mm	5.500±0.371 mm	5.588±0.180 mm

Table (2): Dimensions of length; width; thickness of kidney; width of cortex and medulla of left kidney.

Kidney length	Kidney width	Kidney thickness	Cortex width	Medulla width
18.300± 0.722 mm	14.394 ±0 .830 mm	8.194±0.440 mm	5.790±1.792 mm	5.490±0.205 Mm

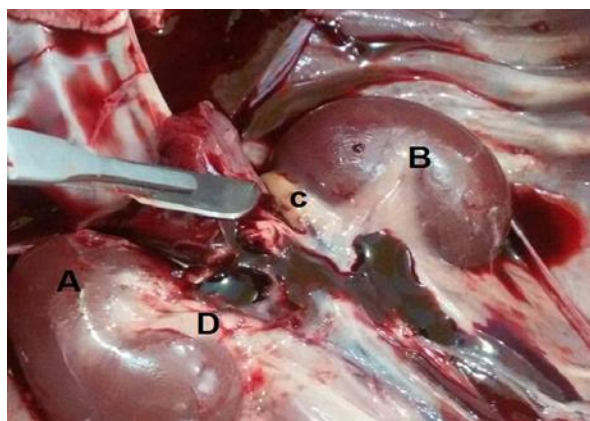


Fig. (1) Section ventral view anatomical position show A-right kidney B-left kidney C- right adrenal gland D-adipose tissue

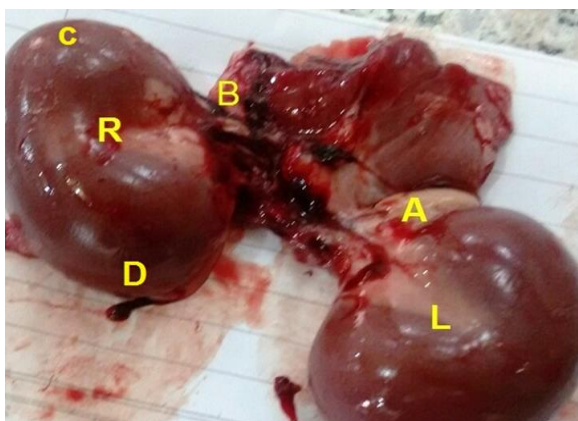


Fig. (2) Section anatomical position, shape and color of kidney show R-Right kidney L- left kidney A-left adrenal gland B-left adrenal gland C-lateral border D-medial border

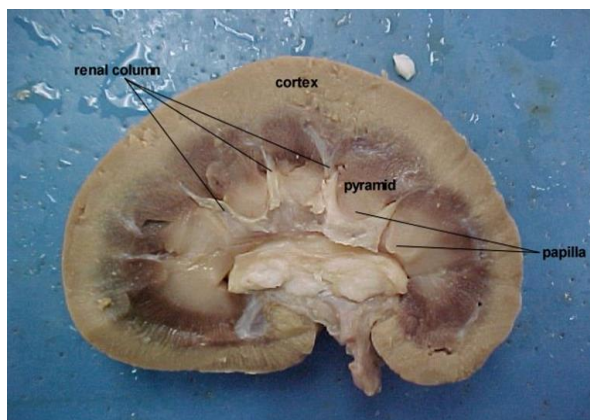


Fig. (3): longitudinal section show cortex, medulla, renal column and papilla

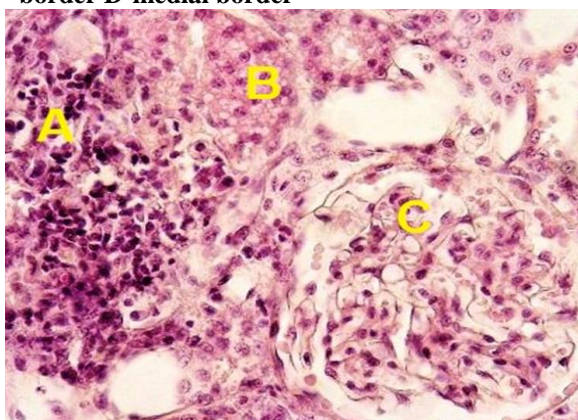


Fig. (4): Transverse section in kidney stain (H&E×100)A-cortex B-medulla C-orpuscle

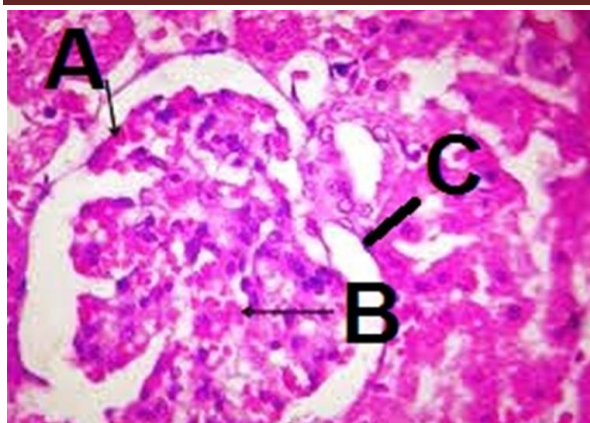


Fig. (5) Transverse section in cortex stain (H&E×400) A-glomerulus B-visceral layer C-parietal layer

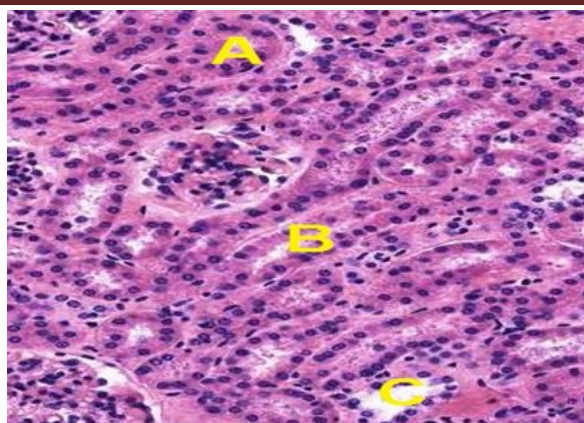


Fig. (6) Transverse section in cortex stain (H&E×400) show A-Straight (descending) B-Straight (ascending) C-collecting tubules D-Henle loop

Discussion:

The anatomical studies show urinary system of porcupine (*hystrix cristate*) was composed of two kidney. "The kidneys are retroperitoneal organs bean in shape situated in the posterior part of the abdomen on each side of the vertebral column". "The present explanation are consistence with that surveillance of (8) in all mammals and (9) in wasteland rodents". The study established the right kidney be rostral and craniomedially to the left kidney, the uneven of the kidneys localization on every side of the vertebral column due to relation difference in growth of dissimilar organs in the abdominal and pelvic cavities during various phases of embryonic development ,that is accord with the (10, 11) in laboratory animal at the same time as disagreed with the (12) who decide localization of the kidneys in rabbits correspond on the lumbar vertebrae and unlike with the (13) who presented removal of the kidneys dependent of the level of artery vessel because not use artery vessel marker for the determine disposal of the kidneys ."Also the results of this study showed slight difference between measurements of right and left kidney, these differences in values could be due to variations in age, breed and environmental factors including the diets". "The values in

this study were also similar to those of (14) in laboratory rat". "Histologic study declares the typical kidney is subdivided into external darker staining cortex and internal lighter staining medulla. "The cortex contains distal, proximal convoluted tubule; glomerulus and medullary rays". The attendance and development of this configuration in large number in the cortex of kidney depend to functional renal disorders, species, gender and aging. "This result confirmed the studies of (15) in normal rats and (16) in wistar rats". Proximal convoluted skinny tubules characteristic by contain widest lumen and internally inside layer by cuboidal epithelial cells which enclosed by a brush border at the same time as the apical surface of the distal convoluted tubule be uncovered by short microvilli .That is agreement with the (17) in rat. Presence of brush border appreciably increases the surface area of the cell of the proximal convoluted tubule and therefore permits the high rates of trans epithelial transport. In addition, brush border microvilli play a mechanosensory function in which fluid dynamic torque is transmitted to the actin cytoskeleton and modulates " Na+" absorption in proximal tubules. "Similar observations are found by (18,19)".

References:

- 1-Fourman J, Moffat D. The blood vessels of the kidney; (1971). Oxford Blackwell Scientific Publication
- 2-Horacek MJ, Earle AM, Gilmore JP. The renal vascular system of the monkey: a gross anatomical description. Journal of Anatomy.(1987); 153:123-137.

- 3-Mc Dougall EM, Clayman RV, Chandhoke PS. Laparoscopic partial nephrectomy in the pig model. *J. Urol.* (1993); 149: 1633-1636.
- 4-Ojeda JL, Icardo JM, Domezain A. Introduction to Fishes. *Acipenseriformes*, 1: 285-293. Renal corpuscle of the sturgeon kidney: an ultrastructural, chemical dissection and lectin binding study. *The Anatomical Record. Pt.A.*, (2003);272: 563-573.
- 5-Ritchison G. Avian osmoregulation. Urinary system, salt glands and osmoregulation. *J. Exp. Biol.*, (2008); 554:17-31.
- 6-Salehi E, Morovati MS. Kidney Morphogenesis during Prenatal Development in Camelus dromedaries Embryoes. *J. Anim. Vet. Adv.*, (2012); 1(6), 822-825
- 7-Kamal S, Bilal A. Morphogenesis of Kidney in Crossbred Pig (*Sus scrofa*) Foetii. *Egypt. J. Morphol.* (2007);25 (1):129-132.
- 8-Young ZJ. *The Life of Mammals; Their anatomy and Physiology*, second edition, clarendon press, (1975); Oxford
- 9-El-salkh BA, Zaki ZK, Basuony MI, Khidr HA. Anatomical, Histological and histochemical studies on some organs of true desert rodents in the Egyptian habitats. *Egyptian Journal of Hospital Medicine Vol.*, 33(2008); 578- 306
- 10-Barone R, Chapitre V. *Anatomie comparée des mammifères domestiques*. (2001). *Splanchnologie*
- 11-Tome quatrièmeTroisième. Renal Doppler ultrasound examination of. Vigot, Paris, pp. 843-859 edition, Editions Vigot, Paris, (2004); pp.843-859.
- 12-Brewer N. Biology of rabbit. *Journal of the American Association for Laboratory animal Science*, (2006); 45: 8-24, 2006.
- 13-Hristov H, Kostov D, Vladova D. Topographical anatomy of some organs in rabbits. *Trakia Journal of Sciences*, (2006); 4: 7-10. abdominal
- 14-Yokota E, Kawashima T, Oncubo F, Sasaki H. Comparative anatomical study of the kidney position in amniotes using the origin of the renal artery as a landmark. *Okajimas Folia Anatomica Japonica*, (2005);81:135-142.
- 15-Hebel R, Stromberg MW. *Anatomy of the laboratory rat*. Williams and Wilkins Company, Baltimore, (1976); pp: 62-65.
- 16-Bertram JF, Soosaipillai MC, Ricardo SD, Ryan GB. Total numbers of glomeruli and individual glomerular cell types in the normal rat kidney. *Cell Tissue Res*; (1992); 270: 37-45.
- 17-Eze KN. The reno-protective effects of coconut water on the kidneys of diabetic wistar rats. *Journal of Health Sciences*, (2012); 2(1): 1-4
- 18-El-gammal AR, Ibrahim Oy, shaban SF, Dessouky AA. Postnatal development of the albino rat renal cortex (histological study) *Egypt. J. Histol. Vol.* 33, No. 4, Dec. (2010); 745-756.
- 19-Eurell JA, Frappier Bl. *Dellmanns Text book of veterinary histology* Black well publishing sixth Edition, (2006); Ames,usa.
- 20-Du Z, Duan Y, Yan O, Wein stein A M, Weinbaum S, Wang T. Mech-anosensory function of microvilli of the kidney proximal tubule. *PNAS*, (2004);101:13068-13073