

Study the effect of the omental pedicle flap in sciatic nerve healing

B. K. Khashjoori

Coll. of Vet. Med. Unive.of Basrah

E mail :bassim_ka@yahoo.com

Abstract

This study was done to observe the effect of omental pedicle flap in neuroraphies , sciatic nerve of 8 dogs which divided into equal two groups .The neuroraphy was performed, after that greater omentum was prepared by median laporotomy which later pass through a tunnel formed in the inguinal region by preserving its vascular supply and adapted then wrapped around the zone of neuroraphy in treated group.asciatic nerves of control group were severed and primary neuroraphy was done without applying omental flap. The histological examination of the biopsy specimens was done in the 60th day for both groups. The amount of regenerated axons and intra neural connective tissue in two groups were examined. In the revascularized neuroraphies by omental flap, there was a significant increase the number of regenerated nerve fibres and reduced perineural fibrosis when compared with control group.

Introduction

A great deal of experimental and clinical studies have been carried out in the restoration of complex function of peripheral nerve for many years.The first primary neuroraphy was reported by Ionly and Hashimoto in 1917 on the other hand, first attempt of neural grafting were mentioned by (1) .Sunderland has studied the nerve vascularisation in 1945 and has observed that he reported vascular supply to peripheral nerve was segmental. Furthermore, he reported the vascular passing through thin membrane on connective and thus he was the first to define the mesoneurium (2).The effect of omental wrapping on nerve graft regeneration and observed higher count of axons in the cases where the nerve graft was wrapped with omentum were mentioned by (1,2). Omentum play a central role in peritoneal defence by adhering to sites of inflammation and providing leukocytes for local immune response (3). The first attempt for using omentum in grafting was done by Jobert and Lambelle in 1826. While Ranvier 1980

had described omentum and defined its milk spots as a mesenchyma cells clusters –like which has high immuno active due to its content of macrophages , histocytes and mast cells that made omentum highly effected in wound healing and also on 1972 there was an attempt of transport of omental pedical flap from abdomen to the neck to treat avulsion wound in the head were mentioned by (4).While it was shown that higher blood vessels population as well as a good orientation of the regenerated nerve fibres homogenization of nervous tissue and proliferation of blood vessels when he wrapped infected sciatic nerve by omentum (5).Other researchers were observed that milk spots contain fenestrated blood vessels ,So omentum used to treat chronic lymph oedema depending on absorption mechanism by transport omental flap to the effected extremities (6 and 7). In the present study we wrapped omental pedicle flap on the sciatic nerve to investigate the effectiveness of the omentum on sciatic nerve regeneration.

Materials and methods

As experimental animals , 8 healthy dogs of local breed from different sexes and races weight between (10-15) Kg were used , and reared in separated cages ,then divided into two equal groups as control and treated respectively.The operations were made under sterilized surgical

environment , mixture of ketamine 15 mg / kg and xylazine 5 mg / kg was injected after 10 minutes of atropine sulfate 0.03 mg / kg I / M injection to prepare the dogs for surgery. With vertical incision on the lateral femoral area of hind limbs ,the sciatic nerve was reached

transmuscularly(fig 1). The nerve was freed 5-7 cm ,then severed in the middle . primary neuroraphy was performed by epineural technique and using(0-3) nylon suture material, then grater omentum was prepared by median laporotomy which was passed through a tunnel arranged in the inguinal region (fig 2,3) by preserving its vascular supply and adapted around the zone of neuroraphy site. while in control group the same procedure was done but without

applying the omental flap . After surgical operations were done each dog was injected by systemic antibiotic of procaine penicillin and streptomycin 15000 I. U. /kg and 5 mg /kg respectively for 4 days. Then the animals reoperated for obtaining biopsies from distal and proximal ends of the neuroraphies .the procedures were performed for each group separately at 60th day.

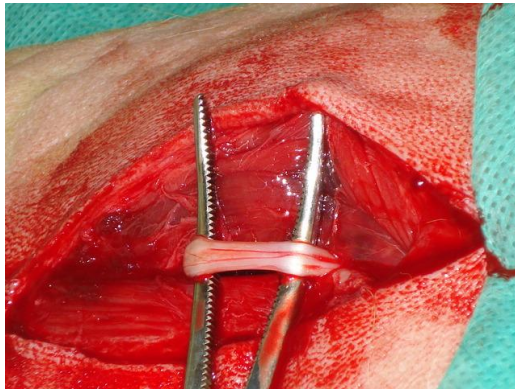


Figure (1)show Sciatic nerve of adult dog

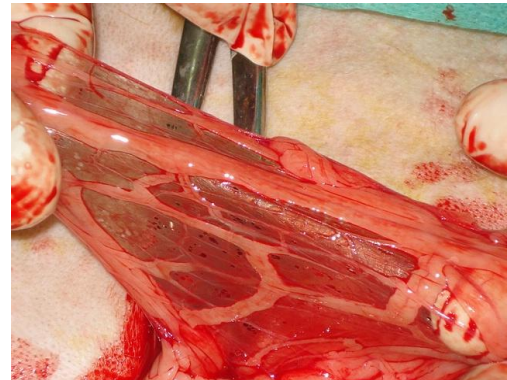


figure (2) show the omentum of adult dog

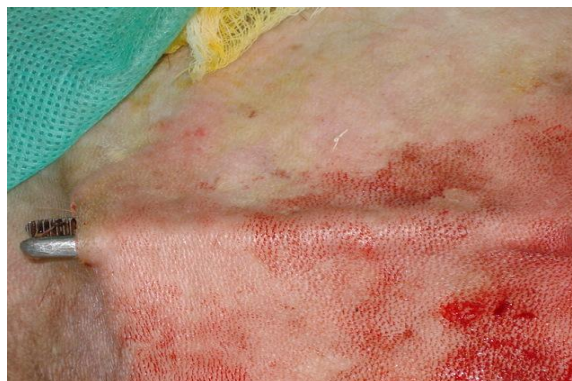

Figure (3) show the induced tunnel in the inguinal region

Results

Clinical signs

Table:1 –show the main clinical signs

Week	Movement		Knuckling	
	Control	Treated	Control	Treated
1 st	Recumbency then try to stand up with ataxia at the 1 st tow days then they began stand up at the other days		+	+
2 nd			+	+
3 rd	Standing up		+	+
4 th	Standing up		+	±
5 th	Standing up		+	±
6 th	Standing up		+	±
7 th	Standing up		+	±
8 th	Standing up		+	±

(+) : Knuckling

(-) : Normal

(±) : Knuckling then normal altimetly

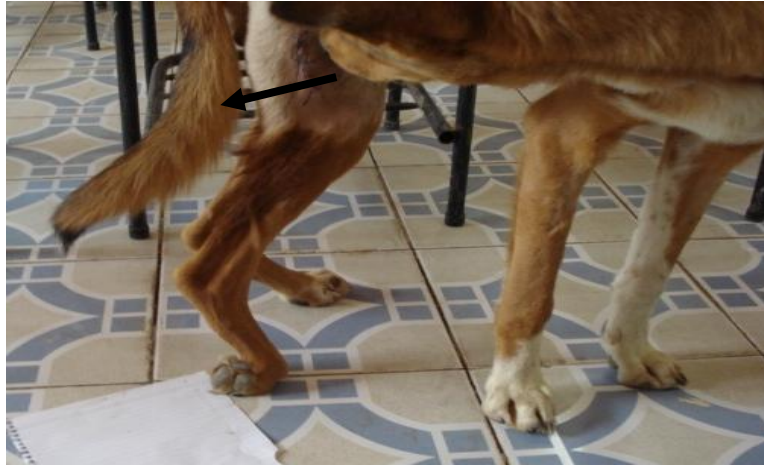

Fig. 4: show the knuckling of the foot

The post-operative evaluations were made according to clinical signs and histological parameters. In the control and treatment groups, the main clinical signs were anorexia, recumbency, inability to stand up with ataxia in the first two days and then they tried to walking with knuckling (Fig.4 and table-1) since the mid of the 1st week extend to the 8th week. Accompanied by ulceration of the medial face of the foot but knuckling became appear then disappear ultimately in the treated group since the 4th week to the last of the experiment and also there was a swelling in the site of operation in the treated group.

Histological investigation

The histological exam of the biopsy specimens were carried out to identify the effect of omental revascularization. After transaction of sciatic nerve experimental animal were divided into two groups. The first group with transaction of sciatic nerve only while the second group with transaction of sciatic nerve and wrapping with omental pedicle flap. Both groups transected sciatic nerve were sutured then also complete suturing of the skin, the animal were put under observation for 60

days. The animal were killed and section of the operated transected sciatic nerve from both with or without omentum.

Histopathological examination of the sciatic nerve

group one without omentum showed areas of degenerated / vacuolated nerve fibers (Fig.7,10). In some sections associated with proliferation of fibrous tissue (Fig.6) while the second group of transected sciatic nerve with the omentum, the degeneration and vacuolation of nerve fibers was far less than without omentum. In conclusion it indicated that wrapping of pedicle flap of omentum was with less degenerated vacuolated nerve fibers also associated with regeneration of nerve fibers (Fig.9). In the early phases of regeneration at 60 days post operation, regenerated nerve fibers were present within the omentum guide and regenerated nerve fiber could be confirmed after this period (Fig.11). In these groups with no conduit between the proximal and distal stumps. the specimens were dehydrated through serial alcohols and impeded in paraffin, take slices and stained with H and E stain.

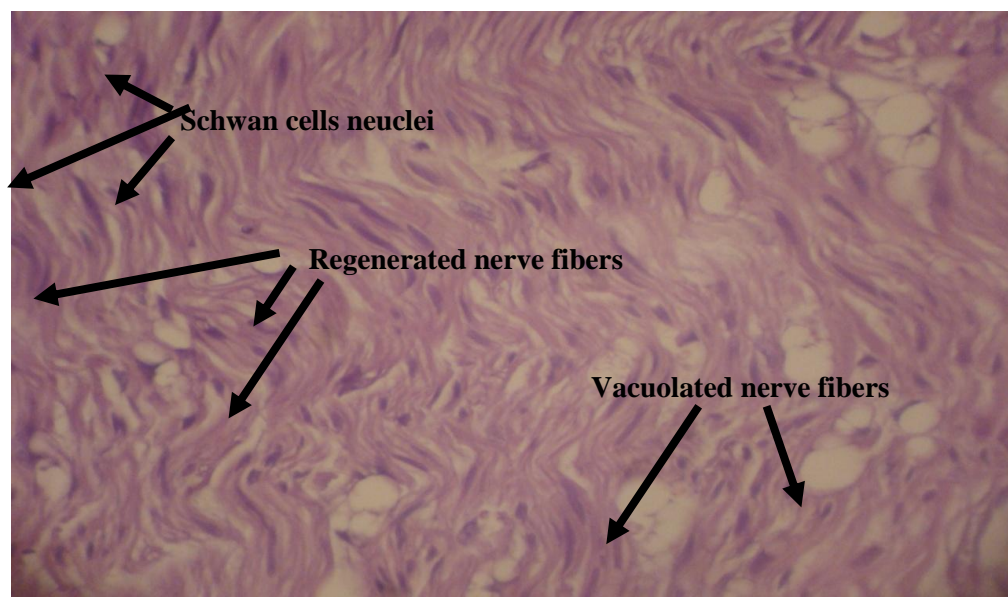


Fig 5 : Section of sciatic nerve after surgical transaction wrapped by pedicle flap of omentum revealed regenerated nerve fibers, increase number of Schwann cells and vacuolated / degenerated nerve fibers (Treated group) X 40

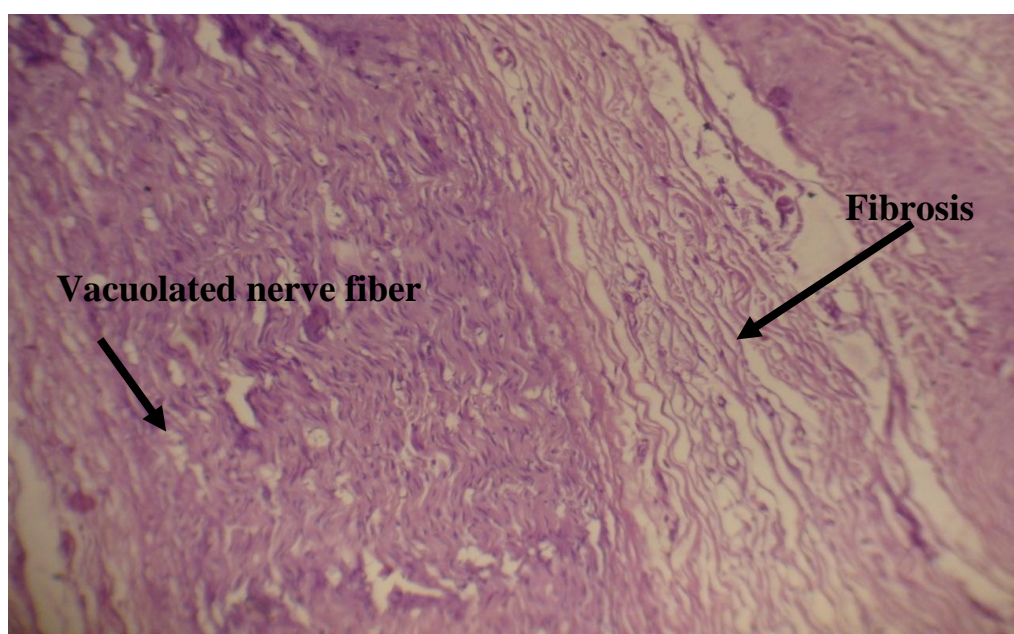

Fig. 6 : Section of sciatic nerve after surgical transaction revealed vacuolated, degenerated nerve fibers nerve and prineural fibrosis (Control group) X 40

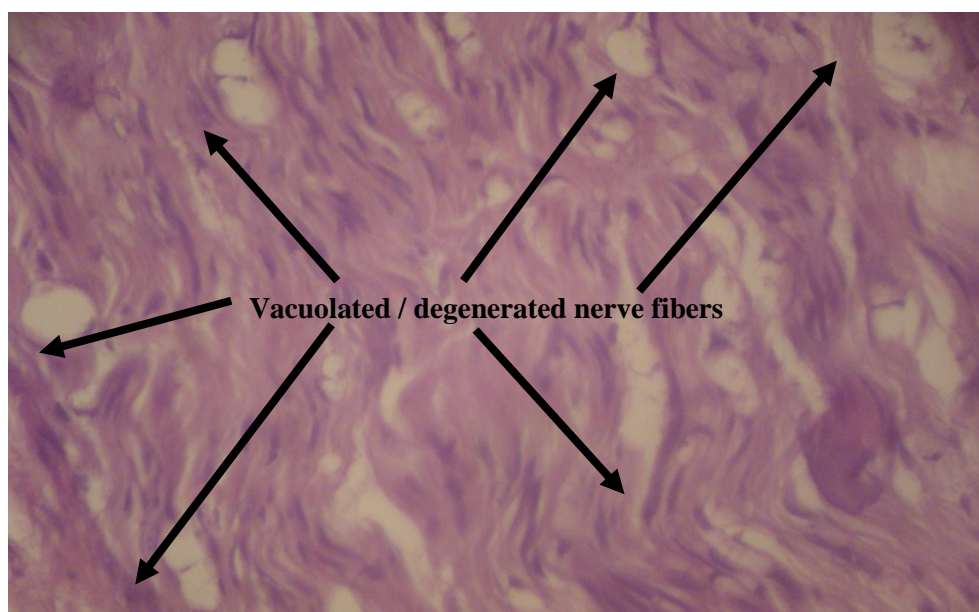


Fig. 7 : Section of sciatic nerve after surgical transaction revealed Vacuolated / degenerated nerve fibers (control group)X40

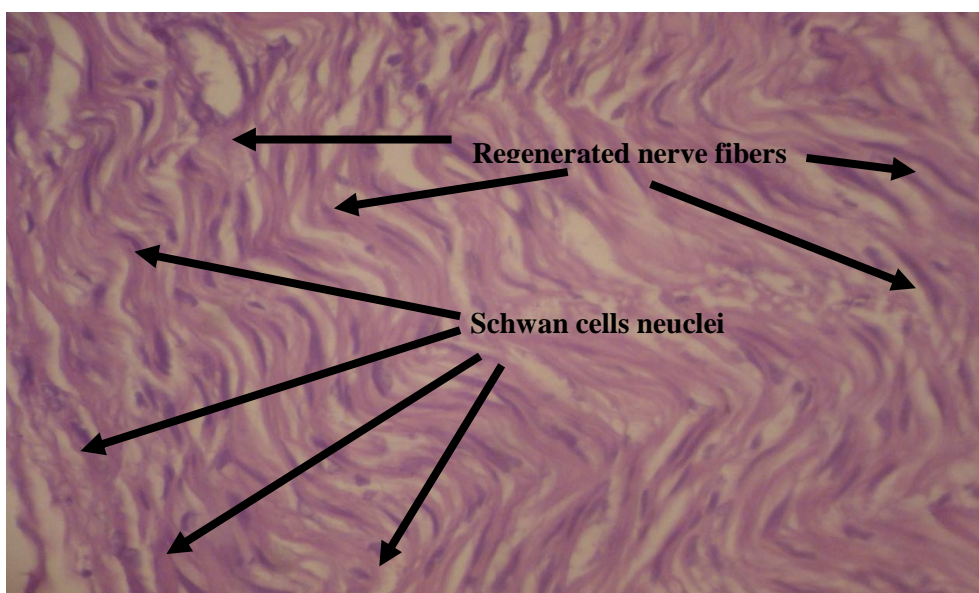


Fig. 8 : Section of sciatic nerve with clear evidence of regenerated nerve fibers and prominent number of schwann cells neuclei (Treated group) X40

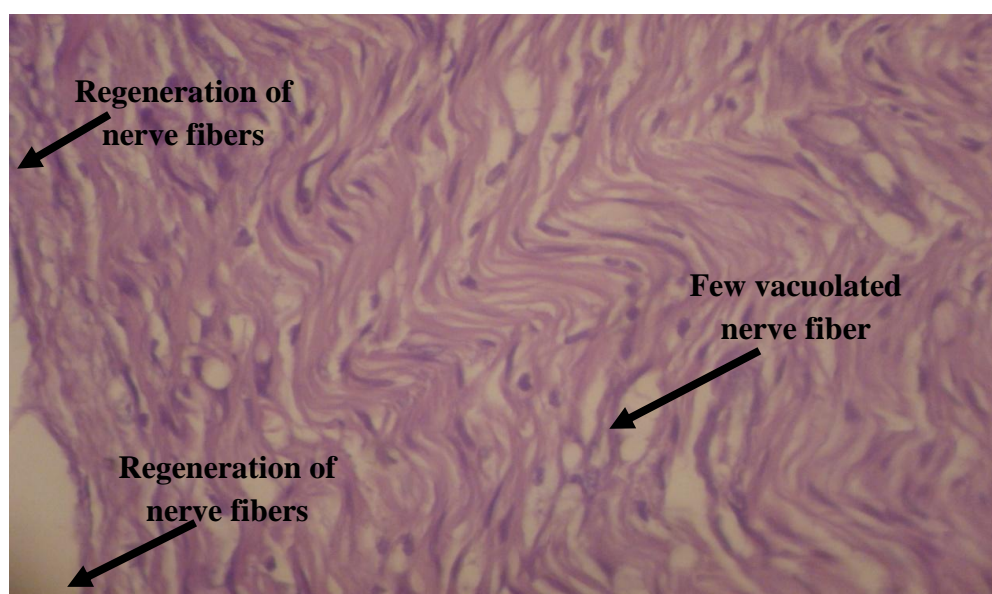


Fig. 9: Section of sciatic nerve after surgical transaction , wrapped by pedicle flap of omentum showed vacuolated, few degenerate nerve fiber also evidence of nerve fiber regeneration (Treated group) X40

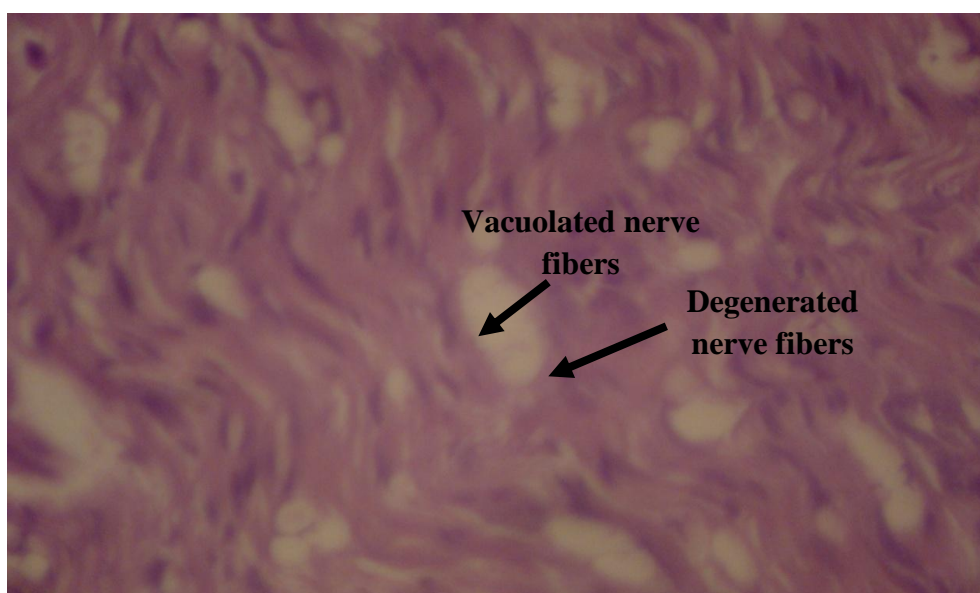


Fig. 10 : Section of sciatic nerve revealed vacuolated nerve fibers and degenerated nerve fibers (Control group) X40

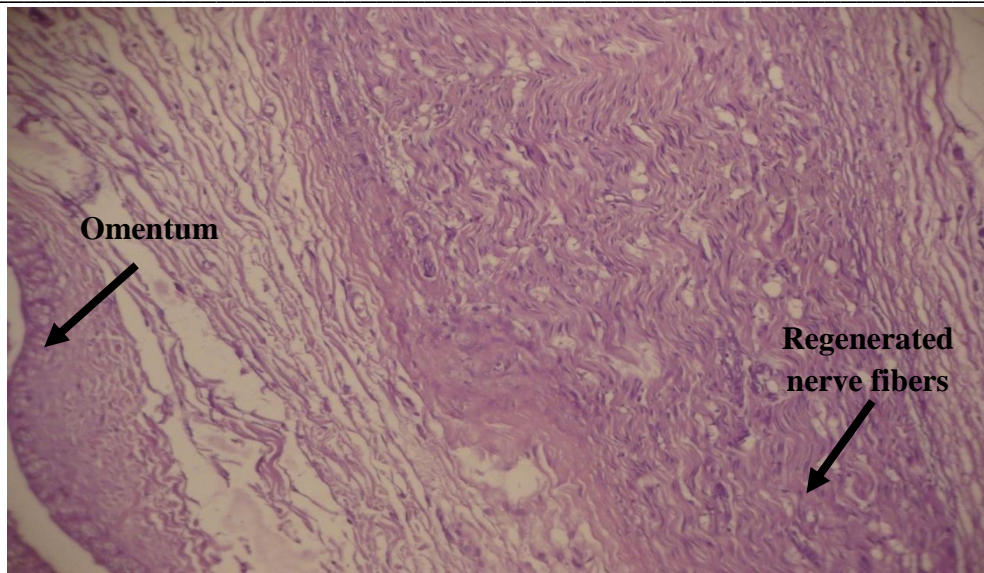


Fig. 11: Section of sciatic nerve after surgical transaction wrapped by pedicle flap of omentum revealed omentum and regenerated nerve fibers (Treated group) .
X40

Section from proximal and distal part of sciatic nerve were examined, in animals of treated group showed regenerated small axons associated with increase in the number of Schwann cells nuclei (Fig.5,8). Also showed the vacuolated degenerated

nerve fibers (Fig.9) when the omentum was thoroughly assessed on the light microscopy the fascicular formation were observed in some animals. Therefore these signs were thinner and irregular and surrounding perineurium was not observed.

Discussion

We have chosen study the effect of omentum in neuroraphies because of its rich vascular anatomical structure and the characteristics of the serous membrane with its selective permeability which overlies it, the peritoneum which cover the lymphatic and vascular tissues provides an equilibrium between the secretion and resorption thus effects the healing in the abdominal pathologies. On other hand the cellular elements of healing process, the fibroblast, macrophage can easily reach the neuroraphy site through the rich lymphatic and vascular network provide by omentum and thus cause rapid and effective healing of peripheral nerves (3). Knuckling is considered as a natural result of sciatic nerve paralysis or severed and that explain the main sign which noticed at the 2nd week due to inability to transport the neuropulsation (8). While the cause of disappearing of knuckling at the 4th week in the treated group was the passing of regenerated neurofibres from distal to proximal ends of sutured sciatic nerve (9).

So the neural pulsation began to transport from distal to proximal ends because that the omentum contain neuroactive substances as acetyl choline transferase which is responsible for convert acetyl – co enzyme A to acetyl cholin which support the transporting of neuropulsation (10). Furthermore omentum contain acidic fibroblast growth factor which have ability to hasten regeneration of the axons (11) so blood supply of omental pedicle flap consider as important factor to stimulate the ability of omentum to increase the regeneration of peripheral neurofibres (12) while the cause of swelling on the site of operation of treated group was due to the wrapping of omentum on injured sciatic nerve and the ability of omentum to increasing the adhesions with adjacent tissues (13) Many different technical improvement have been aimed to achieve better cooptation in peripheral nerve repairs, such as laser magnetic field alternative but none of them proved to be superior over conventional epineural suture

technique. The omentum has been extensively used in neurosurgery since the beginning of 1970s for many years, however it has been through that increase in blood flow was the only factor involved on the effects of the transplant (14). Omentum and peripheral nerve regeneration in the literature: yet all reports have been imposed that omentum activating character of omentum, we decided to use omentum graft (15). Our results about omentum were contradicting to the findings in the literature. In the present study, the omentum treated the animals and could be used safely and effectively to promote peripheral nerve regeneration. The biological and mechanical structure of the omentum is an important factor in order to achieve an effective nerve regeneration. The discovery of several substances in the omentum

Acknowledgment

I should like to thank professor Dr. Abdulbari Abbas Sahi for his valuable comments and ideas and visiting professor

AFGF, VEGF, CGRP, GABA, r LI, 5-HT, norepinephrin, beta endorphin, IL-6, IL-2, 1T-8 AND met-enkephalin these factors capable of being adapted to the environment of transplant there were only few reports about (15). In conclusion the present experiment showed that dog with transected sciatic nerve without omentum showed higher number of degenerated / vacuolated nerve fibers with perineural fibrosis while the transected sciatic nerve with omental pedicle flap showed far less number of degenerate vacuolated nerve fibers but also associated with regenerated nerve fibers. That indicate using of pedicle flap of omentum with association of transaction of sciatic nerves will speed the recovery of transected sciatic nerve by increase the regeneration nerve fibers, also hardly any perineural fibrosis.

Dr. S. K. Majeed for doing the histopathology and the lecturer A. A. Ibrahim for technical assistance.

References

1. Ozbek, M.; Kutlu, N.; Emiroglu, M. and Wormuk. E. (1990). The Effect of Omental Vascularization on Peripheral nerve healing. Turkish Journal of research in medical sciences ;8:432-439.
2. Michon J. and Moberg E. (1975): Traumatic nerve lesion of the upper limb. Churchill Livingstone. Edinburgh. PP:87.
3. Cameron Platell; Deborah Cooper; John ,M. Papadimitriou and John ,C. Hall (2000): The Omentum. World J. Gastroentero;6(2):169-176.
4. Kiricuta, I. (1980). Use of Omentum In Plastic Surgery (1st ed.). Editura Medical Romania.
5. Ibrahim, A.F. (2001). The Effect Of Wrapping Of Omentum On graft peripheral nerve regeneration .MS.C. thesis college of Vetereinary Medicine University of Baghdad.
6. Bo Levander (1977). Studies on the absorption of lumbar cerebrospinal fluid by pedicle graft of the greater omentum .Acta Neurochirurgica. Stockholm:9-22
7. Goldsmith, H.S.; Delos Santos. and Beattie, E. (1967). Relief of chronic lymph edema by omental transposition. Annals of Surgery. October:573-584.
8. Yao, M.; Inserra, M. M.; Duh, M.J. and Terris, D.J. (1998). A longitudinal functional nerve recovery in the Mouse. The Laryngoscop. 108:1141-1145.
9. Swaim ,S.F. (1978). Peripheral nerve Surgery (chapter 10). in Canine neurology diagnosis and treatment (Hoevlien, B.F. Ed.). (3rd ed.). W.B. Sanders Company Philadelphia PP.296-318.
10. Goldsmith, H.S.; McIntosh, T.; Vezina, R. M. and Colton, T. (1987). Vasoactive Neurochemicals identification in omentum : A preliminary report British J. Neurosurg. 1;359-364.

11. Cordiero,p.G.;Seck,B.R.;Lipton,S.A.;D Amore,P.A;Wanger,J and Madison ,R.(1989) Acidic fibroblast growth factor enhance peripheral nerve regeneration in vitro. Plast. Reconst. Surgery 83: 1013-1019.
12. Goldsmith,H.S(1994).Brian and Spinal cord revascularization by omental transposition .Neurol.Res.16:159-162.
13. Hosgood,G.(1990).The omentum-the forgotten organ: physiology and potential surgical application in dogs and cats. The Compendium small animal.12(1);45-50.
14. Anger, c.; Yeomans. D.; Dujovny, m. (2001). The neurochemichal basis for the application of the greater omentum in neurosurgery. Neurol. Res. 23(1):7-15.
15. Odaka, M.; Oka, M.; Takami, T. and Uchiyama, Y. (2003).Evaluation of morphological and functional regeneration of rat nerve muscles unites after temporary and permanent tubulilization. Muscles nerve. 28(2);194-203.

دراسة تأثير لف سويق الثرب في شفاء جروح العصب الوركي

باسم كاظم خشجوري

كلية الطب البيطري/جامعة البصرة

الخلاصة

أجريت هذه الدراسة لمعرفة تأثير لف سويق الثرب في خياطة العصب الوركي لثمانية كلاب تم تقسيمها إلى مجموعتين متساويتين. أجريت خياطة العصب الوركي بعد قطعه في حيوانات المجموعة المعاملة وبعد ذلك حضر سويق الثرب عن طريق إجراء عملية فتح البطن خلال الخط البطني الوسطي إذ تم سحبه في المنطقة الاربية خلال نفق مستحدث جراحي ولف حول الجزء المخاط من العصب الوركي. أما حيوانات مجموعة السيطرة فقد أجريت لها خياطة العصب الوركي دون لف سويق الثرب على العصب. فحصت عينات المجموعتين نسيجياً بعد مرور 60 يوم ,وأظهرت النتائج وجود زيادة في عدد الالياف العصبية المتوالدة وانخفاض التليف العصبي في منطقة القطع الجراحي لحيوانات المجموعة المعاملة مقارنة بمجموعة السيطرة.