

Effect of application of Fenugreek (*Trigonella foenum-graecum*) on skin wound healing in rabbits

D. O. Muhammed

N. A. Salih

Coll. of Vet. Med./ Unive. of Sulaimani

Abstract

Fenugreek has a long history of medical uses in Chinese and Kurdish medicine, the objective of this study is to determine the effectiveness of topical application of fenugreek on the wound healing in rabbits. Twenty adult healthy local breed male rabbits weighing 1600-1800 gram were used. Animals were divided into two equal groups, by surgical aseptic technique, two surgical skin incision at length of 3 cm in the back region were done on both side of the vertebrae, then they closed by simple interrupted pattern by silk (3/0). Control group treated with Vaseline while in treated group the wounds were covered with 10% fenugreek ointment twice daily for 21 days. The clinical and histopathological evaluation revealed that fenugreek promote the wound healing by early formation of cellular fibrous connective tissue, granulation tissue and early maturation of fibrous connective tissues, which characterized by regular and complete layer of epidermis, when compared with control group, in conclusion this study indicated that the fenugreek was enhanced wound healing and that may be due to it is therapeutic and nutritional activities.

Introduction

Historically, fenugreek was used for a variety of health conditions, including menopausal symptoms and digestive problems. It was also used for inducing childbirth. Today, it is used for diabetes and loss of appetite, and to stimulate milk production in breastfeeding women. Some people mix Fenugreek powder into massage oil to stimulate circulation and allow the nutrients in the powder to be absorbed directly into the skin. Fenugreek powder is rich in nutrients like vitamin E, vitamin A, vitamin B1 and vitamin C. The product is

inexpensive, readily available and can be used in a variety of ways (1). Fenugreek seeds are a rich source of the polysaccharide galactomannan, saponins such as diosgenin, yamogenin, gitogenin, tigogenin, and neotigogens. Saponins can produce steroidal effects that could reduce inflammation in the body. Other bioactive constituents of fenugreek include mucilage, volatile oils, flavonoids and amino acid, alkaloids. The other active ingredient found in fenugreek is 4-hydroxyisoleucine.(2,3).

Materials and Methods

For this experiment twenty male domestic rabbits from local breed were used. Their age and body weight were from 6 -to- 8 months and 1.6 -1.8 kg respectively. The rabbits were physically healthy and were adapted pre-experimentally for one week, They were reared at an optimal room temperature ranged between 22-25°C and were exposed to artificial light for 12 hrs./day. The area of incision was previously shaved, disinfected with 70% alcohol and after inducing general anesthesia with intramuscular injection of (10 mg/kg

xylazine and 40mg/kg ketamine). Animals were divided into two equal groups, by surgical aseptic technique, two surgical skin incision at length of 3 cm in the back region were done on both side of the vertebrae, then they closed by simple interrupted pattern by silk (3/0), Group one animals were treated with a thin layer of Vaseline twice daily as control, Group two were treated with 10% of fenugreek seed ointment twice daily. Along the treatment periods the animals were observed for evidence of any abnormalities such as infection, exudate, untile complete

healing. Biopsies were collected from 5, 15, and 21. The specimens were then fixed in 10 % neutral buffered formalin solution for 72 hrs, after that they were trimmed, dehydrated, cleared, embedded in paraffin wax, sectioned at 6 micrometer thickness and the sections were stained with hematoxylin and eosin stain (4).The fenugreek seeds were obtained from local market in sulaimanya

were washed with distilled water and dried separately in an oven at 50C for 4 days until fully dried then they were grounded to a fine powder using a grinder and used for the experiment, the seed powder were homogenously mixed with Vaseline in a concentration of 10% (w/w), kept at room temperature until time of application.

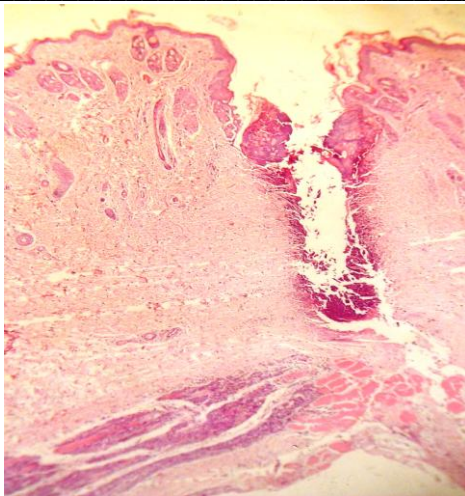
Results

The examination of slides from the fenugreek sample in day-5 shows that the changes of inflammatory cell infiltration and granulation tissue reaction have started earlier and they are more prominent when compared with control sample at day 5, Re-epithelialization has started in fenugreek sample while it has not in control. In second set of samples we have slides from day 15 of a fenugreek sample and the changes are far more advanced than control sample (day 15 of injury). In third set of samples at day 21 of injury the test sample shows normalization of epithelial layer, formation of few hair follicles, marked maturation of collagen and complete submission of inflammatory cell reaction and granulation tissue reaction while the control sample shows that epithelial layer has been restored to near normal but not fully matured, the granulation tissue and inflammatory cell reaction are still

present but to a slight degree, collagen maturation although has started yet it is not matured and not advanced as that of the fenugreek sample. We also found during microscopically examination of slides from few test samples that when fenugreek preparation is not well ground and contain large fragments it interfere with healing of the wound and has a negative effect because the large fragments act as foreign particles that prevent proper approximation of wound edges and elicit a strong foreign body type chronic inflammatory response which causes delay of healing as it creates un-wanted tissue injury. Therefore this is an additional finding which explains the fact that highly grinding of the fenugreek into a very fine powder from the herb is a better and more efficient method to make medicinal use from this herb.

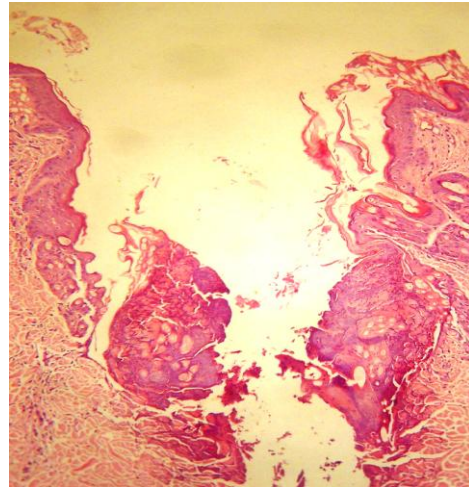
Table (1) for comparison of histopathological changes in skin wound in control sample and fenugreek sample divided into three groups. (A=5 days, B= 15 days and C= 21 days)

CRITERIA	CONTROL WITH OUT FENUGREEK	TEST WITH FENUGREEK
inflammation	A- Mild to moderate B- moderate C- residual and mild	A-Marked. B-slight C-no
granulation	A-No B-marked C- still present	A-marked B-reduced. C-no
Re-epithelialization	A-No B- started C- Nearly complete	A- started B-complete C- normalized
Collagen	A-No B-No C- Half complete	A-No B-starting to mature. C- mature

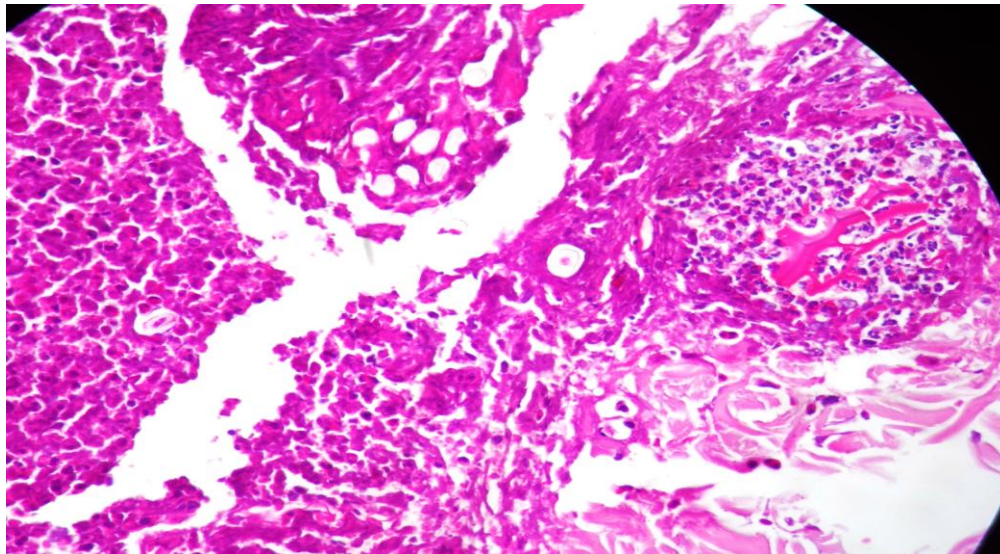


Power 10

Control 5 days



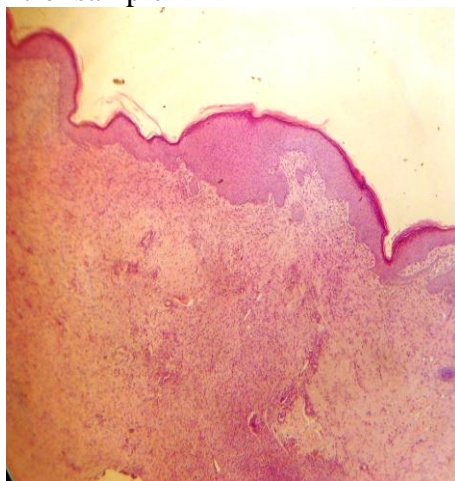
power 40



Power 100

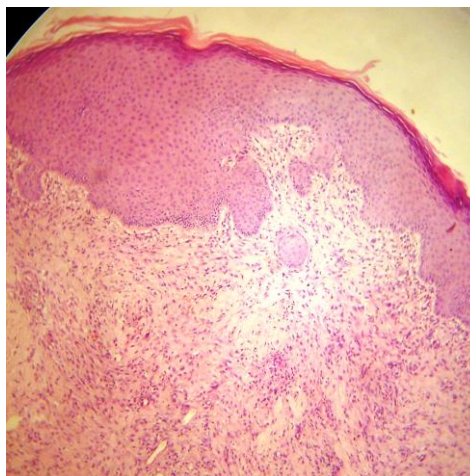
Control 5 days

Section from skin at site of wound showing acute inflammation still marked on 5th day after injury in control sample

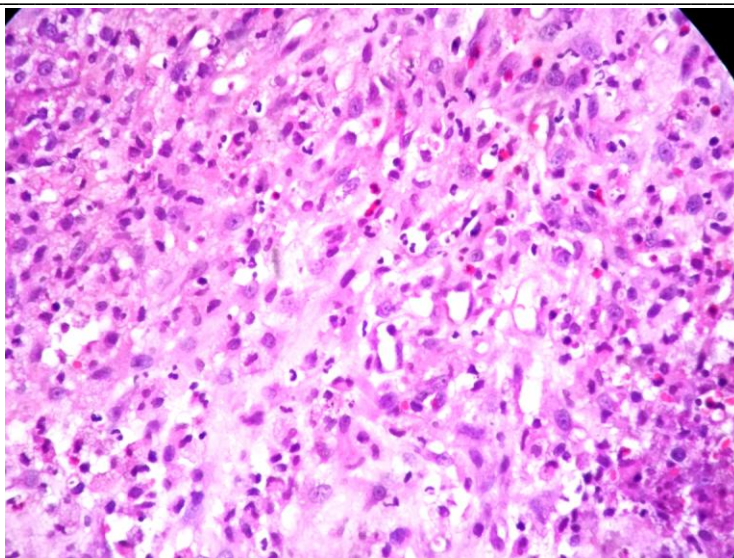


Power 10

(Control 15 days)

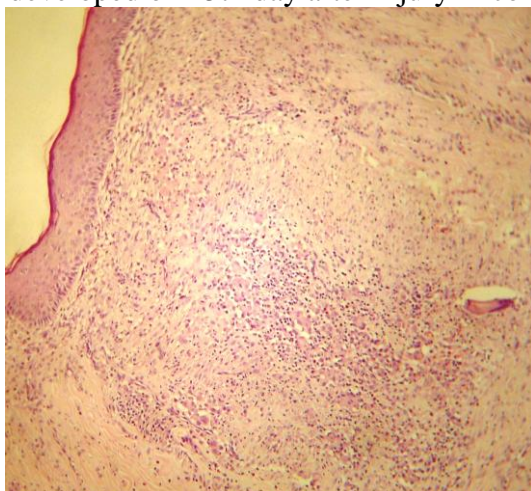


power 40



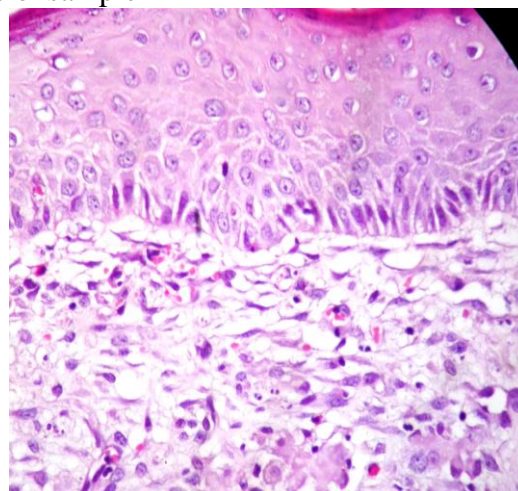
Power 100 (Control 15 days)

Section from skin at site of wound showing that collagen formation and granulation tissue are not as well developed on 15th day after injury in control sample



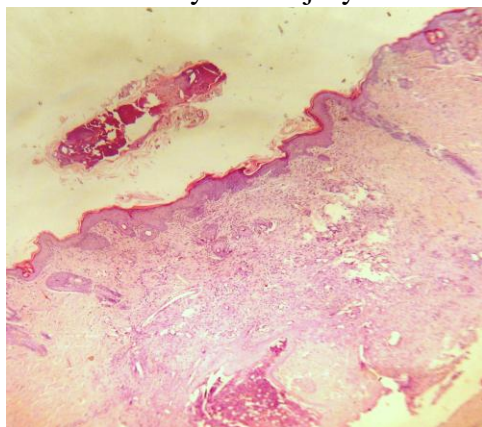
Power 10

(Control 21 days)

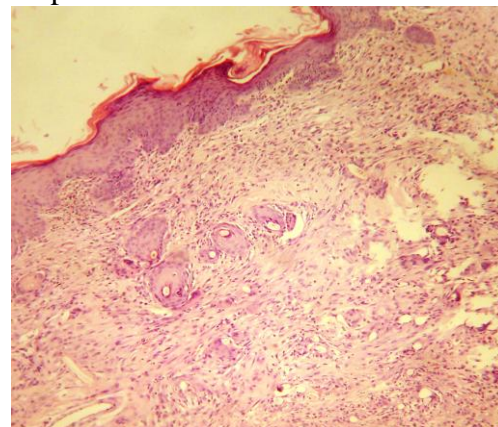


power 100

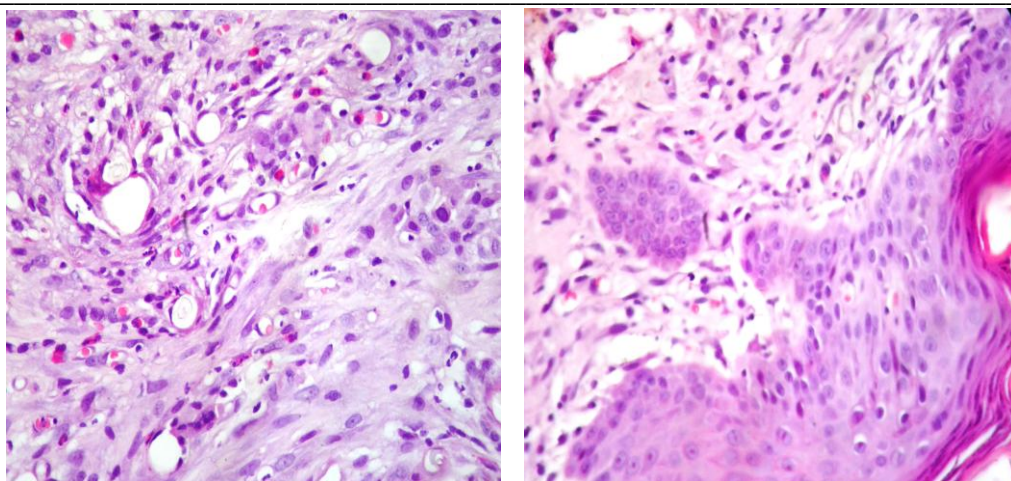
Sections from skin at site of wound show relative delay of fibrous scar formation and persistent inflammation on 21st day after injury in control sample



Power 10



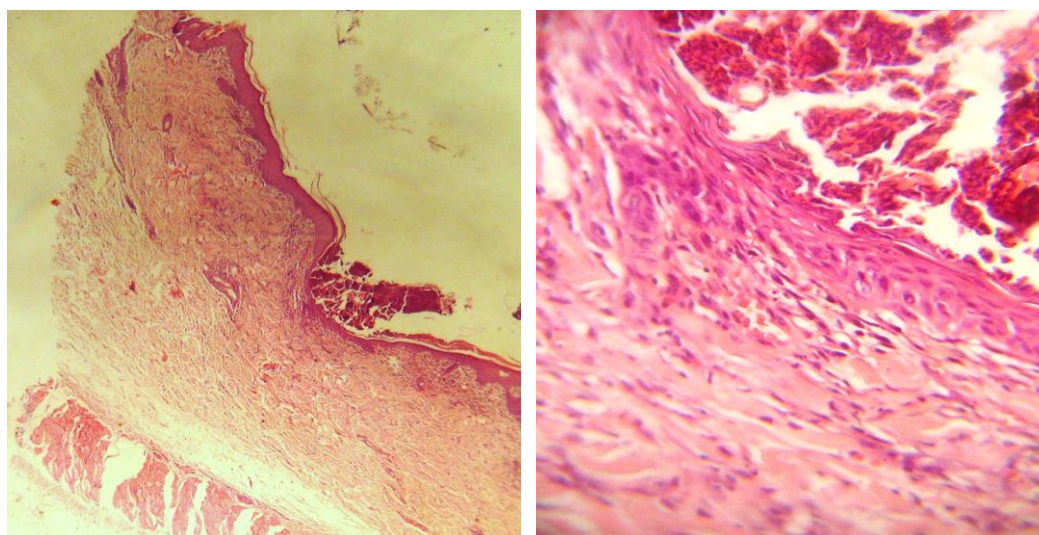
(Fenugreek 5 days)



Power 100

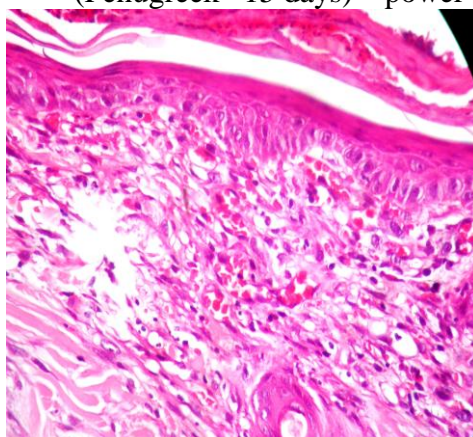
(Fenugreek 5 days)

Sections from skin at site of wound in fenugreek-treated sample shows brisk granulation tissue reaction on 5th day after injury



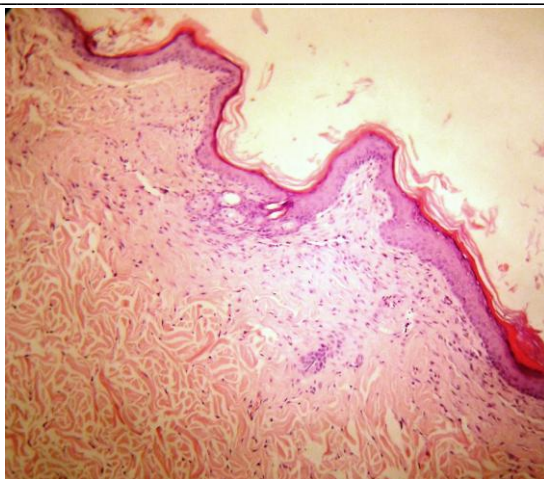
Power 10

(Fenugreek 15 days) power 40

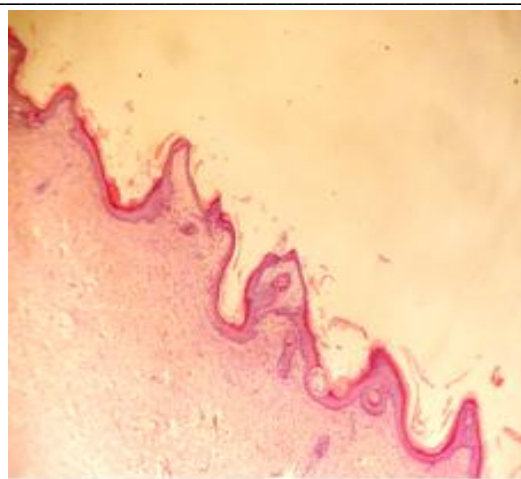


Power 100

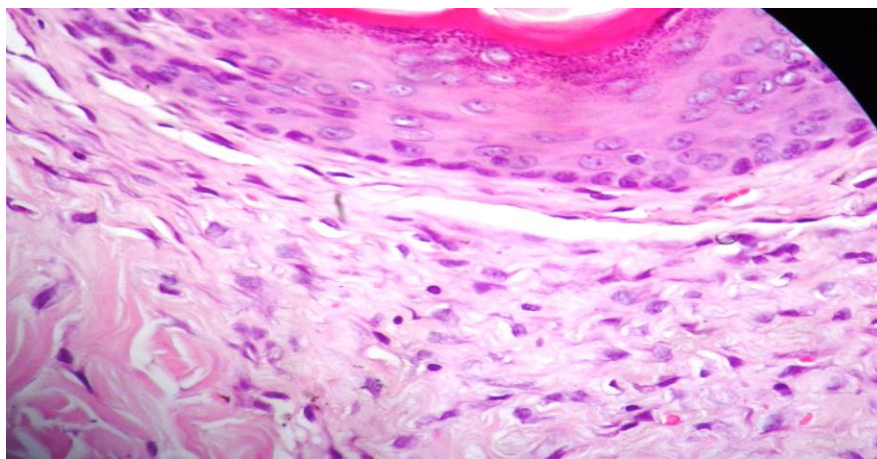
Sections from skin at site of wound in fenugreek-treated sample show regression of granulation tissue reaction and gradual replacement by immature fibrous tissue on 15th day after injury



Power 10

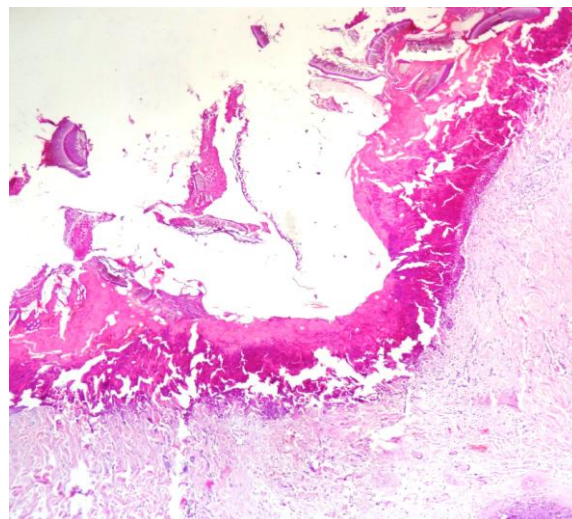
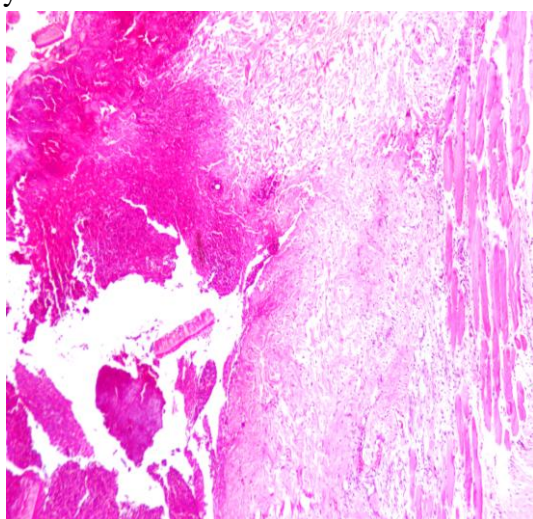


Fenugreek 21 days power 40



Power 100

Sections from skin at site of wound in fenugreek-treated sample show complete regression of granulation tissue reaction and its replacement by organized fibrous tissue on 21st day after injury



Sections from skin at site of wound in fenugreek-treated sample show large fragments of fenugreek preventing approximation of wound edges thereby causing failure of re epithelialization and marked foreign body type inflammatory reaction on 21 day after injury

Discussion

Wound healing is a biological process that begins with trauma and ends with scar formation. The goals of wound care include reducing risk factors that inhibit wound healing, enhancing the healing process and lowering the incidence of wound infections. Many medicinal plants have been found useful in wound healing this facts leads to find therapeutically useful compounds, thus more efforts should be made towards isolation and characterization of the active principles and elucidation of the relationship between structure and activity. The combination of traditional and modern knowledge can produce better drugs for wound healing with fewer side effects (5). Fenugreek, when applied to a wound, releases its anti-inflammatory properties and works to maintain the healing process and reduce the inflammation that is no longer needed as the wounds heals. Fenugreek seeds contain fatty acids which build collagen that is promoted wound healing and maintain skin elasticity (6). Recent studies have shown fenugreek to be an anti-inflammatory, which supports its traditional use as a treatment for sore throat, arthritis, and wound healing. Commission E, a group that evaluates the safety and efficacy of herbs for the German government, approves fenugreek for treatment of inflammation, loss of appetite, and gastritis. Fenugreek seeds contain a gumming substance called mucilage. This mucilage expands and becomes a gelatinous soother for incised tissues and helps sooth skin inflammation by coating the incision area and also keeps the site moist and gives a soft texture to the skin

during healing process, this moisture and nutritional activities of the seeds enhance debridement, neutrophils cell life and proteolytic enzymes which lead to painless debridement (3,7).(7) (8), (9) and (10) demonstrated that Fenugreek seeds are rich in polysaccharide galactomannan (that has exhibited significant wound healing property; our results confirm their finding that fenugreek play major role in wound healing process, if the fenugreek is in fine powder form and mixed and prepared in homogenized mixture, while if the particle of fenugreek is not grinded well this will give a negative result on wound healing process as this fact is confirmed by histopathological slides. The ability of the fenugreek to augment the healing process might be attributed to a number of chemical ingredients present in the extract, which may have angiogenic and mitogenic potential. Flavonoids and triterpenoids, which have been identified in the drug extract, might promote the wound-healing process due to their astringent and antimicrobial properties (11). The results of other research indicate that vegetables containing high phenolic may provide a source of dietary anti-oxidants; fenugreek is great antioxidant so it can be suggested that the healing activity of fenugreek may be in part due to it is antioxidant activity (12). Fenugreek either promotes direct wound repair or exhibit antimicrobial and other related properties which are beneficial in overall wound care which may lead to clean wound without secondary infections.

References

1. MacKay DJ, Miller AL (2003). Nutritional support for wound healing. *Altern. Med. Rev.* 8(4):359-377
2. Acharya S N, Srichamoren A, Basu S, Ooraikul B, Basu T. 2006. Improvement in the nutraceutical properties of fenugreek (*Trigonella foenum-graecum* L.) Songklanakarin J. Sci. Technol. 28(1): 1-9.
3. Joanne B., Linda. A and. Philipson J. D, (2002). *Herbal medicines*. (Second edition), published by pharmaceutical

- press (publication division of the Royal pharmaceutical society of Great Britain 204-210.
4. Culling, C.F.A.; Allison, R.T.; Barr, W.T.(1985) .Cellular pathology technique.4th ed. London; Butter Worths:155-163.
 5. Clark RAF (1991). Cutaneous wound repairs. In: Goldsmith LA (ed.) Physiology, Biochemistry and Molecular Biology of Skin. New York: Oxford University Press, p.576.
 6. Dixit, P., Ghaskadbi, S., Mohan, H. and Devasagayam, T. P. A. (2005), Antioxidant properties of germinated fenugreek seeds. Phytotherapy Research, 19: 977–983
 7. Toppo, F.A., R. Akhand and A.K. Pathak, 2009. Pharmacological actions and potential uses of *Trigonella foenum-graecum*: A review. Asian J. Pharm. Clin. Res., 2: 29-38.
 8. Taranalli, A.D. and I.J. Kuppast, 1996. Study of wound healing activity of seeds of *Trigonella foenum-graecum* in rats. Indian J. Pharm. Sci., 58: 117-119.
 9. Issarani, R. and B.P. Nagori, 2004. FTIR-spectrum of galactomannan extracted from *Trigonella foenum-graecum*. Indian J. Pharm. Sci., 3: 358-359.
 10. McAnalley, B.H., R.H. Carpenter, H.R. McDaniel, R. Harley and Carrington Laboratories, Inc., 1995. Wound healing accelerated by systemic administration of polysaccharide from aloe.
 11. Badri P. N. and Renu S., 2011. Role of Medicinal Plants in Wound Healing. Research Journal of Medicinal Plant, 5: 392-405.
 12. Kaur, C. and Kapoor, H. C. (2002), Anti-oxidant activity and total phenolic content of some Asian vegetables. International Journal of Food Science & Technology, 37: 153–161.

تأثير نبات الحلبة *Trigonella foenum-graecum* على التئام الجروح في الجلد في الأرانب

ديرين عمر محمد نادية عبد الكريم صالح
كلية الطب البيطري / جامعة السليمانية
الخلاصة

استهدف البحث دراسة تأثير الاستعمال الموضعي لنبات الحلبة على التئام الجروح في الارانب. استعمل في التجربة عشرون ارنب من الذكور و قسمت الى مجموعتين (كل مجموعة تحتوي على عشرة ارانب) وبعد تحضيرها جراحيا و تخديرها عمل شقين جراحيين في الجلد بطول 3 سنتيمتر في منطقة الظهر وخط الجرح بطريقة المتقطع البسيط بواسطة الحرير قياس 3\0 , مجموعة السيطرة عولجت بمادة الفاسالين ,في حين استعمل في مجموعة الثانية مطحون حبوب نبات الحلبة مع الفاسالين بنسبة 10% مرتين في اليوم و لمدة 21 يوم و اظهرت نتائج الفحص العياني والنسيجي ان نبات الحلبة قد ساعد في شفاء الجروح عن طريق تكوين المبكر للنسيج الحبيبي ونضوج النسيج الضام والذي تميز بانتضام اليافه و اكتمال طبقة البشرة التي تغطيه.