

IMMUNOHISTOPATHOLOGICAL STUDY OF BOVINE BILE SALT AGAINST *SALMONELLA* TYPHIMURIUM INFECTION IN RABBITS

Hawraa M. Murad* , Ahlam J.H.AL-Khamas , Suhad J., Rawaa S.A.AL-Azawi
College of Veterinary Medicine Al Qasim Green University, Babylon
***E-mail: howraa_alhussaini@yahoo.com**

Abstract:

The current study was carried out to investigate some immunohistopathological effects of bovine bile salts against *Salmonella typhimurium*. In laboratory animal thirty albino rabbits of both sex that ages ranged between (10-12) months were divided randomly into three groups ,the first group immunized orally by 0.5ml (5mg/ml) and the second group immunized orally with 0.3ml (3mg/ml) of bile salts in zero time after two weeks the same doses repeated against *Salmonella typhimurium*, then delayed type hypersensitivity test was made on these groups and compared with the third group "that had been inoculated with 0.5 ml of sterile PBS as a control group at day 27 post immunization using soluble bile salts. At day 30 half number of animals from each group were scarified. Then challenge dose by 1ml of *salmonella typhi* were injected intraperitoneally (I/P) for the remaining half of all study groups ,then after three days they scarified. Samples of blood were collected from each group to ELIZA analysis for determine the level of IgG in serum in order to obtain their tissues for histopathological .The results showed that marked necrotic lesion, together with blood vessel congestion accompanied by hyperplasia with hypertrophy goblet cell of intestine and thickness of splenic capsule due to mononuclear cells (MNCs) infiltration. While the immunized groups with bile salts revealed presence of granulomatous lesion in liver with lymphoid hyperplasia and slight megakaryocyte proliferation in spleen. Finally, the results showed that the bile salts was highly immunogenic against *Salmonella typhimurium* and its toxins and this may be related to the fact that the one of component of bile salts deoxy cholic acid in their structure which has the ability of destroyed effect on salmonella and their toxins in the rabbits tissues.

Keywords: *Salmonella typhimurium*, Bile salts, Rabbits, ELISA.

دراسة مناعية مرضية لأملاح الصفراء البقريّة ضد الإصابة بالسالمونيلا تيفونيد في الارانب

حوراء محمود مراد، احلام جابر حمزة الخماس، سهاد جميل هادي، رواء صفاء عباس العزاوي
كلية الطب البيطري /جامعة القاسم الخضراء- بابل -العراق

الخلاصة :

أجريت هذه الدراسة لبحث بعض التأثيرات المناعية المرضية لأملاح الصفراء على الاستجابة المناعية ضد الإصابة بالسالمونيلا تيفونيد في الارانب المختبرية. ثلاثون أرنباً من كلا الجنسين تتراوح اعمارهم بين (10-12) شهر تم تقسمهم عشوائياً الى ثلاث مجاميع. وشملت هذه الدراسة تمنيع المجموعة الأولى والثانية بجرعة 0.5 مل ، 0.3 مل على التوالي من املاح الصفراء فمويًا في الارانب ضد السالمونيلا تيفونيد في زمن الصفر (بداية التجربة) ثم تم اعادة التجريب بعد اسبوعين وبنفس الجرعة بعدها اجري اختبار فرط الحساسية المتأخر وقد تم مقارنتها مع مجموعة السيطرة (المجموعة الثالثة) والمجرعة 0.5 ب مل من المحلول الملحي الفسلجي في اليوم 27 وتم تشريح نصف عدد الحيوانات من كل مجموعة في اليوم الثلاثين لفصل المصل وقياس مستوى الاجسام المضادة IgG. ثم حقنت الحيوانات المتبقية من المجاميع الثلاثة بجرعة التحدي الحاوية على ما يقارب امل من السالمونيلا تيفونيد / لكل حيوان داخل الخلب وتركت الحيوانات لمدة مقارنة لثلاثة ايام، بعدها قتلّت لا جراء الفحوصات المرضية النسيجية وقد اظهرت النتائج بجرعة التحدي في أكباد حيوانات السيطرة آفات نخريه مع احتقان الاوعية الدموية ويصاحبها فرط تنسج في الخلايا الكأسية للأمعاء، وتنسج في المحفظة الطحالية بسبب ارتشاح خلايا العدلة وحيدة النواة (MNCs)، مع ترسب النشوان في الطحال اما المجاميع التي منعت بأملح الصفراء اظهرت، ورم حبيبي في الكبد مع وجود فرط تنسج لمفاوي وتكاثر الخلايا العملاقة في نسيج الطحال. أخيراً بينت النتائج أن الأملاح الصفراء اعطت مناعة عالية ضد الإصابة بالسالمونيلا وسمومها، وهذا قد يعزى لحقيقة أن أحد مكونات املاح الصفراء هو حامض (Deoxy cholic acid) في بنيتها وهذا الأخير لديه تأثير محطم للسالمونيلا في الانسجة.

الكلمات المفتاحية: السالمونيلا تيفونيد، املاح الصفراء، الارانب، الاليزا

be efficiently excreted in urine because they are insoluble or protein bound, for example "cholesterol which is derived from excess synthesis or the pigment bilirubin, the end product of hemi metabolism, which is carried in blood attached to albumin proteins (2). Finally, some of the secondary bile salts generated by microorganisms are potentially toxic and/or mutagenic. It is suggested that they can disturb the normal micro biota of the gut leading to diarrhea, mucosal inflammation or activation of harmful drugs and carcinogens in the intestinal contents (3).

Introduction :

Bile is a fluid containing bile salts, cholesterol, and a variety of proteins and electrolytes, bile is synthesized by parenchymal cells hepatocytes in the liver. In mammals with a gall bladder, a fraction of bile is stored in the gall bladder while another fraction flows directly into the small intestine (1). The major function of bile in vivo is to act as a biological detergent which emulsifies and solubilizes fats. This also confers potent antimicrobial properties on bile and gives it an important role in the body's physicochemical defense system. Bile also functions as an excretory fluid by eliminating substances that cannot

immunosorbent assay): This test was done according to manufacturer (immunological consultants laboratory, Inc.) to determine the level of IgG in serum.

- 3- Histological examination: Four animals from each groups were scarified under deep anesthesia and specimens from liver and kidney fixed in buffered formalin (10 %), sectioned (5 mm thickness) and stained with Hematoxylin and Eosin according to(4).

Results and discussion :

1- Cellular immune response detected by skin test(delayed type hypersensitivity-DTH).

The results of the current study revealed that the mean values of the skin thickness after 24 hours were significantly ($p < 0.05$) higher in the group that immunized by bile salts for concentration (5mg/ml) which reached 4 ± 0.08 mm as compared with the control group (0.87 ± 0.02) mm , while it was significantly ($p > 0.05$) lower in the group that immunized by bile salts by concentration (3mg/ml) which reached (0.274 ± 0.05) mm respectively as compared to those that immunized by bile salts but significantly higher as compared with control the group (PBS) . Also after 48h, the results were showed a significant difference ($p < 0.05$) in the group that immunized with bile salts for concentration 5mg/ml which were (2.75 ± 0.04) as compared with 3mg/ml concentration which were (1.89 ± 0.09)mm and control group (PBS) (0.66 ± 0.06) mm

Therefore the train of this study was to determine the effect of the bile salts on the immunopathological change in rabbits that infected by salmonella typhimurium.

Materials and Methods

A-Experimental design:

Thirty rabbits were randomly divided into three groups as following:

1. The first group (10) rabbits were immunized orally by (0.5 ml) containing (5mg /ml) of bile salt by two doses for 14 days intervals (first immunization at day 0 and followed by booster immunizations at day 14) .
2. The second group (10) rabbits immunized orally with(0.3ml) containing(3mg /ml)of bile salt for two doses with 14 days intervals (first immunization at day 0 and followed by booster immunizations at day 14).
3. The control group (10) rabbits were inoculated by 0.5 ml of sterile PBS. Then these groups were infected with hydatid cysts after 2 weeks from adaptation were injected intraperitoneally with (1ml/rabbit) containing salmonella typhimurium).

B-Tests

- 1- Cell mediated immune response of experimental rabbit determined by Delayed type hypersensitivity test was done on all animals at 27 day post immunization and post challenge.
- 2- Humoral immune response detected by ELISA(enzyme linked

(p>0.05).

did not show significant difference

Table1: Values of skin thickness in the three groups.

Group	Time	Time
	24 hours	48 hours
1st group animal immunized with bile salt at concretions (5 mg /ml)	4.00±0.08 Aa	2.57±0.04 Ab
2nd group animal immunized with bile salt at concretions(3mg /ml)	2.74±0.05 Ba	1.89±0.09 Bb
3th control group	0.87±0.02 Ca	0.66±0.06 Cb

Different small letters in row denote significant differences between periods (P≤0.05).

inflammatory cytokines mainly IL10 and adaptive modulation of macrophage phenotype in adding to their role in nutrient absorption, BAs were signaling molecules that can control immune cell responses via FXR and TGR5 (6).

2- ELISA test for detecting levels of humeral immunity (Ab Titers)

ELISA test was showed the levels of IgG titer. The results revealed" that there were a significant differences (p<0.05) in the mean values of the groups that immunized by bile salts for both concentrations (5mg/ml) and (3mg/ml) which were (30.68±0.78) as compared with control group (PBS)(6.12±0.040), also there were a significant (p<0.05) differences in the mean value of the group that immunized with bile salts for concentration (3mg/ml) which were (19.96±0.29) as compared with control group (PBS) (6.12±0.40).

The role of bile that had both primary and secondary BAs which could activate the cellular immune response. First, activation of Toll-like receptor 4 (TLR4), by damage-associated molecular pattern molecules released from dead hepatocytes, triggers an inflammatory response. Second, bile acids act as inflammagens, and directly activate signaling pathways in hepatocytes that stimulate production of proinflammatory mediators. Treatment of hepatocytes with bile acids did not directly cause cell toxicity but increased the expression of numerous proinflammatory mediators, including cytokines, chemokines, adhesion molecules, and other proteins that influence immune cell and function (5). The positive skin reaction against bile salt could be attributed to the bile acid that had suppressive effect on cell of innate and adaptive immunity and induced anti-

Table (2): The mean values of antibody IgG titers (ng/ml) of the immunized groups and control group at 30th days:

Group	Time
	24 hours Mean±SE
1st group animal immunized with bile salt at concretions (5 mg /ml).	30.68±0.78 A
2nd group animal immunized with bile salt at concretions(3 mg /ml).	19.96±0.29 B
3th control group	6.12±0.40 C

Different capital letters in column denote significant differences between periods (P≤0.05).

intestine infiltration inflammatory cell and hyperplasia with hypertrophy goblet cell (figure 2). The predominant splenic lesion was characterized by slight thickness of splenic capsule due to MNCs infiltration figure (3).

B. Group(2).Oral immunized group with (3mg/ml) of bovine bile salts.

Microscopic pictures of liver tissue showed small granulomatous lesion in liver paranchyma (figure 4). In addition to presence of small granulomatous lesion consist of neutrophils intense PMNs aggregation (figure 5).Also the histopathological section in spleen showed per arteriolar lymphoid hyperplasia (figure 6).

C. Group(3).Oral immunized group with (5mg/ml) of bovine bile salts.

There is no clear histopathological changes in hepatic liver of this group (figure 7),While in histopathological section of intestinal tissue The predominant lesion showed sub mucosal MNCs infiltration associated with slight

This current study showed the titer of IgG by bile salts was high significant. Whereas bile acids in extra reduce the cell-mediated immune response, their effects on the humeral response have been many investigated, the results are contract with(7 and 8) Biliary epithelial cells participate in both innate and adaptive immunity. (9 and 10). In contrast, the adaptive immune response induces memory to foreign antigens and is mediated by both B and T cells. Following activation, the adaptive immune response can also stimulate the production of a variety of cytokines and the recruitment of inflammatory cells (11).

3- Histopathological changes

A. Group (1) None immunized infected animals (positive control group).

The characteristic macroscopically found in the liver of non-immunized infected Rabbit was presence of intense MNCs aggregation, necrosis, together with blood vessel congestion (figure 1), while the result of histopathological changes in

deposition with slight megakaryocyte proliferation (figure 9).

desquamation of intestinal mucosa (figure 8) and the splenic microscopically lesion showed diffuse amyloid like substances

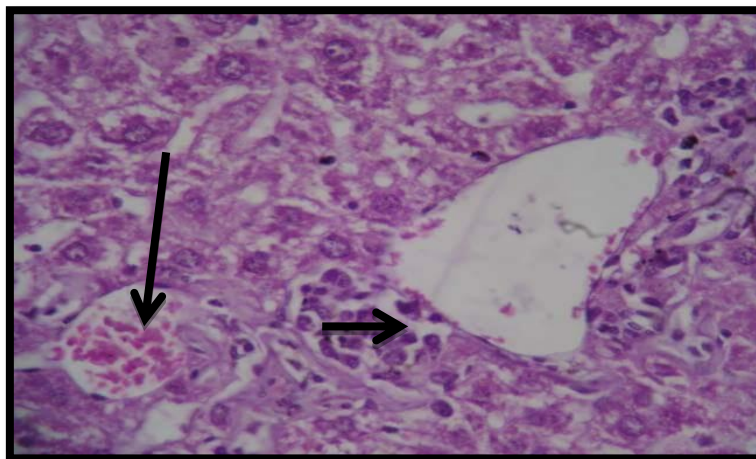


Fig:(1). Histopathological section in liver of non-immunized animals infected shows intense MNCs aggregation, necrosis, together with blood vessel congestion (H&E stain 40x)

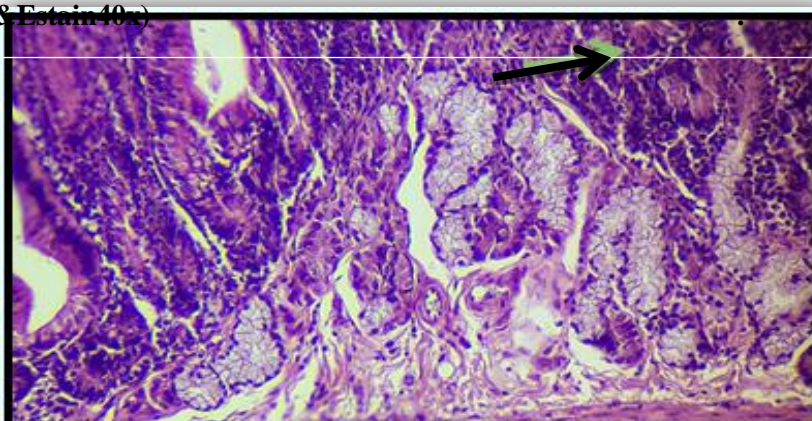


Fig:(2). Histopathological section in the intestine of non-immunized infected animals shows infiltration inflammatory cell and hyperplasia with hypertrophy goblet cell (H&E stain 40x).

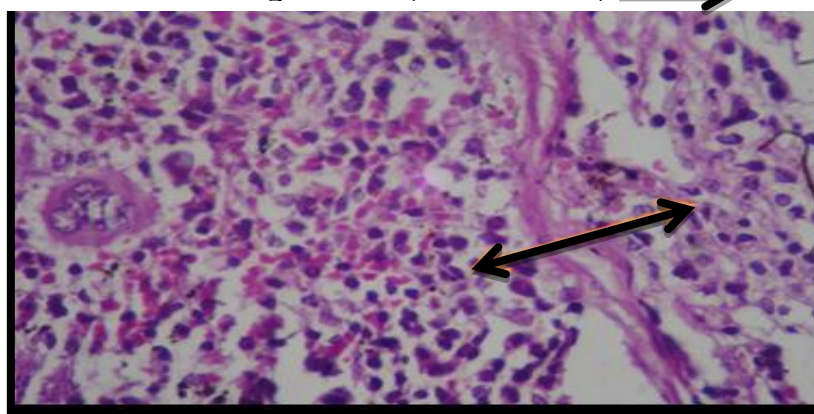


Fig:(3). Histopathological section in the spleen of non-immunized animals shows slight thickness of splenic capsule due to MNCs infiltration (H&E stain 40x).

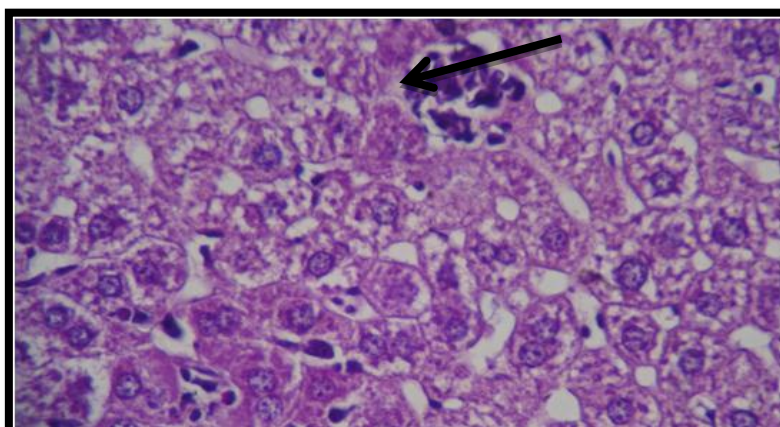


Fig:(4).Histopathological section in liver of Immunized group with (3mg/ml)of bovine bile salt shows small granulomatous lesion in liver paranchyma ←(H&E stain 40x).

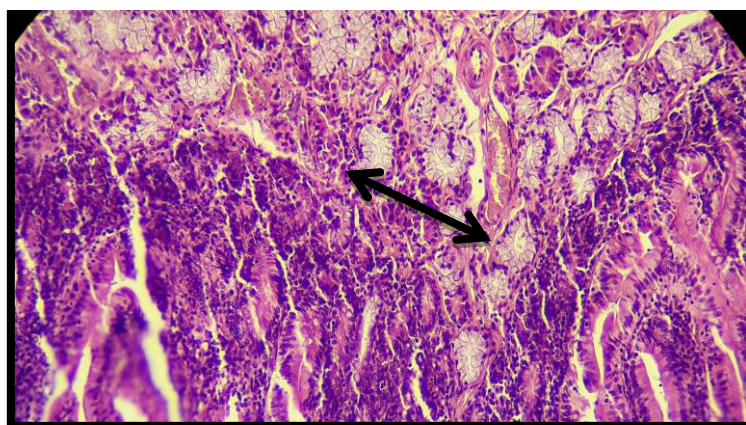


Fig:(5).Histopathological section in intestine of immunized animal with (3mg/ml)of bovine bile salts shows presence of small granulomatous lesion consist of neutrophils intense PMNs aggregation ↔ (H&E stain 40x).

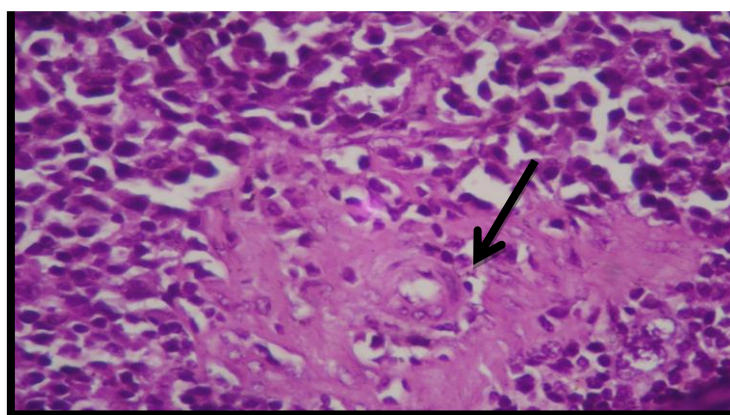


Fig:(6). Histopathological section in spleen Immunized group with (3mg/ml)of bovine bile salt shows per arteriolar lymphoid hyperplasia → (H&E stain40x).

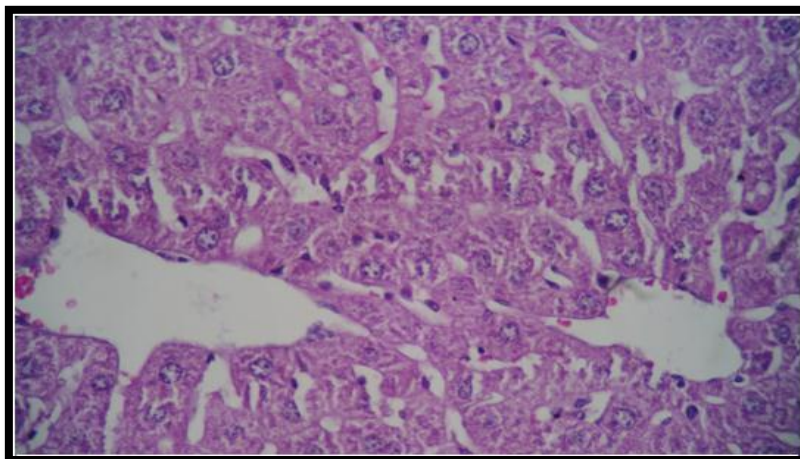


Fig:(7). Histopathological section in liver Immunized group with (5mg/ml)of bovine bile salts shows no clear pathological changes (H&E stain40x).

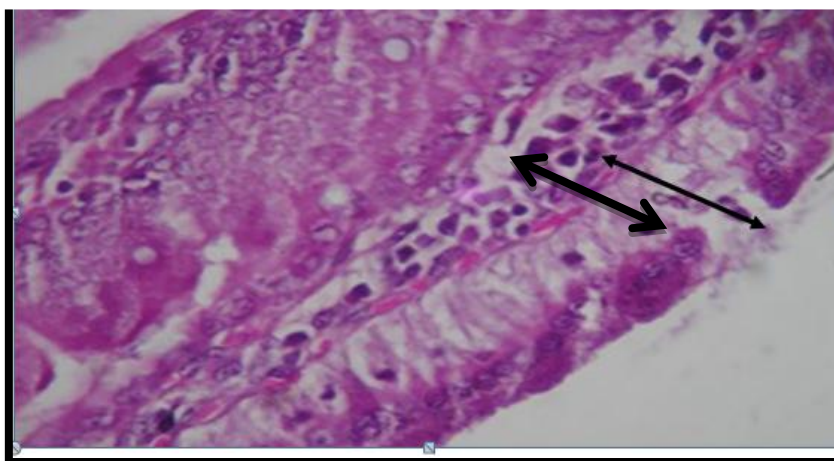
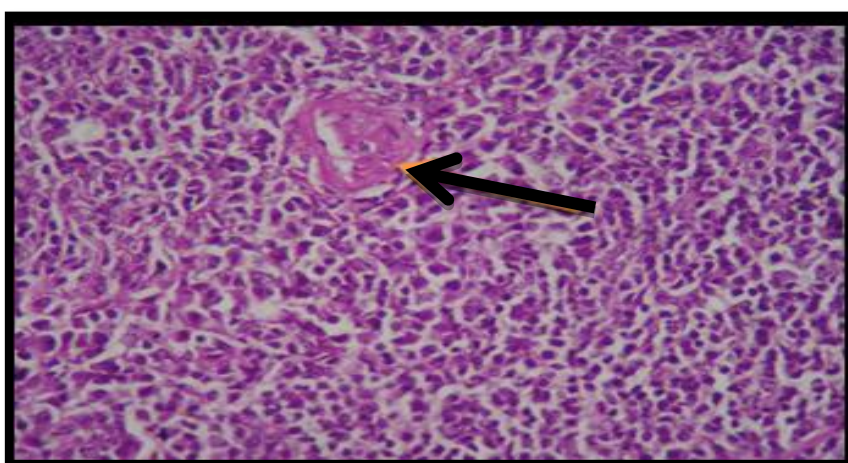


Fig:(8).Histopathological section in intestine Immunized group with (5mg/ml)of bovine bile salt shows sub mucosal MNCs infiltration associated with slight desquamation of intestinal mucosa. \longleftrightarrow (H&E stain40x).



"Fig(9).Histopathological section in the spleen of immunized deposition with slight megakaryocyte proliferation \leftarrow (H&E stain40x)."

concentration(5mg/ml). Also appearance of lymphoid hyperplasia in the spleen showed as a result to its persist stimulated by this antigen especially 1month post immunity which revealed a good immune response following bacterial infection which act as a mitogen stimulate lymphoid cell According to the above histopathological results of this group mainly histopathological findings in the spleen tissue could be related directly to the function of the spleen as a secondary lymphoid organ in which the recognition and presentation of non-self-antigens occurs (16 and 17).While It has shown that MNCs aggregation was in various tissue mainly with higher bile salts concentration with slight evidence of serious degenerative changes comparing to the other treated groups that revealed more degenerative histopathological changes mainly in the intestine tissue which showed slight desquamation.In our histopathological results there were MNCs aggregations, neutrophils infiltration in various tissues when these tissues were immunized by bile salts with two concentrations (3mg/ml) and (5mg/ml),these results similar with (18). Also disappearance of lesion in liver tissue which were immunized with bile salts specially in 5mg/ml of salts due to decomposition of bacteria with bile so this result agreed with (19 and 17) who observed that the fatty acids and the basic phosphatase found in bile play a role in protoscolices decomposition because of the influence of this enzyme on the chemical composition of protoscolices.

According to the above histopathological results of the first group (Non immunized infected animals group)mainly histopathological findings in the liver tissue showed necrosis, this lesion caused by factors external to the cell or tissue, such as infection, toxins, or trauma which result in the unregulated digestion of cell components. So the toxin of salmonella caused necrosis in this organ also this lesion lead to activation of MNCs aggregation to remove this necrotic tissue (12). lesions of the intestine after treatment with *S. typhimurium* orally characterized by hyperplasia of goblet cells, inflammatory cells in the lamina propria of atrophic villi and the result agreed with (13) that said *Salmonella typhimurium* causes gastroenteritis in humans and other mammals. When the bacterial cells enter epithelial cells lining the intestine they cause host cell ruffling which temporarily damages the microvilli on the surface of the cell.

As well as granulomatous lesion may also be seen in the examined organs of the second group (Oral immunized group with (3mg/ml) of bovine bile salts) this may be explained that host defense attempts to localize and destroy the invading bacteria through inducing proliferation and aggregation of phagocytic cells mainly alternative activated macrophage which produce cytokines IL-8 and IL-12 (14)

On the other hand the increase in number of megakaryocytes, which produce platelets that have antibody receptors, paralleled the increase in antibodies (15) These effects increased as the dose increased, especially in high bile salts

immunobiology of bile and biliary epithelium. *Hepatology*. 30:351–357.

8. Harada K, Ohba K, Ozaki S, et al.(2004) Peptide antibiotic human beta-defensin-1 and -2 contribute to antimicrobial defense of the intrahepatic biliary tree. *Hepatology* ;40:925–932.
9. Akira S, Uematsu S, Takeuchi O. (2006) Pathogen recognition and innate immunity. *Cell*. ; 124:783–801.
10. Karin M, Lawrence T, Nizet V.(2006) Innate immunity gone awry: linking microbial infections to chronic inflammation and cancer. *Cell*. ;124:823–835.
11. Flajnik MF, Du Pasquier L.(2004) Evolution of innate and adaptive immunity: can we draw a line? *Trends Immunol*. 25:640–644.
12. Proskuryakov SY, Konoplyannikov AG, Gabai VL; Konoplyannikov; Gabai (2003). "Necrosis: a specific form of programmed cell death?". *Exp. Cell Res*. 283 (1): 1–16.
13. Everest, P Julian Ketley, Simon Hardy, Gill Douce, Shahid Khan, Jacqui Shea, David Holden, Duncan Maskell And Gordon Dougan. (1999). Evaluation Of Salmonella Typhimurium Mutants In A Model Of Experimental Gastroenteritis. *Infection And Immunity*, Vol. 67, No. 6: 2815–2821.
14. Shallal, Z. sh.; Yousif, A.A. and Falih, I.B.(2013). Pathological

References :

1. Boyer, J.L. 2002. Bile Formation and Cholestasis. In: Schiff ER, Sorrell MF, Maddrey WC, editors. *Schiff's Diseases of the Liver*. Philadelphia: Lippincott, Williams and Wilkins; pp. 135–165.
2. Begley, M.; Cormac G.M. and Hill, C.(2004). The interaction between bacteria and bile. *EMS Microbiology Reviews* 29: 625–651.
3. Edgell, D. R., M. Belfort, and D. A. Shub. (2000). Barriers to intron promiscuity in bacteria. *J. Bacteriol*. 182:5281-5289.
4. Mikel, Ulrika V. 1994. Advanced laboratory methods in histology and pathology / Armed Forces Institute of Pathology. Washington, DC : Armed Forces Institute of Pathology, American Registry of Pathology.
5. Allen, K. ; Jaeschke, H. and Bryan, L. (2011). Bile Acids Induce Inflammatory Genes in Hepatocytes. *Am. J. Pathol.*, 178(1): 175–186.
6. Fiorucci, S. ; Mencarelli, A. ; Palladino, G. and Cipriani, S. (2009). Bile-acid-activated receptors: targeting TGR5 and farnesoid-X-receptor in lipid and glucose disorders. *Trends Pharmacol Sci.*;30:570-80.
7. Reynoso-Paz S, Coppel RL, Mackay IR, et al. (1999). The

17. Mardan ,A. U.(2004) .Study of the effect of temperature degrees and bile juice in *Echinococcus granulosus* infection M.Sc. Thesis. Vet. Coll. Uni.-Baghdad.
18. Aiello,S.E.;Mays,A.;Amstutz,H.E.; Anderson,D.P.;Armour,S.J.;Jeffcott, L.B.;Loew, F.M. and Wolf, A .M. (1998). The Merk veterinary Published by Merk and Co.,Inc. White House Station N.J.,USA;1196-1197.
19. Tennant, B.C and Hornbuckle, W.E. (1980). Gastrointestinal function. In: Clinical Biochemistry of domestic animals. Kaneko, J.J (ed.)Academic press, New York:283-337.
20. changes in some internal organs of mice infected experimentally with *Salmonella mbandaka*. International Journal of Advanced Research . 1:(7) 249-255.
15. Hanada, K.; Kumagai, K.; Yasuda, S.; Miura, Y.; Kawano, M.; Fukasawa, M.and Nishijima, M. (2003). Molecular machinery for non-vesicular trafficking of ceramide. Nature. ,426:803–809.
16. Rogan, M.T. (1998).T-cell activity associated with secondary infections and implanted cysts of *Echinococcus granulosus* in BALB/c mice. Parasite Immunol., 20: 527-33.