

One stage vs. two stages septorhinoplasty for correction of deviated nose.

Assist. Prof. Dr. Salim H. Ibrahim, MBChB, DLO, FICMS(ENT).

Abstract

One -stage septorhinoplasty is standard technique for correction of deviated nose, but still two stages technique are used. This study compare septal complications and functional outcomes between septorhinoplasty and first stage only septoplasty, and study the surgical approaches for second stage (rhinoplasty)for correction of deviated nose (patients with previous septoplasty). A retrospective case study of 110 patients with deviated nose underwent endonasal septorhinoplasty in the Tikrit Teaching Hospital during 6 years period . 72 male and 38 female, mean ages was 26 years. The patients divided into two groups:

A. Patients with one-stage septorhinoplasty, were 97 patients

B. Patients with septoplasty (first stage), were 13 patients.

The surgical steps for correction of deviated nose in the patients with septoplasty was studied. Follow up of the patients for a minimum 6 months for the septal condition and functional outcomes. The results founds the late complications of nasal septum are less in one-stage septorhinoplasty than in only septoplasty. Septal perforation were (2%), (23%) respectively. Failure of septal correction (8%), (31%), nasal saddling and columellar retraction (4%), (23%), intranasal adhesions (1%) ,(15%) respectively. Functional improvement in one stage septorhinoplasty (92%), in only septoplasty (69%). Second stage for patients with previous septoplasty, 6 patients was done for them rhinoplasty with limited dorsal septal dissection, five do septorhinoplasty, and two needs augmentation rhinoplasty. conclusions: One -stage septorhinoplasty procedure gives better functional results and less septal complications than only septoplasty as first stage, which made subsequent rhinoplasty more difficult.

Key words: One stage septorhinoplasty. Deviated nose. Setorhinoplasty. Septoplasty, Septal perforation.

Introduction

Septoplasty is techniques to correct the deviated nasal septum to improve breathing and rhinoplasty is techniques to correct the external nasal deviations to straighten the nose. Each technique can be done separately for deviated nose; however the one stage septorhinoplasty has become the standard line of management for deviated nose 1, 2, 3. The surgeon requires thorough knowledge of nasal anatomy and experience with both septoplasty and rhinoplasty 4.

The correction of deviated nose still doing in two stages, when the otorhinolaryngology surgeon have no experience with rhinoplasty or the plastic surgeon have no experience with septoplasty. Septoplasty or rhinoplasty alone is not sufficient to fix a crooked nose. As in the deviated nose, the inside and outside of the nose are intimately connected. The two stage septorhinoplasty increase the number of surgery the patient exposed, so the recovery, healing time, hospital stay and the cost will be increased.

Patients and methods

A retrospective case study of 110 patients with deviated nose underwent endonasal approach septorhinoplasty in the Tikrit Teaching Hospital during the period from Jun.2008-Jun.2014. History of patient's age, sex, asking for aesthetic or functional correction or both, history of nasal trauma, previous nasal surgery, nasal obstruction. Patients with history of septoplasty asked the date of surgery, post operative changes in the nasal shape(saddling), improvement of nasal obstruction, nasal crustation and epistaxis.

Inspection for type of external nasal deviations, nasal dorsum (hump, saddling), nasal tip and nostril asymmetry, columellar retraction, caudal dislocation. Palpation for dorsal nasal support. Anterior rhinoscope for septal deviation, septal perforation, intranasal adhesion, turbinates, nasal valve area,....

The patients divided into two groups.

A. Patients with one-stage septorhinoplasty, were 97 patients

B. Patients with previous septoplasty, were 13 patients.

The surgical approaches for correction of deviated nose for patients with previous septoplasty were studied.

Follow up of the patients for a minimum 6 months for the septal condition and functional outcomes.

Results

From 110 patients with deviated nose underwent endonasal approach septorhinoplasty. Male were 72 (65%), and female were 38 (35%). The mean age was 26 ranging from 18-42 years. Ninety-seven patients (88%) one-stage septorhinoplasty done for them and 13 patients (12%) have history of only septoplasty by other surgeons.(Figure 1).

The late complications for patients with one-stage septorhinoplasty are septal perforation 2 patients(2%),failure of septal correction 8 patients (8%),Nasal saddling and columellar retraction were 4(4%),intranasal adhesions 1(1%).

Patients with only septoplasty. Septal perforation in 3 patients(23%),failure of septal correction 4 (31%), nasal saddling and columellar retraction (worsen the external deviation) were 3 patients (23%),intranasal adhesions2 (15%). (Table 1.and Figure 2).

The surgical approaches for second stage septo rhinoplasty for patients with previous septoplasty, were done at least nine months after first stage (septoplasty). From 13 patients, 6 patients (46%) do rhinoplasty with limited dorsal septal dissection. (Two patients having large perforation to avoid further enlargement .and 4 patients have uncorrected upper dorsal deviation).For those patients dissection of dorsal part of the septum to the level of hump removal, with submucosal tunnel and separation of upper lateral cartilage from septal cartilage. Then dehumping and lateral percutaneous osteotomies and in-fracture of nasal bones.

Five patients (38.5%) do revision septorhinoplasty because of failure of septal correction, the sites of deviations was dorsal and posterior part of the septum.

Two patients (15.5%) do augmentation rhinoplasty (Table 2).

The complication only septal perforation in one case from 10 patients (10%), in patients with previous septoplasty without perforation.

Functional results in one stage septorhinoplasty functional improvement in 89 patients (92%), in

only septoplasty 9 patients (69%) (Table 3).

Discussion

Deviated nose common in male patients (65%) in this study, because young men are twice likely to sustain fracture nose than women, as personal assaults and contact sports are more common. The septal deviation in the deviated nose usually severe especially in type C-shape and S-shape nasal deviation, because there are complex septal deviation with obvious dorsal osteocartilagenous deformities. So requires aggressive septal surgery than that for standard aesthetic rhinoplasty 6,7.

The septal cartilages and bones removed which weakened the septum and limit dorsal supports results in aesthetic complication like dorsal saddling, columellar retraction, and loss of tip projection occurs during operation or post operatively 8,9. The severe vertical and horizontal angulations of the nasal septum which commonly traumatic causes made the dissection extensive and difficult that violating the integrity of septal mucosa causes tearing and septal perforations which is common. In our study nasal saddling and columellar retraction in one stage septorhinoplasty were (4%), and in patients with previous septoplasty were (23%). In different studies the frequency of aesthetic deformities after septoplasty varies from (0-13%) 10, (1%) 11, and (21%) 8.

The septal perforations were 2% in one stage septorhinoplasty, and (23%) in only septoplasty, and in rhinoplasty follow septoplasty one patient from 9 patients (11%). studies founds septal perforations in septoplasty not in deviated nose was (8%) 12, (5%) 11.

The functional improvement in one stage operation (92%) which better

than only septoplasty (69%), because the failure in septal correction is more in only septoplasty than one stage septorhinoplasty (31%) and (8%) respectively.

In one stage septorhinoplasty get better septal correction than septoplasty alone because of

1. In rhinoplasty for deviated nose the complete mobilization and separation of septal cartilage from all its attachments is important in correction of deviated nose, especially the separation of upper lateral cartilage from septal cartilage 13, this made the correction of nasal septum easier and decrease risk of septal perforation.

2. Dehumping also help in reduction of dorsal deviation.

3. Medial and lateral osteotomy also help to straighten the external deviation and the nasal septum.

4. Septal centering and pyramidal correction in one-stage septorhinoplasty produce better airway 2.

The rhinoplasty after septoplasty (second stage of septorhinoplasty) is challenging and potentially more complicated procedure, as the presence of septal perforation and weak septum increasing risk of septal perforation, augmentation rhinoplasty, and long duration time of the operation. Revision septoplasty may require trimming and repositioning the bone and cartilage of the septum a second time and needs skilled surgeon. The septum is source of transplant material for augmentation or spreader graft in rhinoplasty when septoplasty below the area of scarring is created which bears on subsequent rhinoplasty because hump removal and transfixation bring us in to contact with the septum 2. This limit later rhinoplasty and remove of the dorsal hump would open in to excised area of nasal septum 9, specially when there is septal perforation, causes nasal

saddling needs augmentation rhinoplasty. Augmentation rhinoplasty was done for two cases (15.5%), they have dorsal saddling, columellar retraction, and loss of tip projection, one with septal perforation, using onlay dorsal graft and columella strut 13, one case used auricular graft as onlay dorsal graft, and vomer bone and remaining septal cartilage graft for columella strut. (Table 3. Figure 3). Full examination to show how much septal structure has been changed or removed during previous septoplasty by palpation, probing, and even CT scan is important.

Conclusion

1. One stage septorhinoplasty procedure gives better functional results and less septal complications than only septoplasty as first stage in correction of deviated nose.
2. The only septoplasty made subsequent rhinoplasty more difficult and challenging operation.

References

1. Hossamm M. T. Foda. Management of deviated nose, Plastic and reconstructive surgery, Vol. 115, No. 2; 2005).
2. Graeme M. Clark. The role of the nasal septum in one-stage rhinoplasty. Arch Otolaryngol. 1967; 85(4): 418-423.
3. David Bernstein, septal surgery in rhinoplasty. Bull. N. Y. Acad. Med. Vol. 57, No. 4, May 1981.
4. Assem H. Kamel, Mohamad A., et al; State of art in management of the twisted nose. Egypt, J. Plast. Reconstr. Surgery., Vol. 29, No. 1, January: 13-19, 2005.
5. Brent a Mcmonagle and Michael Gleeson. Nasal fractures. Chapter 127. Scott-Brown's Otorhinolaryngology, Head and neck surgery. Vol. 2. Seventh edition. Edited by Michael Gleeson. 2008; P: 1610-1617.
6. Salim H. Endonasal septorhinoplasty for correction of deviated nose. The patient's evaluation of the results
7. Francisca Yao, et al. Effect of midfacial asymmetry on nasal axis deviation. Arch Facial plast. surgery. 11(3): 157-164, 2009.
8. H. D. Vuyk. Aesthetic sequelae of septoplasty. Clin. otolaryngol. 22, 226-232, 1997.
9. Martyn Mendelson, Straightening the crooked middle third of the nose. Arch Facial Plast surg; 2005; Vol. 7: 74-80.
10. Phillips J. J. The cosmetic effects of submucosal resection. Clin. otolaryngol. 16, 179-181, 1991.
11. Muhammad IA, Nabil-ur Rahman. Complications of surgery of deviated nasal septum. J Coll Physician Surg Pak. Oct; 13(10): 565-8, 2003.
12. Marco Aurelio, Et al. perforation of nasal septum; Etiology and diagnosis. International archives In otorhinolaryngology. Vol. 14 Num. 4; 2010
13. H. D. Vuyk. A review of practical guidelines for correction of the deviated, asymmetric nose. Rhinology, 38, 72-78, 2000.
14. Hong-ryul Jin, et al. Management of combined deviated and saddle nose. otolaryngology-head and neck surgery, 139: p31, 2008.

Table (1): Late complications of One-stage septorhinoplasty and only septoplasty in deviated nose.

Complications	No.of patients	Septal perforation	Failure of septal correction	Intranasal adhesion	Nasal saddling	Columellar retraction
One-stage septorhinoplasty	97 (88%)	2(2%)	8(8%)	1(1%)	4(4%)	4(4%)
Only septoplasty	13 (12%)	3(23%)	4(31%)	2 (15%)	3(23%)	3(23%)

Table (2): Surgical approaches for correction of deviated nose for patients with septoplasty (second stage).

Surgical approaches	No. (%)
Rhinoplasty with limited dorsal septal dissection.	6 (46%)
Septorhinoplasty	5 (38.5%)
Augmentation rhinoplasty	2 (15.5%)
Total	13 (100 %)

Table (3): The functional improvement in one-stage Septorhinoplasty and only septoplasty.

Procedure	No.(%)	Functional improvement
One stage septorhinoplasty	97(88%)	89(92%)
Only Septoplasty	13(12%)	9(69%)

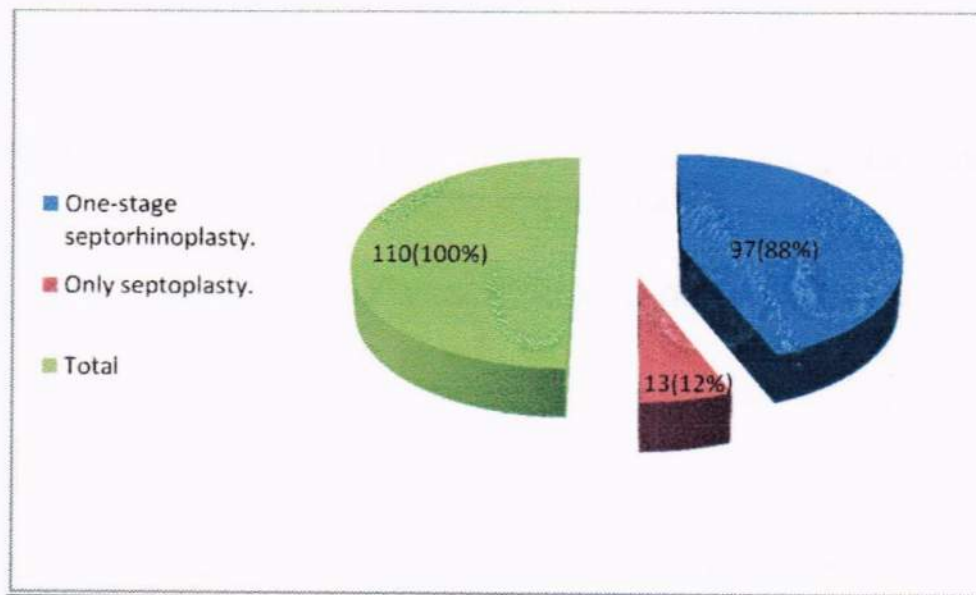


Figure (1): Pie chart for No. of patients with one- stage septorhinoplasty and with only septoplasty(First stage).

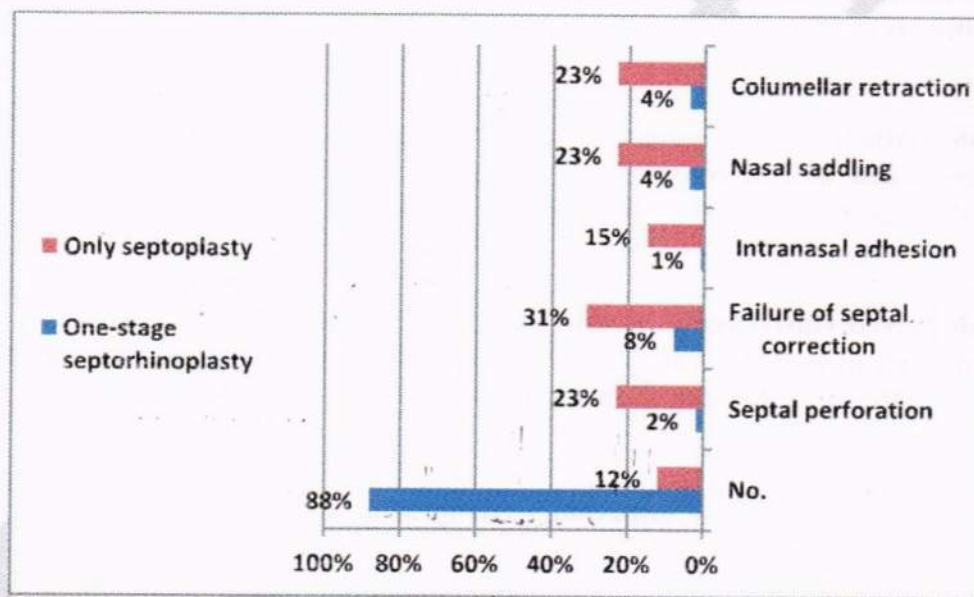


Figure (2): Bar chart for compare the late complications of one-stage septorhinoplasty and only septoplasty.