



Gross and histological features of thyroid gland in adult male one humped camel *Camelus dromedarius* in AL-Muthanna province

Ali Oday Hatem

Khalid Hadi Kadhim

Department of the Anat. and Histol./ Colla. of Vet. Med./ University AL-Muthanna / Iraq

Email; dr-kh8195@ mu.edu.iq

Received on 28/12/2024 Accepted on 22/4/2025 Published on 30/6/2025

Abstract

This study aimed to focus light on the histomorphometry structure of the camels' thyroid glands. For this study, 15 adult male camels were used. Grossly: The thyroid gland was made up of two long, oval lobes near the sides of the trachea that were connected from the ventral side by an isthmus runs along the ventral edge of trachea near the level of the second and third rings. It was situated behind the larynx. The thyroid gland's right lobe was situated on the dorsomedial side of trachea, which ran from the first to the eighth rings. On the medial side of the trachea, the left lobe was situated between the second and sixth to seventh rings. The trachea was attached to the medial portion of the lobes. They have convex lateral surfaces. Additionally, the lobes' ventral and dorsal borders were convex. Histologically; The thyroid gland was divided into different lobules by the penetration of the trabeculae from the collagenous connective tissue capsule that encloses it. Follicles were create the lobules, which differ in size and shape. Large follicles were dormant and found in the gland's periphery, whilst small follicles were active and found in the gland's center. The follicles came in a variety of forms and sizes, including oval, irregular, circular, and polygonal. The vascular bed of the gland's central regions is larger than that of its outer regions. According to this study, the thyroid gland of camels contains parafollicular cells, the majority of which are found in the gland's center. These cells are far less

numerous than the follicular cells and were more frequently found in the spaces between the gland's tiny follicles. Colloid was abundant inside the follicles, and these cells are infrequently found in the gland's periphery. The activity of the central tiny follicles was compatible with the well-developed loose connective tissues and vascular bed in the gland's center. **Conclusion,** With a few exceptions, the camel's thyroid structure was similar to that of large ruminants. It had a thin capsule, only two types of follicular cells; parafollicular cells were very few, and a different type of colloid. All of these factors helped the camel adapt to hot, dry, and unfavorable climates.

Key words: camel, thyroid gland, follicles, follicular cells parafollicular cells

Introduction

Unlike animals that dwell in temperate regions, camels are ruminants that are suited for hot, dry, and unfavorable environments. This animal can concentrate its pee without getting sick, and it may lose 25% of the weight of its body (1). A camel's body temperature fluctuates greatly. In hot temperatures, the endocrine system is responsible for stabilizing the camel's internal conditions, and the thyroid gland affects numerous organs, as heart, kidneys and liver (2,3). The thyroid gland is the first endocrine organ to form, which is normally found on the ventrolateral side of trachea in mammals, is made up of two lobes joined by a thyroid tissue bridge (4,5). In the area of first pharyngeal pouch, the endoderm from the primitive pharynx develops ventrally. As the thyroid gland grows, the thyroglossal duct recedes, causing it to migrate caudally towards the neck and separate from the oral

cavity's floor (6). The thyroid goes through a migration process before birth, moving from its original location close to the back of tongue to the front of the neck. According to the thyroid gland's histology, each lobule is made up of a collection of follicles that serve as the gland's structural and functional element. A follicle is made up of follicular cells called thyrocytes and a relatively solid substance called colloid. Numerous body organs are impacted by the thyroid, a crucial endocrine gland. (7,8). The hormones Triiodothyronine and tetraiodothyronine are produced by follicular cells in the thyroid gland, while calcitonin hormone is produced by parafollicular cells. These hormones have a significant impact on animals' metabolism (9,10). More recently, there has been a focus on analyzing the processes via which thyroid hormone enhances heat output. Because thyroid hormone stimulates many metabolic

processes involved in tissue formation, remodeling, and energy delivery, it raises obligatory thermogenesis. Furthermore, certain thermogenic mechanisms that were chosen throughout the evolution of homeotherms (such as muscle Ca²⁺ cycling and Na/K-ATPase) may be specially stimulated by thyroid hormone. Additionally, thyroid hormone interacts with sympathetic nervous system on multiple levels and is crucial for facultative thermogenesis. Thyroid hormone increases the SNS's effects at adrenergic receptors and adenylyl cyclase complex levels in the periphery (11,12). Only a few studies have been conducted on the properties of this camel gland. In order to provide information for further research, the purpose of this study is to examine the morphological characteristics and histological structure of the thyroid in adult one-humped camels.

Materials and method

Animals: The study used 15 healthy adult male one-humped camels *Camelus dromedarius*, aged 6-7, who were gathered at a slaughterhouse in the AL-Muthanna district. The thyroid glands inherit their gross and histological characteristics from these species. Seven 1 cm³ samples were collected for histological examination from

various regions of the thyroid gland lobes and isthmus (5).

Histological methods: many stains used Hematoxylin and Eosin (H&E) for histological features, Masson's trichrome for muscles and collagen fibers, Verhoef for elastic fibers and toluidine blue for parafollicular cells (13).

STATISTICAL ANALYSIS; The study was examined at the 5% significant levels using one-way analysis of variance (ANOVA) tests. Social science statistical approaches were used to process and regulate the data (14).

Results and discussion

The camel's thyroid gland was situated behind the larynx and was made up of two lateral lobes that were oval in shape and connected to the ventral surface by a clear non-glandular isthmus that ran along the ventral surface of trachea on the level of the second and third rings (Fig.1,2). This is comparable to other large animals, such as buffaloes, goat, donkey, sheep and cattle (15-24). The gland had a reddish-brown appearance (Fig.3) which is consistent with the results of (25,26). The thyroid gland's right lobe was situated on the dorsomedial side of the trachea, which ran from the first to the eighth rings. On the medial aspect of trachea, the left lobe was situated between the second and sixth to seventh rings. The

trachea is attached to the medial aspect of lobes. They have convex lateral surfaces. Additionally, the lobes' dorsal and ventral borders are convex (Fig.1), these like other domestic mammals (15,27). Mean length, weight and thickness of left and right lobes of thyroid gland were (8.9 ± 0.5 cm; 3.5 ± 0.1 gm; 1.7 ± 0.1 cm) (8.6 ± 0.1 cm; 3.2 ± 0.3 gm; 1.5 ± 0.1 cm) respectively.

The thyroid gland is divided into different lobules by the penetration of the trabeculae from the collagenous connective tissue capsule that encloses it. The follicles that make up the lobules vary in the size and shape, The study's findings demonstrate that a thin capsule encloses the thyroid gland (Fig.4,5). These characteristics are present in camels as well and align with findings (26). In contrary to the study of (27) stating that the camel's thyroid gland capsule is thick. In contrast to other domestic mammals, camels have small (active) follicles at the core of the gland and vast (inactive) follicles in the periphery (Fig. 6,7,8). The endocrine system controls the camel's internal health in warm, arid climates, and the thyroid has an impact on numerous body organs, Thyroid dysfunction during summertime dehydration lowers basal metabolism and pulmonary water loss, which helps keep the water level (27,28). The follicles within the gland's core and peripheral regions appear to be arranged

in a particular way, which helps the animal adapt to the hot, dry climate of the deserts. Despite the fact that this disease has been noticed, researchers like (26,27) who have previously examined the thyroid gland of camels have not reported it. Similar to other domestic mammals (5,6,28,29), the thyroid gland of camels has cuboid cells that form the follicle wall and colloid inside the follicles. The findings of (8,30) are in agreement with these results.

A narrow capsule of dense, connective tissue, which contained numerous thin collagen fibers, encircled the thyroid glands. A few trabeculae were forming some irregular lobules when they penetrated the gland from the capsule. A variety of follicles of various sizes and shapes made up each lobule. Between the follicles were thin collagen fibers, blood capillaries, and a large number of fibroblasts, each follicle was encased in an epithelium that ranged from low columnar to simple cuboidal. As a uniform eosinophilic colloid, the secretion was kept in the follicles. The cells were all the same size within each follicle. Two sets of follicles were created based on their size. The gland's center region had small follicles, whereas the periphery contained large follicles, While the epithelium of tiny follicles varied from cuboidal to low columnar, the epithelium of large follicles

contained low cuboidal to squamous cells. Large follicles had a thick, fully acidophilic colloid, whereas small follicles had a thinner, more homogeneous colloid. The cuboidal follicular cells, which make up the majority of the gland's cell population, have cytoplasm that is comparatively basophilic. On the base of cells was a sizable nucleus. active follicular group was being formed by small follicles with vacuoles inside the colloid (Fig. 4,9,10,11), these like results of (26). This study demonstrated that C cells are present in the camel's thyroid gland (Fig. 4,11), despite previous research claiming that they are absent from the camel's thyroid (26). Compared to follicular cells, these cells tint paler. They are situated in between the follicles and are also bigger and brighter than follicular cells. Because of the extensive vascular bedding in the middle region of the gland, these cells are much less numerous than follicular cell and is more frequently observed between the tiny and active follicles. Seldom do these cells exist in the gland's outer regions. It was additionally reported by (30) that the thyroid gland of camels contains ultimobranchial structure.

The para follicular cells inhabit a tiny number of thyroid cells and are seen in mammals including horses, dogs, and cats as light, pale cells that lie between follicles and

follicular cells. These cells, are classified as Amine Precursor The absorption and Decarboxylation cells in the neuroendocrine system, secrete the hormone "calcitonin," which is essential for preserving calcium homeostasis. High blood calcium concentrations cause the release of calcitonin, which inhibits bone resorption to sharply reduce the concentrations (31,32,33). There were very few parafollicular cells present. These cells, which were frequently observed singly between follicles, were larger and stained lighter than follicular cells. The majority of these cells are located in the gland's central region, where they are more frequently observed in the small and active follicles because of the extensive vascular bedding there. These cells are infrequently found in the gland's outer regions. Cuboid cells make up the follicle wall, and the interior of follicles was filled with colloid that reacts favorably to Masson stain (Fig. 6), The follicles' lumen included colloid material, which was most likely an apocrine release from the cells that line them (34).

(35) given that hypothyroidism and hyperthyroidism cause both elevated and reduced body temperatures. thyroid hormone also has a significant impact on thermoregulation. Significant alterations in the energy metabolism of the entire body are

linked to thyroid hormone abnormalities. Thermogenic brown adipose tissue is a primary target of thyroid hormones, and it can be activated both directly by thyroid hormone receptors expressed in the brown adipocytes and indirectly by thyroid hormone receptors expressed in hypothalamic neurons (36-39). Statistical analysis refers to significant differences between left lobe, right lobe and isthmus, and right lobes was more than other parts in all measurements (Table 1). (8) demonstrated how the thyroid gland influences an animal's ability to withstand bad weather. Thermoregulation is a vital homeostatic

process in which the hypothalamus plays a major central role in controlling vital mechanisms of the heat production as well as dissipation, while the sympathetic nervous system is activated on a peripheral level. Both adaptive thermogenesis via shivering and non-shivering processes and mandatory thermogenesis generated by body metabolism occur during cold exposure. The latter mostly happens in muscle and brown adipose tissue, but adrenergic stimulation can also cause white adipose tissue to brown in order to develop thermogenic potential.

Table, (1): Measurements each of lobes of thyroid gland and isthmus of camel, μm

Measure Part	Capsule	Large follicles	Small follicles
Left lobe	499.1 \pm 0.3A	141.5 \pm 0.7A	58.3 \pm 1.7A
Right lobe	552.3 \pm 0.2A	150.3 \pm 0.5A	61.4 \pm 1.1A
Isthmus	482.1 \pm 0.1A	119.8 \pm 0.7A	52.3 \pm 1.7A

Values with capital letters in same columns denote to significant differences ($P > 0.05$)

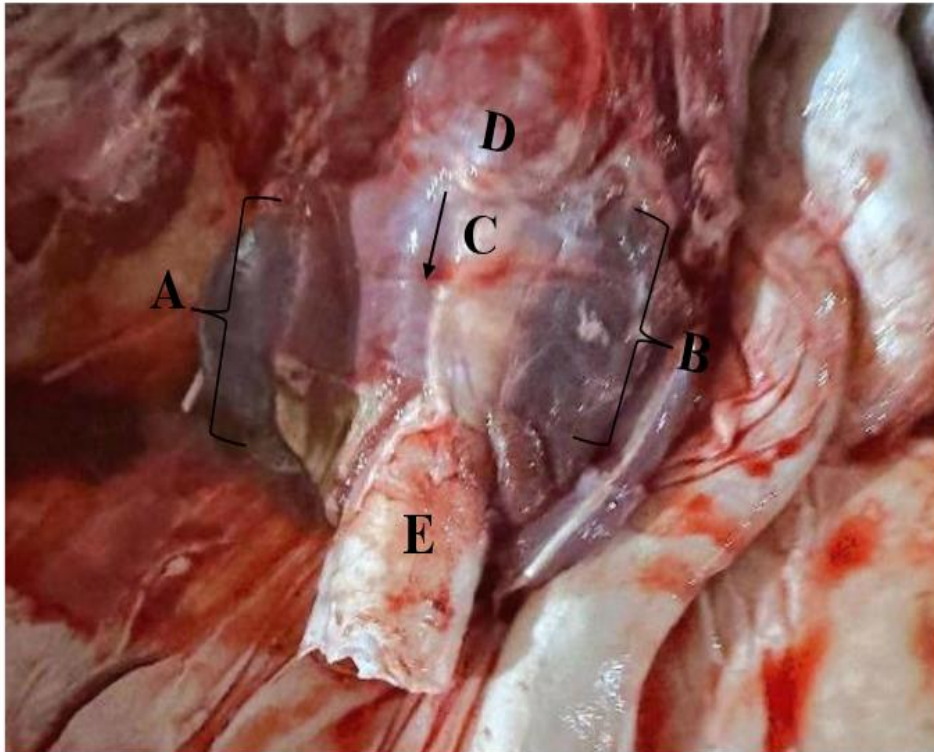


Fig (1): gross section; Shows the location of thyroid gland in adult camel: A- Right lobe, B-Left lobe, C- isthmus, D- larynx. E- trachea

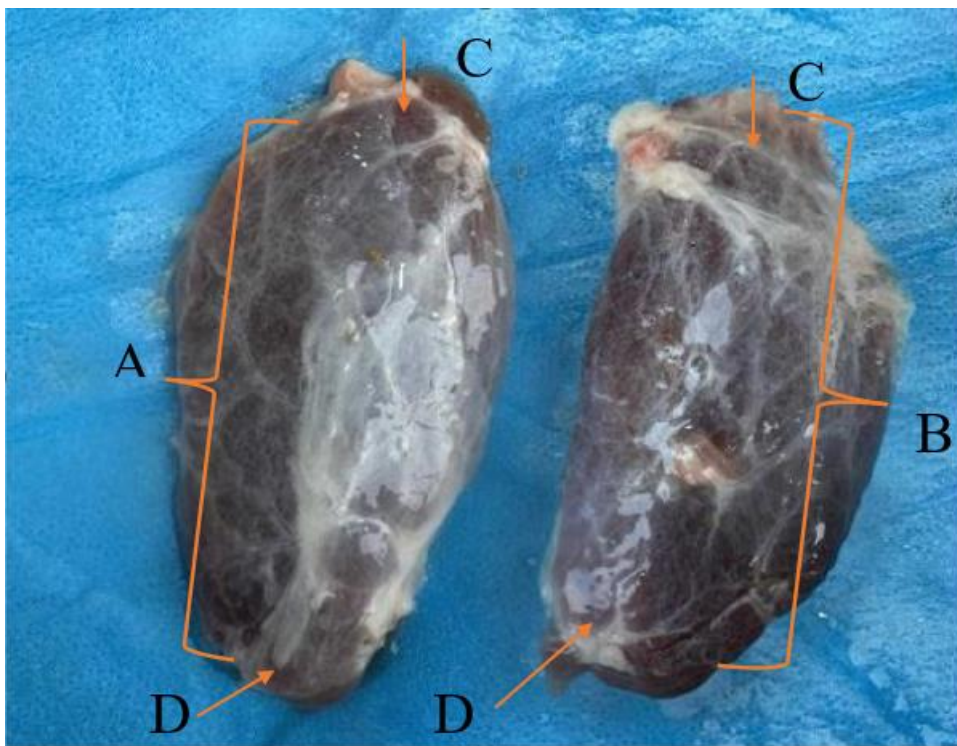


Fig (2): gross appearance; Shows the shape of thyroid gland lobes in adult camel: A- Right lobe, B-Left lobe, C-cranial extremity, D- caudal extremity

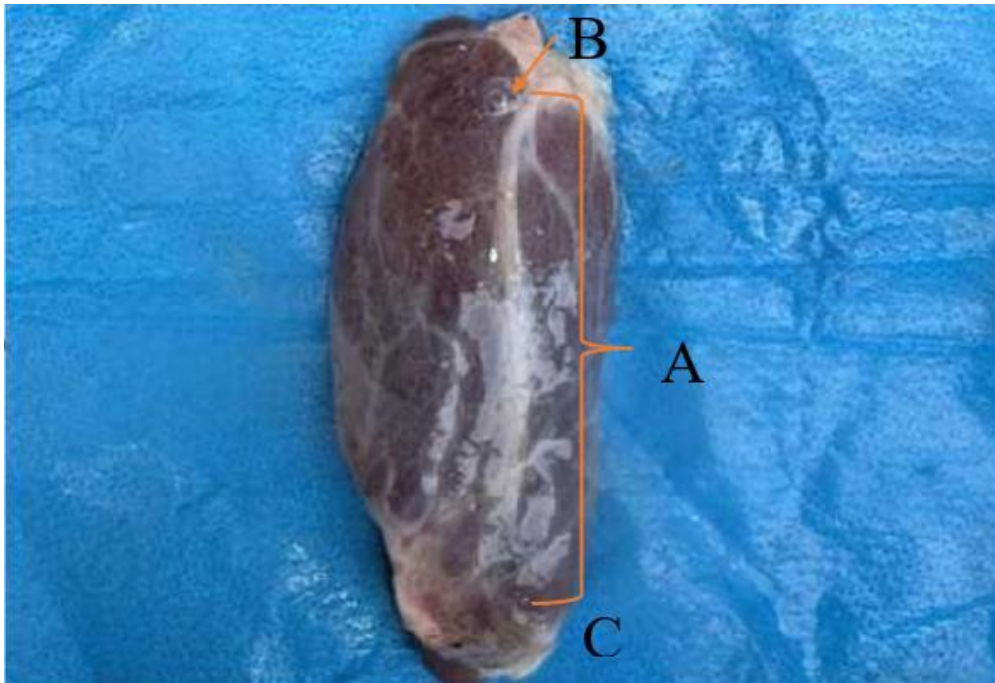


Fig (3): Shows the shape of right lobe of thyroid gland in camel: A- Right lobe, B-cranial extremity, C- caudal extremity

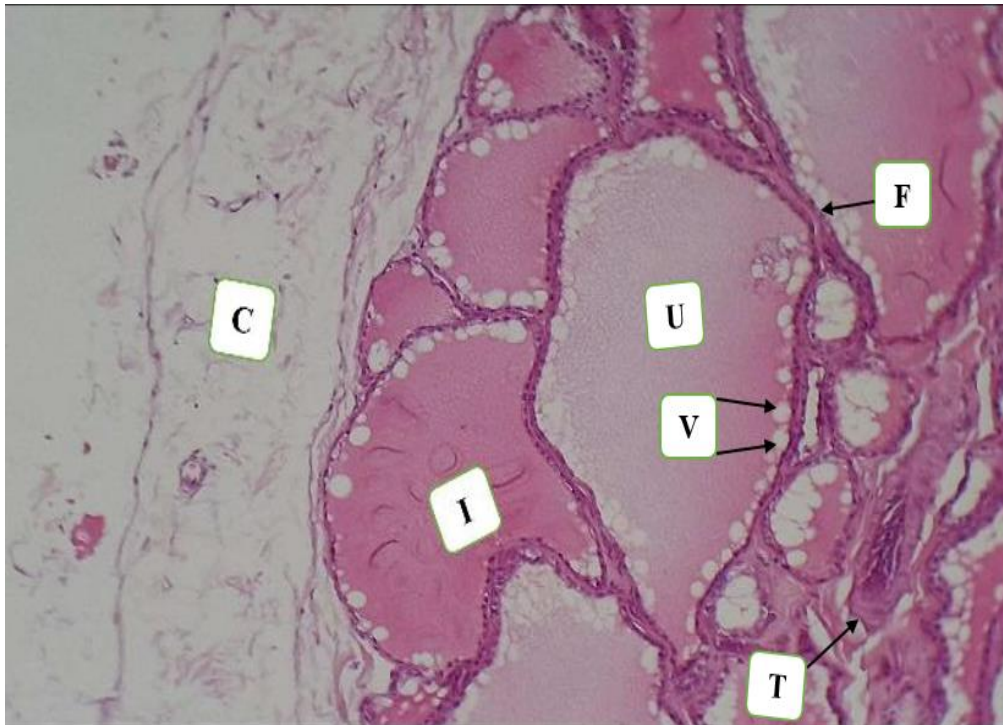


Fig.4. longitudinal Microscopic section of the right lobe of thyroid gland in camel shows the : C. Capsule, F. Follicular cells, I. irregular follicle, T.Trabeculae ,U. Colloid V. vacuole H&E stain X100

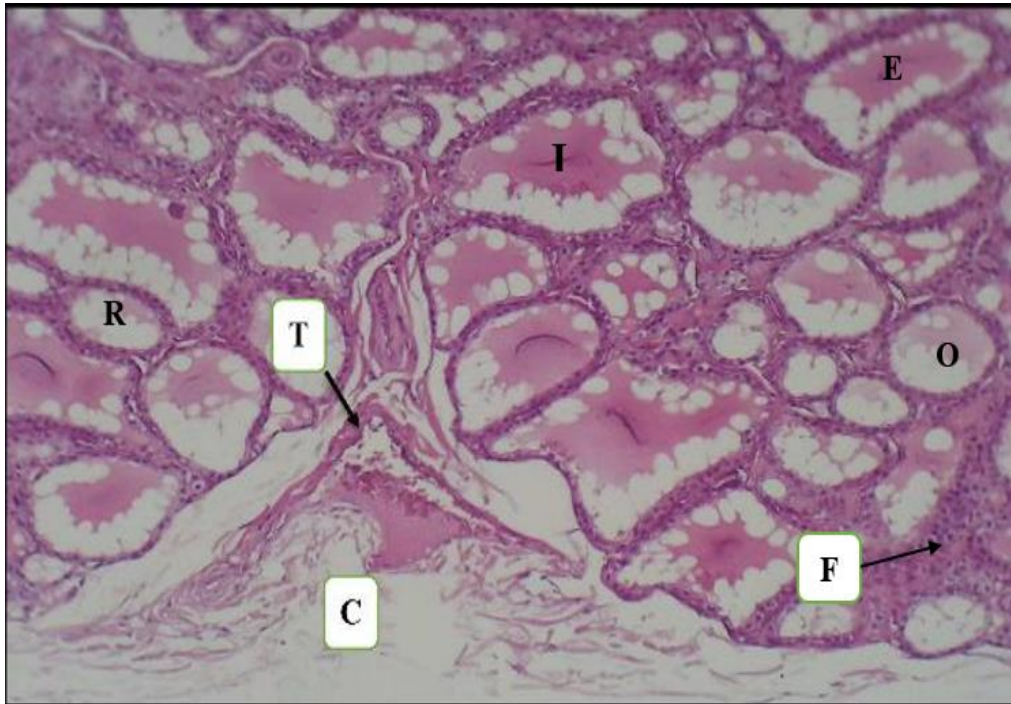


Fig.5. Cross Microscopic section of the left lobe of thyroid gland in camel shows the : C. Capsule, E.Elongated follicle F. Follicular cells, I.Irregular ,O. Oval follicle, R.Round follicle, T. Trabeculae H&E stain X40.

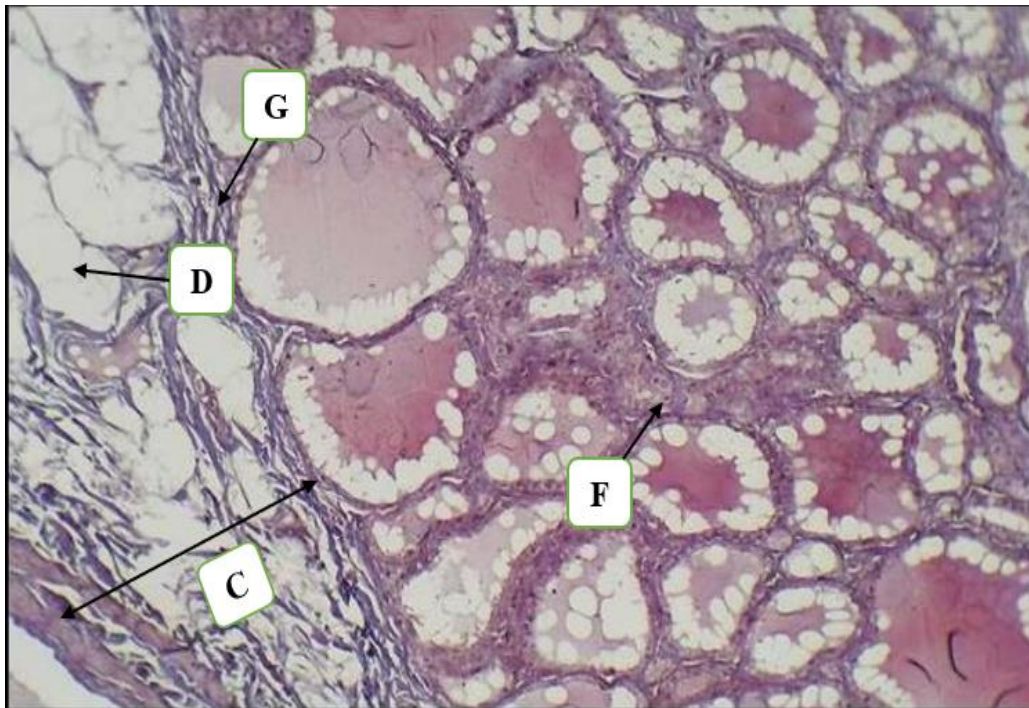


Fig.6. longitudinal Microscopic section of the right lobe of thyroid gland in camel shows the : C. Capsule, D.adipose tissue F. Follicular cells, G. Collagen fibers,. Masson stain X100

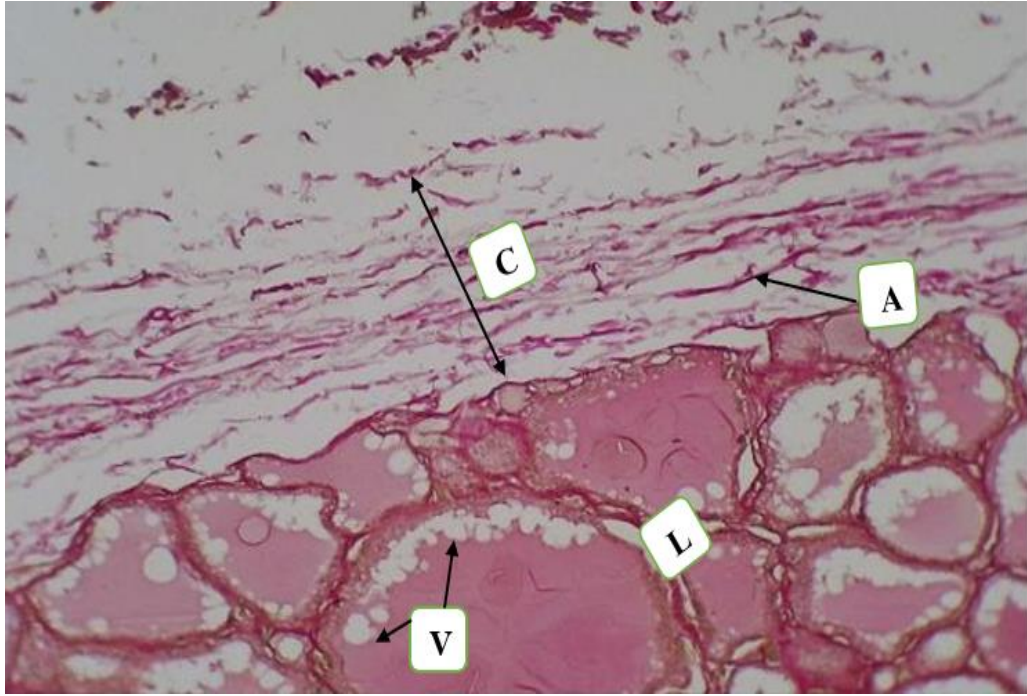


Fig.7. longitudinal Microscopic section of the right lobe of thyroid gland in camel shows the : A. Elastic fibers, C. Capsule, , L. Thyroid lobule, V. vacuole . verhoof stainX100

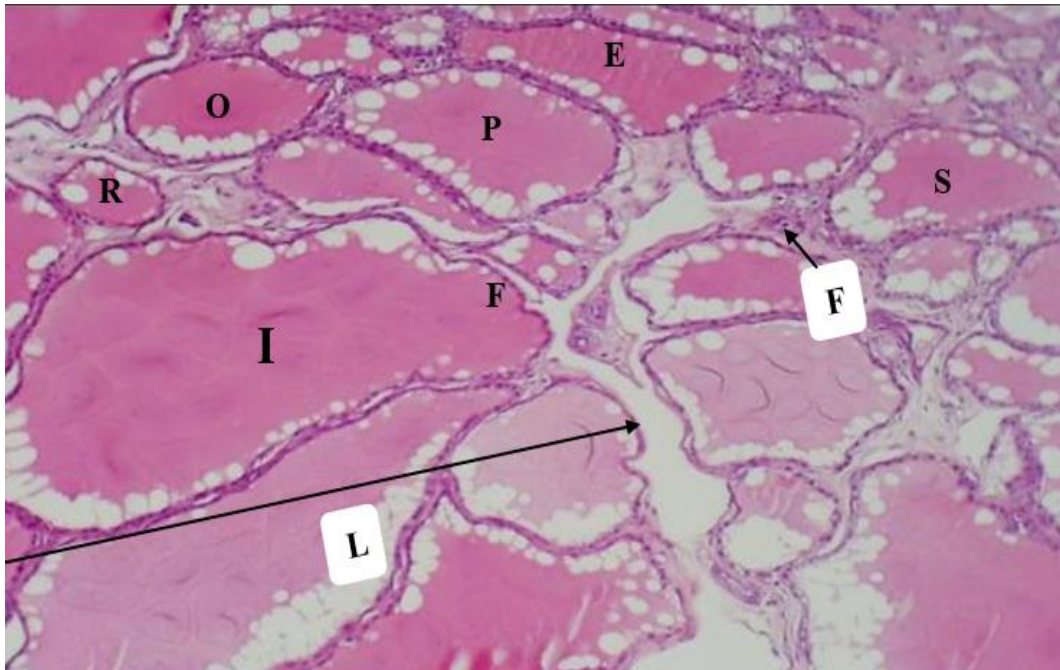


Fig.8. Cross Microscopic section of the right lobe of thyroid gland in camel shows the : E.Elongated follicle, F. Follicular cells, I. Irregular shape, L. Lobule, ,O.Oval follicle, P.Polygonal follicle ,R.Round follicle,S.Spherical follicle H&EX100

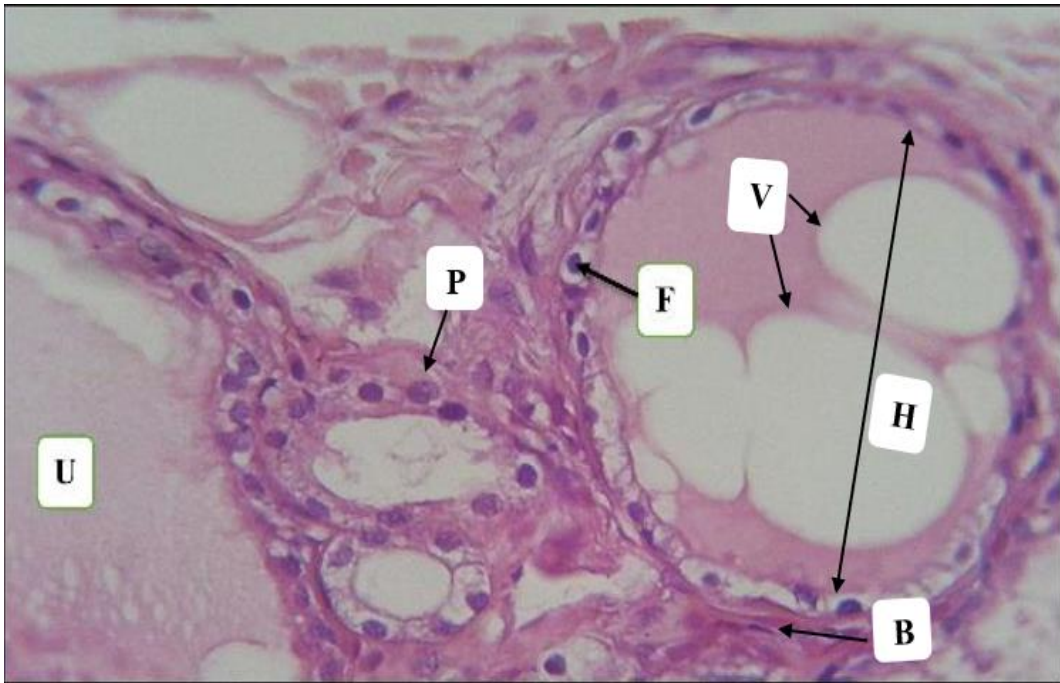


Fig.9. Cross Microscopic section of the left lobe of thyroid gland in camel shows the : F. Follicular cells, V. vacuole U. Colloid,H.Thyroid follicles,B. Fibroblast,P. Para follicular cell H&E X400.

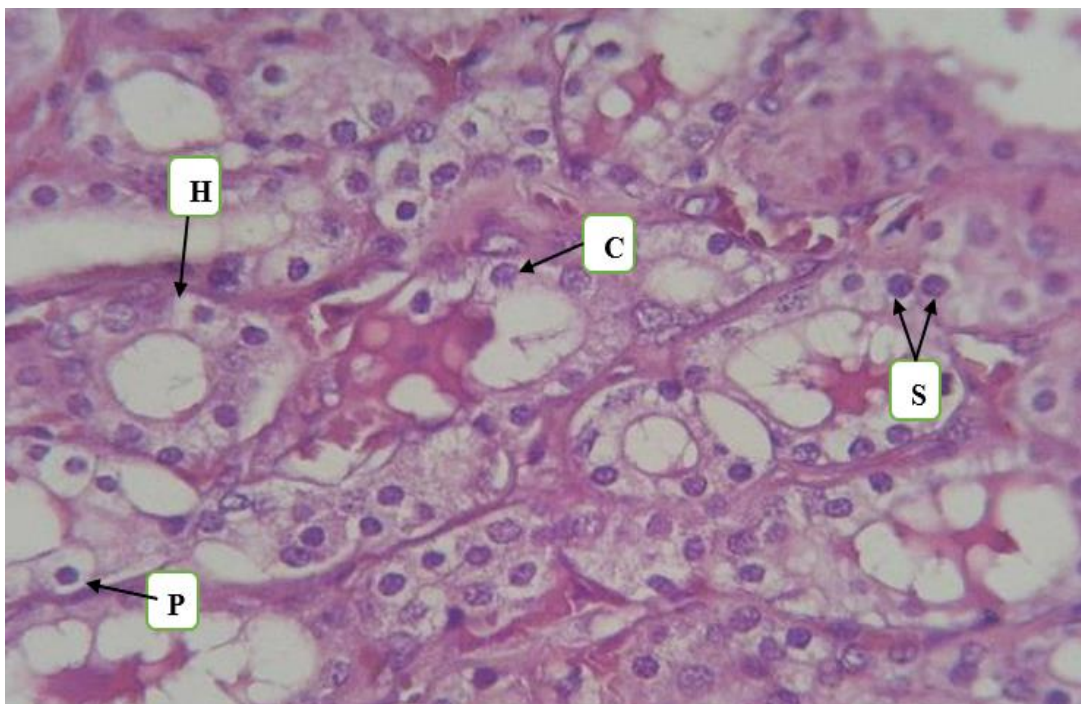


Fig.10. Cross Microscopic section of the right lobe of thyroid gland in camel shows the : C. Circle Follicular cells, S.Simple cuboidal epithelium , H. Thyroid follicles, P.Para follicular cell H&E X400.

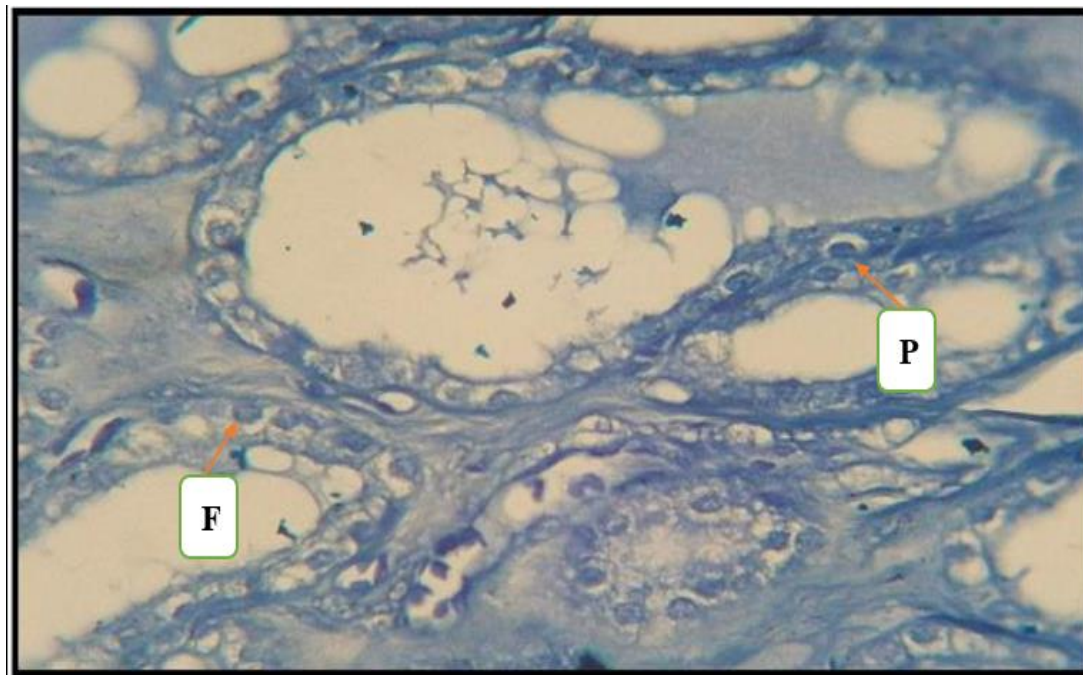


Fig.11. Cross microscopic section of the left lobe of thyroid gland in camel shows the : F. Follicular cells, P. Parafollicular cell ,Toluidine blue X400

Conclusion,

With a few exceptions, such as the size of the thyroid gland and the length of its lobes, the thyroid gland of an adult one-humped camel has a thin capsule, only two types of follicular cells, and parafollicular cells are rare and absent in many sections and the isthmus. The thyroid's colloid is different from that of other ruminants, which are adapted to hot, dry, and unfavorable climates. The thyroid gland of a camel helps to maintain water level by lowering pulmonary water loss and metabolism. These unique characteristics allow the camel to adapt to its physiology and harsh niche.

Acknowledgment: We would like to thank all of the participants who made this research possible for us to finish and publish. We appreciate their efforts.

Conflict of interest: The manuscript's authors have said that there were no conflicts of interest during the drafting process.

References

1. Marisa, M. (2011): All About Camels. All rights reserved. Revised: 11 Nov 2011 13:05:00 - 0500.
2. McDonald, L.E. (2003). Veterinary Endocrinology and Reproduction. 5th

- edition. Iowa State Press, Iowa, PP 165-201.
3. Abdulzahra, Ibrahim A., (2020). "Histopathological change study of the attachment sites of adult ticks on slaughtered camels skin in Al-Muthanna Province." *EurAsian Journal of BioSciences* 14.2.
 4. Dellmann HD, Eurell JA. (1998). Textbook of veterinary histology. 5th ed. Awoters Kluwer company. Philadelphia ; 287 -391 p.
 5. Bengoumi, M., Moutaouakil F., De La Farge F., Faye B., (1999). Thyroidal status of the dromedary camel (*Camelus dromedarius*): Effect of some physiological factors. *J. Camel Pract. Res.*, 6 (1), 41-43.
 6. Bengoumi, M., Moutaouakil F., De La Farge F., Faye B., (2003). Seasonal variations of the lasma thyroid hormone concentrations and the body temperature in the dromedary camel. *J. Camel Pract. Res.*, 10 (2), 115-119.
 7. Bhardwaj, R. L; Rajput, R; Pathak, V and Thakur, K. (2006). Animal Comparative anatomy of the thyroid gland of small ruminants *Indian Journal of Sciences* 76(1): 46-47.
 8. Hussein, Diyar Mohammad, and Iman Mousa Khaleel. (2024). "Histological, Histometrical and Hormonal Assay Comparative Study of Thyroid Glands between Suckling and Adult Local Male Cats (*Felis catus*)."
University of Thi-Qar Journal of agricultural research 13.2: 486-505.
 9. El-Zoghby, I.M.A. (2004). Morphological Structure of the Buffalo's Internal Parathyroid Gland. Zagazig. *Veterinary Medical Journal*. 456-490.
 10. Faye, B. and Bengoumi, B. (2000): Le dromadaire face à la sous-nutrition minérale. un aspect méconnu de son adaptabilité aux conditions désertiques. *Sécheresse*. 11 (3), 155-61.
 11. Fleischer, C., Becker, D., Hamele-Bena, T., Breen, L. and Silverberg, S. J. (2004). Oxyphil Parathyroid Adenoma: A Malignant Presentation of a Benign Disease. *Journal of Clinical Endocrinology Metabolism*, 89 (12): 5948 – 5951.
 12. Ganong, W. F. (2005). Review of Medical Physiology. 28th ed. Alange Medical Company London. Pp: 955-969.
 13. Suvarna SK, Layton C, Bancroft JD. (2018). Bancroft's theory and practice of histological techniques, 8th ed. Churchill Livingstone Elsevier Philadelphia.; 176 -725 p.

14. Al-Rawi KM, Kalaf-Allah IS. Design and Analysis Agriculture Experiments. Dar-Al Kutub-Mosul, Iraq.1980; 65, 95-107 p.
15. Dyce, K. M., Sack, W. O., And Wensing, C. J. G. (2010). Textbook Of Veterinary Anatomy-E-Book. Elsevier Health Sciences; Pp:200-300.
16. Eurell JAC. Veterinary histology, Teton New Media,U.S.A. 2004; 64-67 p.
17. Bornstein, S., (2010). "Important ectoparasites of Alpaca (*Vicugna pacos*)". *Acta Veterinaria Scandinavica* 52 (Suppl 1): S17.
18. Capen, C. and Martin, S. L. (2003). *The Thyroid Gland, Veterinary Endocrinology and Reproduction*, 5th Edition. Iowa State Press, Ames, Iowa PP. 35-69.
19. Charles, C. C., Adalbert, K., and Clarence, R. C. (2000). The ultrastructure, histopathology, and histochemistry of the parathyroid glands of pregnant and non pregnant cows fed a high level of vitamin D. *Laboratory Investigations*, 14, (10): 1809-1825.
20. Doley, A. (2017). Histological study of thyroid gland in some mammals. *J. Evid. Based Med. Healthc*, 4 (74): 4387-4390.
21. Hajovska, K. (2002). Prenatal thyroid gland in sheep with regard to the presence of the isthmus. *Anatomia Histologia Embryologia* 31(5): 300.
22. Hamad, E. S. A. (2008). Seasonal Changes in the Morphology and Morphometry of the Thyroid Gland of the Nubian Goat. M.V.Sc Thesis, Faculty of Veterinary Medicine University of Khartoum, Sudan.
23. Hussein, A.M. (2003): Anatomical and histological study on the adrenal gland of the local donkey (*Equus asinus*). Iraq. *Journal Veterinary Science*.129-132
24. Hussin, A.M and Al-Taay, M. M. (2009). Histological study of the thyroid and parathyroid glands in iraqi buffalo "*bubalus bubalis*" with referring to the seasonal changes. *Bas.J.Vet.Res*.8 (1) :26-38.
25. Elrayah A.H., Hussein A.S., El Sheikh B.M., Osman A.H., Mahadi N.Y., 2009. Assessment of thyroid hormones (Triiodothyronine T3 and thyroxin T4) in Sudanese camels (*Camelus dromedaries*). The second conference of the international society of camelid research and development. Djerba (Tunisia), 21-14.
26. Kausar R, Shahid RU (2006). Gross and microscopic anatomy of thyroid gland of one-humped camel (*camelus dromedarius*). *Pak. Vet. J.* 26:88-90.
27. Nagpal, S. K., Sudhakar, L. S., Yashwant, S and Dhingra, L. D. (2001). Histomorphology of parathyroid gland

- of camel. *Indian Journal of Animal Science*, 59 (1): PP 80-84.
28. Khaleel. I.M and A.A.M. Salih (2017). Comparative Histomorphological and Histochemical study of thyroid gland in adult indigenous gazelle (*Gazelle Subgutturosa*) and sheep (*Ovis aries*). *Journal of Entomology and zoology studies*. 5(6):1236-1241.
 29. Kuria S G, Tura IA, Amboga S, Walaga HK (2013). Status of minerals in camels (*Camelus dromedarius*) in north eastern Kenya as evaluated from the blood plasma. *Livest. Res. Rural Dev*. 25:8.
 30. Mubarak, W., Sayed, R., (2005). Ultramicroscopical study on thyrocalcitonin cells in the camel (*camelus dromdarius*). *Anatomia Histologia Embryologia* 34, 35.
 31. Nabipour A., Khanzadi S. and Behdegani A. (2008), Gross And Histological Study On the Adrenal Glands in Camels (*Camelus Dromedarius*). *Journal of Camel Practice and Research*. Vol. 15. 1. 121-125.
 32. Nazifi S, NikahvalB, Mansourian M, Razavi SM, Farshneshani F, Rahsepar M, Javdani M, Bozorgi H (2009). Relationships between thyroid hormones, serum lipid profile and erythrocyte antioxidant enzymes in clinically healthy camel (*Camelus dromedarius*). *Rev. Med. Vet*. 160:3-9.
 33. Omidi A, Sajedi Z, Montazer Torbati MB, Ansari Nik H (2014a). Lipid profile and thyroid hormone status in the last trimester of pregnancy in single-humped camels (*Camelus dromedarius*). *Trop. Anim. Health Prod*. 46:609-614.
 34. Omidi A, Sajedi ZH, Montazer Torbati MB, Mostafai M (2014b). Metabolic profile of pregnant, non-pregnant and male two humped camels (*Camelus bactrianus*) of Iran. *Iran. J. Vet. Med*. 8:235-242.
 35. Ouajd, S. and Kamel, B. (2009): "Physiological Particularities of Dromedary (*Camelus dromedarius*) and Experimental Implications". *Scandinavian Journal of Laboratory Animal Science*. 36 (1). 19.
 36. Rejeb, A., Amara, A., Rekik, M. and Rezeigui, H. (2011): Histomorphometry and hormone secretion of the thyroid gland of the One-humped Camel (*Camelus dromedarius*). *Journal of Camelid Science*, 4: 10-22.
 37. Salih, A. A. M. (2018). Comparative Anatomical and Histological study of the thyroid gland in adult male indigenous gazelle (*Gazella subgutturosa*) and Rams (*Ovis aris*). M.V.Sc. Thesis,

College of Veterinary Medicine.
University of Baghdad.

38.Hussein, Diyar & Hadi, Khalid. (2023).
View of Histological and histochemical
studies on the structural development of the
trachea in Awassi rams *Ovis aries* during
postnatal and sucking life. Journal of Survey
in Fisheries Sciences (SFS) ISSN: 2368-
7487,10(35).

39.Roshdy, K., Alsafy, M. A., El-Gendy, S.
A., El-Mansi, A. A., & Rezk, S. (2024).
Microscopic Focus on the Thyroid Follicles
of the One-Humped Camel (*Camelus
dromedarius*). *Microscopy and
Microanalysis*, 30(2), 382-391.