

Detection the infection with *Babesia spp.* *Cytauxzoon felis* and *Haemobartonella felis* in stray cats in Mosul

E. G. Suliman

Department of Microbiology, College of Veterinary Medicine, University of Mosul, Mosul, Iraq

Abstract

The current study was included to examination of 50 blood samples which collected from 50 stray cats in Mosul city for diagnosis *Babesia spp.*, *Cytauxzoon felis* and *Haemobartonella felis*, different diagnostic techniques were used for differentiation between these parasites, they were: Impression smear, fine needle aspiration and histological examination of the liver and spleen. Some clinical signs and pathological changes were observed in the affected cats which may be result from the infection with these blood parasites. The percentage of infection with *Babesia spp.* (small type), *Cytauxzoon felis*, and *Haemobartonella felis* were 26%, 22%, 42% respectively. The sizes of *Babesia spp.* was between 1.33-2.15 μ within a mean of 1.53 μ and the size of *Cytauxzoon felis* ranged between 0.8-2.3 within a mean of 1.64 μ while the sizes of *Haemobartonella felis* varied between 0.5-2 μ within a mean of 1.15 μ . Tissue stage (schizonts) of *Cytauxzoon felis* were diagnosed in the cytoplasm of macrophages in the liver and spleen with different stage of replication.

Keywords: *Babesia*, *Cytauxzoon*, *Haemobartonella*, Cat.

Available online at <http://www.vetmedmosul.org/ijvs>

تحديد الخمج بطفيلي *Babesia spp.* و *Cytauxzoon felis* و *Haemobartonella felis* في القطط السائبة في مدينة الموصل

إيمان غانم سليمان

فرع الاحياء المجهرية، كلية الطب البيطري، جامعة الموصل، الموصل، العراق

الخلاصة

تضمنت الدراسة الحالية فحص ٥٠ عينة دم جمعت من ٥٠ قطرة سائبة في مدينة الموصل وذلك للكشف عن طفيلي *Babesia spp.* و *Cytauxzoon felis* و *Haemobartonella felis* واستخدمت عدة تقنيات تشخيصية وذلك للتفريق بين هذه الطفيليات وهي: مسح طبقات الانسجة ورشافة الابرة الدقيقة والفحص النسجي لكل من الكبد والطحال، حيث تم ملاحظة بعض العلامات السريرية والتغيرات المرضية على القطط الخمجة والتي قد تكون ناشئة عن الخمج بهذه الطفيليات. بلغت نسبة الخمج بكل من طفيلي *Babesia spp.* (الانواع الصغيرة) و *Cytauxzoon felis* و *Haemobartonella felis* ٢٦٪ و ٢٢٪ و ٤٢٪ على التوالي. تراوح حجم طفيلي *Babesia spp.* بين ١.٣٣-٢.١٥ مايكرون وبمعدل ١.٥٣ مايكرون وحجم طفيلي *Cytauxzoon felis* بين ٠.٨-٢.٣ مايكرون وبمعدل ١.٦٤ مايكرون بينما تراوح حجم طفيلي *Haemobartonella felis* بين ٠.٥ - ٢ مايكرون وبمعدل ١.١٥ مايكرون. شخخص الطور النسجي (مرحلة التكاثر الانفلاقي) لطفيلي *Cytauxzoon felis* داخل سايتوبلازم الخلايا البلعمية للكبد والطحال وبمراحل تكاثرية مختلفة.

Introduction

Babesia spp. are tick -borne hemoprotozoal parasites found in a variety of domestic, wild animals and humans. in

domestic cats, babesiosis has primarily been reported in South Africa and Sudan where infected is mainly due to *Babesia felis*, a small *Babesia spp.* that causes anemia and icterus (1). Others *Babesia spp.* were detected in naturally

infected domestic cats in different countries such as: *B. leo* from Africa, *B. cati* from India, *B. canis canis* from Spain and Portugal, and *B. microti* – like spp from Portugal (2). In addition sporadic cases of infection in domestic cats by unidentified *Babesia* spp. (3-6). Feline babesiosis often presents as a chronic low grade disease (1) and the appearance of certain clinical signs (7). *C. felis* is a protozoan parasite that causes cytauxzoonosis (Cat's theileriosis) (8). *C. felis* was classified in the order: piroplasmida, Family: Theileriidae (9), the genus Cytauxzoon has two stages in their life cycle: Erythrocytic stage, signet rings 1-1.5 µm in diameter, bipolar oval (safety pin) 2 µm in diameter and tetrad forms or anaplasmod round "dots" less than 0.5 µm in diameter (10). The second stage occur in the spleen, liver, and lymph nodes and the parasite proliferate in the mononuclear phagocytes undergo asexual reproduction, resulting obstruction of the blood flow (11,12). Which eventually cause host cell rupture and enter the blood, these intravascular merozoites infects variable numbers of erythrocytes (13). *C. felis* is believed to be spread by ticks bites of cats (12,14,15). The death are depended on the development of schizonts in mononuclear phagocytes rather than parasitemia (8).

H. felis is a gram negative epicellular parasites of feline Red Blood cells, the organisms was classified in the Family: Anaplasmataceae, but recently was shown to be more closely related to the Genus: Mycoplasma (16,17). Haemobartonella appear microscopically as cocci or short rods on the surface of red blood cells often completely surrounding the margin of the red cells and which are tightly attached to the red cells and are rarely free in the plasma (9). *H. felis* is a significant cause of hemolytic anemia in young cats recovered cats may remain as carriers (9,16,18). *H. felis* may be transmitted by a number of routes such as: injection of small volume of blood from an infected cats, blood sucking arthropods like fleas and ticks (16), (19) also reported the *H. felis* can be transmitted from queen (mother cats) to her kittens. The disease can run the spectrum from being very mild, asymptomatic, or a slight anemia, to a very severe form, (16,19). Because the fewer information about the prevalence of infection with these parasites in cats in Mosul city, therefore the aim of the present study was to determine the infection with *Babesia* spp, *C. felis* and *H. felis* in stray cats.

Materials and methods

In this study, 50 cats, in different ages group and both sexes were obtained from different areas of Mosul City from the period of March 2008 to March 2009, all examined clinically and signs were recorded before blood samples were taken from the cephalic vein during the postmortem, thin blood smears were prepared and stained

with Giemza to identify the *Babesia* spp, *C. felis* and *H. felis* (20) and the procedures used for determination the percentage of parasitemia by measuring one thousand of RBC, Later the percentage of parasitemia in the RBCs were calculated according to the following formula (21):

$$\frac{\text{The infected RBCs}}{\text{Calculated RBCs}} \times 100$$

Diagnosis of *C. felis* was made on the basis of the study of schizonts which is not present in *Babesia* spp and the *H. felis* which chains form, the techniques were used includes; Impression smear from liver, spleen (22), fine needle Aspirate of the spleen (23), histological examination of liver, and spleen, these organs fixed with 10% neutral buffered formalin, embedded in paraffin, sectioned 6µm thick and stained with hematoxylin and eosin (24).

Differentiation of *B. spp*, *C. felis*, and *H. felis* also made on the basis of specific feature and by microscopic measurement by using ocular micrometer (9,25,26).

Results

In this study, some clinical signs were observed during blood sampling before PM and some pathological lesions when PM performed. The clinical findings included appearance of pale mucous membrane, weakness, rough hair coats, jaundice nasal discharge and diarrhea. PM diagnosis showed generalized pallor of different organs, enlarged lymph nodes, congested lungs, and petechial haemorrhage on the surfaces of abdominal organs and lungs, slight to marked enlargement of liver and spleen, the spleen was dark and the liver in orange-brown colour. The examination of blood smear revealed diagnosis of: *B. spp*, *C. felis* and *H. felis*, with percentage 26%, 22%, 42% respectively (Table 1).

Table 1: The percentage of infection with the *B. spp.*, *C. felis* and *H. felis* in 50 examined cats.

The parasite	Number of affected cats	The percentage of infection
<i>B. spp</i>	13	26
<i>C. felis</i>	11	22
<i>H. felis</i>	21	42

Babesia spp. appeared in blood smear as small intracellular piroplasm, round, oval and in some blood smear appeared as pyriform shape and found within Red blood cells in a single or pairs (Fig. 1).

The sizes are between 1.33-2.15 µm within a mean 1.53 micron and the percentage of parasitemia was 0.6-2.4% with a mean of 1.4% (Table 2).

Table 2: The morphological features, microscopical measurements and percentage of parasitemia from *B. spp.*, *C. felis* and *H. felis*, in 50 blood smears of cats.

The parasite	Morphological features	Measurements range (mean) μm	The percentage of parasitemia, the range (mean)
<i>B. spp</i>	Round, oval, pyriform, intracellular piroplasm	1.33-2.15 (1.53)	0.6-2.4 (1.4)
<i>C. felis</i>	Signet rings, safety pin and anaplasmoid	0.8-2.3 (1.64)	0.8-5.9 (2.99)
<i>H. felis</i>	Cocci, rods, chain on the surface of red blood cells	0.5-2 (1.15)	2.1-6.1 (3.78)

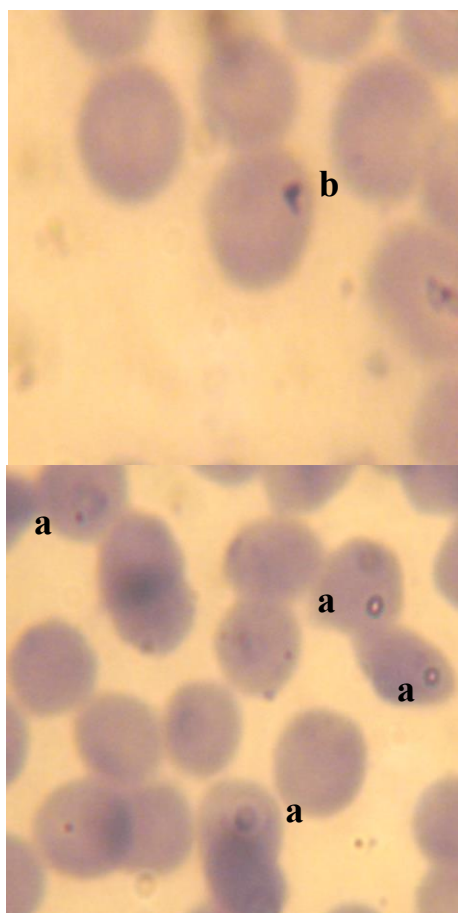


Fig (1): Intracellular piroplasms (small *B. spp.*) in blood smear of cats. 1700X. (a) round form (more common), (b) pyriform (less common).

C. felis diagnosed in the Red blood cells as round to signet rings, safety pin and anaplasmoid round shape, the cytoplasm of *C. felis* was stained light blue while the nucleus was stained dark red or purple in colour, the diameter ranged between 0.8-2.3 μm within a mean of 1.64 μm and the Red blood cells appeared as containing one parasite of *C. felis* as well as in pairs or tetrads form (Fig 2). The percentage of parasitemia 0.8-5.9% within a mean of 2.99% (Table 2).

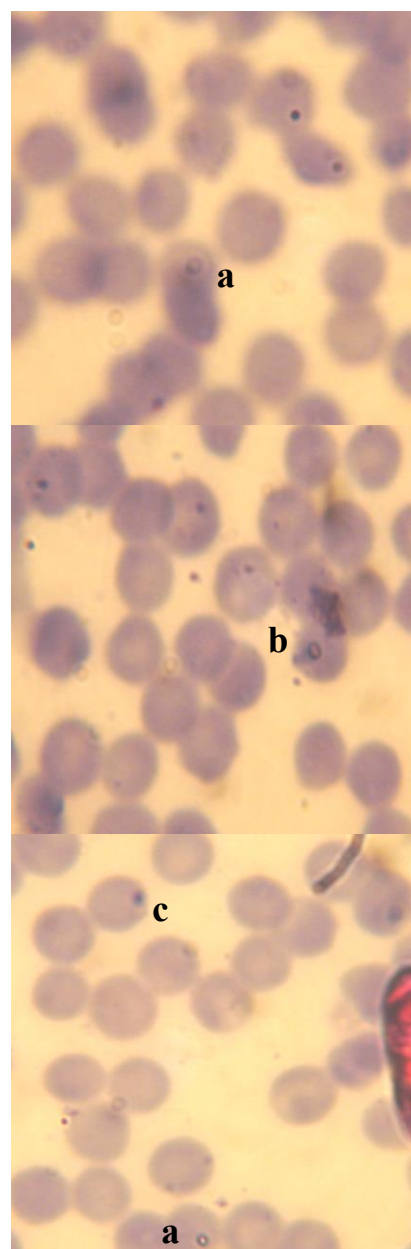


Fig (2): *C. felis* in blood smear of cat. 1400X. (a) signet ring, (b) safety pin, (c) anaplasmoid forms.

H. felis appeared in blood smears as small, blue staining cocci, rods and in some cases appeared as chain forming. These organisms attached to the external surface of the Red blood cells (Fig 3).

The sizes varied between 0.5-2 micron in diameter with a mean of 1.15 micron and the percentage of parasitemia was 2.1-6.1% with a mean of 3.78% (Table 2).

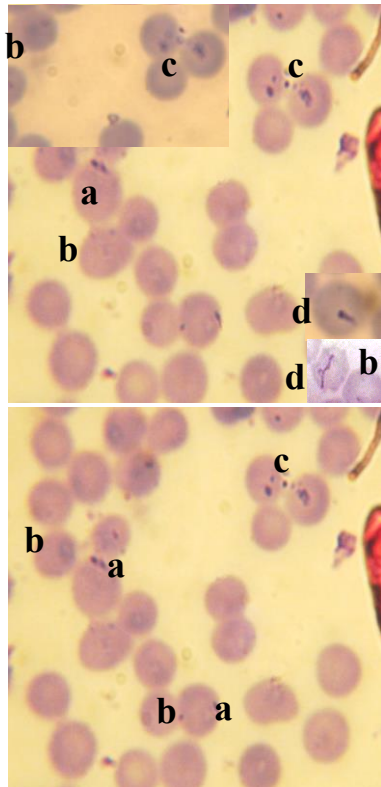


Fig (3): *H. felis*, located on the surface of RBCs in blood smear from a cat.1200X.(a) rod form, (b) small blue staining cocci, (c) small aggregates, (d) chain forming (un common).

Impression smears from liver and spleen and fine needle Aspirate from spleen showed schizont's of *C. felis* present in the cytoplasm of macrophages (in different replication) and contain a number of merozoites the nucleus of macrophages located at the bottom of the macrophages and in some cases has been disintegrated (Fig 4).

On histopathological examination the merozoites of *C. felis* appeared in the cytoplasm of phagocytes that are especially attached to the endothelium of vessels of liver and spleen in various stages of replication from the first development in the cytoplasm of macrophages until to demonstrating macrophages with schizont and merozoites in the parenchyma of liver and spleen. The parasite-laden macrophages identified free within the lumen or attached to

the vessels leading in partial obstruction of blood vessels (Fig 5).

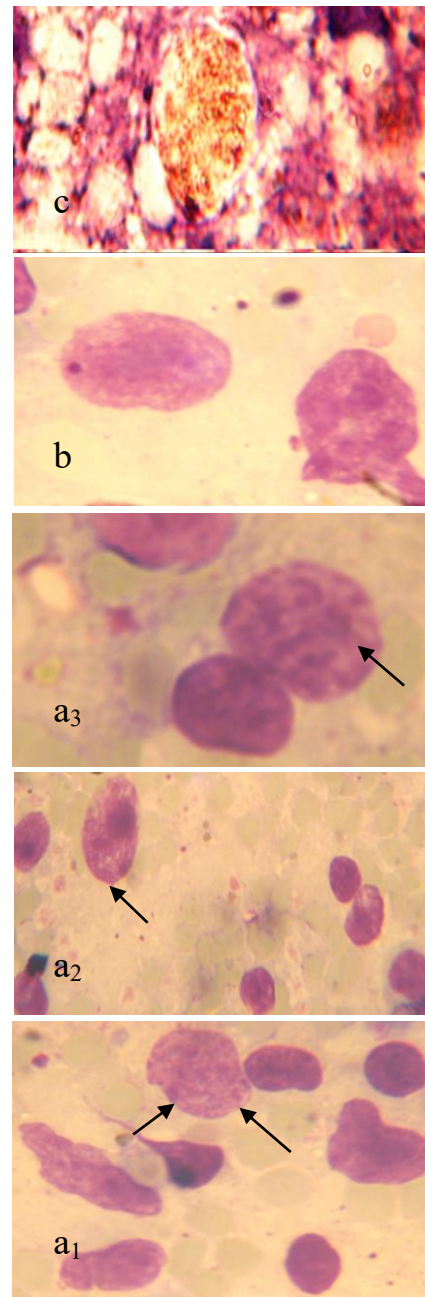


Fig (4): Tissue stage of *C. felis* (a 1-2-3) Impression smear, spleen, Giemza stain, macro phages contain schizonts and merozoites of *C. felis* in different replication. 1200X, (b) fine needle aspirate, spleen, Giemza stain, (c) Impression smear, liver, Giemza stain (large macrophages contain large number of *C. felis* merozoites and the nucleus of the).

macrophages is eccentrically located at the bottom of the cells). 1400X.

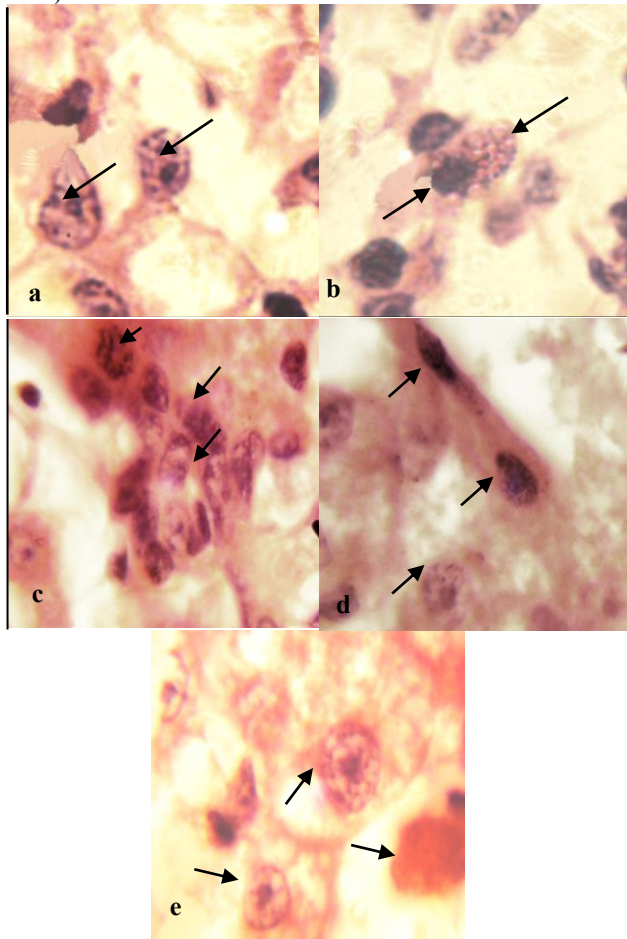


Fig (5): Histopathological examination of tissue stage of *C. felis*, (a) Early schizonts of *C. felis* development within macrophages in the liver ,H & E. 1400x, (b) the merozoites of *C. felis* within the macrophages and the nucleus of the cell located at the bottom edge (ghost of nucleus).liver ,H & E. 1400x, (c) Demonstrating macrophages with schizonts of *C. felis* and merozoites in the parenchyma .liver ,H & E.1200x, (d) Tissue stage of *C. felis* within macrophages which located near to the wall of blood vessels .liver ,H & E .1200x, (e) Partial obstruction of blood vessels by parasite – laden macrophages . liver.H&E. 1200x.

Discussion

There are a little information and studies about stray cats, which lives around and contaminate the surrounding, therefore, they may be affected with many different parasitic diseases, such as infection with blood parasites. In this study blood samples were collected and postmortem performed, certain clinical signs and pathological lesions

were observed in cats who was microscopically positive for *B. spp.*, *C. felis* and *H. felis*, in addition that these cats were affected with other parasites such as different internal parasites, (27) referred that feline babesiosis often present as chronic lowgrade disease and the most clinical findings of sympatomatic feline babesiosis are anorexia, lethargy, weakness and a rough hair coat.

The clinical signs which observed in cats with cytauxzoonosis are non specific, no ticks were found and mortalities was nil, in this study, some cats showed splenomegaly, hepatomegaly and the lungs were congested. The results were in agreement with (8) who demonstrated the presence of *C. felis* in Van cats in Turkey and revealed that preimmunity against the parasite may prevent the observation of the clinical sings. Recent studies indicate historically, cytauxoonosis has been nearly 100% fatal in domestic cats, increasing number of reports of infected cats which demonstrate less and sever disease suggest the existence of different strains of *C. felis* (28).

In naturally affected cats with haemobartonellosis, the clinical signs occur in immunocompetent or immunosuppressed cats and depend on the degree of anemia, stage of infection and the immune status of infected cats (16). Some of the cats recovered from this disease to become carries for the *H. felis* this mean that some cats look healthy but still have small numbers of these parasites in their bodies, if these cats are stressed, it sometimes causes parasites to multiply and produce disease (19). In the infection with *H. felis* the gross necropsy findings are not pathognomonic, but splenomegaly is common and mesenteric lymph nodes may be enlarged (15).

In present study, the percentage of infection with *B. spp.* was 26%, (27) who referred that feline babesiosis appear to be less common. Sporadic cases of babesiosis has been reported from various countries such as France, Germany, Thailand, and Zimbabwe (3-6) while studies in South Africa indicate a higher prevalence of *B. felis* infection has been observed in Siamese and Oriental cats (1). In endemic area many cats are exposed to the parasites at any early age, it appears that some of these cats may become chronic asymptomatic carrier, concurrent illness or stress contributes to the exacerbation of clinical babesiosis in carrier cats (1,29).

The mean size of *B. spp* which diagnosed in this study was 1.53 μ m and the mean percentage of parasitemia was 1.4%. Classification were done according to the size and morphology of felin *B. spp*, in this study, it concluded that the *B. spp* which described as a small type, (29) who classified feline piroplasms morphologically as small piroplasms < 1.5 μ m or as large piroplasms > 2.5 μ m. Small feline piroplasms include *B. felis*, *B. leo* and *Cytauxzoon* and large feline piroplasms include, *B. cati*, *B. pantherae*, *B. canis canis*, *B. canis presenti* and *B. herpailuri* while in

France, Germany, Thailand, and Zimbabwe un characterized spp has been reported (3-6), (30) revealed that the detection of this organisms in blood smear may be difficult because the level of parasitemia may be low and (1) showed that the feline babesiosis often present as chronic low grade disease.

In this study, during the examination of 50 stray cats, *C. felis* was diagnosed in 11 cats with percentage 22%, by using thin blood smear, impression smear, fine needle aspiration and histological examination, in compared with a study in Van region in Turkey, depending on the examination of 120 blood smears of cats only 9 cats had *C. felis* with percentage 7.5%. On microscopic examination of blood smears of cats, multiple Red Blood cells had *C. felis* which appear in different forms like signet ring, safety pin and anaplasmod form, the mean size of *C. felis* was 1.64, this results was agreement (12,15), they considered that *C. felis* was small felin piroplacms while (31) referred that these bodies ranged between 1-5 μ m in diameter. The mean percentage of parasitemia with *C. felis* which recorded in this study was 2.99%, (32) referred that the piroplasms appeared in affected cells from only a few perfilm to 25% before death while the (13) referred that the parasitemia of *C. felis* in the RBCs is low and the number of Red Blood cells parasitized with *C. felis* varies among cats and with the stage of disease, (31) recorded that up to 25% of Red Blood cells may be affected with *C. felis*. In impression smears from liver and spleen and with fine needle aspiration from spleen, showed many macrophages contain large number of schizonts with innumerable *C. felis* merozoites and these cells appeared especially at the feathered edge of peripheral smears, this results was agreement with (12,32).

On histopathological examination large number of parasitized macrophages containing large numbers of merozoites in different stages of replication free within the lumen of the organs (liver, spleen) or on the walls of the veins these vessels appeared partially on completely occluded this results were in agreement with (12,33,34).

In present study, the percentage of infection with *H. felis* was 42%. (22,35) which they referred that many cats are carrier to *H. felis* while (36) showed that the prevalence of this parasites in the feline population from 0.9% to 28% and the cats without door were more likely to be infected with Haemobartonella. The result of this study revealed that *H. felis* appeared in cocci, rod, chain form on the surface of Red blood cells and the mean size was 1.15 μ m this is in agreement with (9,25), the mean percentage of parasitemia of *H. felis* was 3.78%, (15) referred that the number of RBCs affected varies with the severity of the infection and the stage of life cycle of the parasite. In acute phase numbers of *H. felis* increase gradually than disappear rapidly, while in chronically infected cats, the parasites appear only sporadically and in small numbers, and the

parasitemia of *H. felis* is transient or cyclical. The peak of parasitemia may last for few days but occurs just prior to the hemolytic episode, by the time the infected cats is presented, very few or no parasite may be detected on blood film. Thus a single negative findings is not adequate evidence for freedom from infection, it is necessary therefore to examine a number of blood film prepared over a period of 4-10 days, before it may be concluded that the patient is free from infection (37).

Reference

1. Penzhorn BL, Schoeman T, and Jacobson LS. Feline babesiosis in South Africa: A review Ann. NY Acad Sci 2004;1026:183-186.
2. Schoeman T, Lobetti RG, Jacobson LS and penzhorn BL. Feline babesiosis: Signalment, Clinical Pathology and Co-infections. J Vet Assoc 2001;72:4-11.
3. Stewart CG, Hackett KJW and Collett MG An unidentified *Babesia* of the domestic cat (*felis domesticus*). J S Afr Vet Assoc, 1980;51:219-221.
4. Bourdeau. Les babesiosis felines. Le Point Vet. 1996, 27:947-953. (In French).
5. Jittapalapong S, Jansawan W. Preliminary survey on blood parasites of cats in Bangkok District areas Kasetsart. Journal National Sciences 1993;27:330-335.
6. Moik K, Gothe R. Babesia infections of felids and a report on a case in a cat in Germany Tierärztliche Praxis. 1997;25:532-535.
7. Jacobson LS, Schoeman T, and Lobelti RG, A survey of feline babesiosis in South Africa. JS Afr Assoc 2000;71:222-228.
8. Karaca M, Akkan HA, and Tutuncu M, Ozdal N, Deger S, and Agaoglu ZT. Cytauxzoonosis in Van cats. yyu Vet fak derg. 2007;18(1):37-39.
9. Urquhart GM, Armour J, Duncan JL, Dunn AM and Jennings FW. Veterinary Parasitology 2nd. ed. Black Well Science 2003;211.
10. Cowell RL, Fox JC, and Jyler RD. Feline Cytauxzoonosis compend Contin Educ Pract Vet 1988;10:731-736.
11. Butt MT, Bowman D, Barr MC, and Roolke ME. Latrogenic transmission of *C. felis* from a Florida Panther (*Felis Concolor Coryi*) to a domestic cat. Journal of Wildlife Disease 1991;27(2):342-347.
12. Dailey DF, Rakich MP, and Latimer KS. Cytauxzoonosis in cats: An overview Veterinary Clinical Pathology Clerkship Program. <file:///J:lre.htm,2001:1-6>.
13. Meier HT, and Moore LE. Feline Cytauxzoonosis: A case report and literature review. J Am Vet Med Assoc 2000;36:493-496.
14. Brooks W. Cytauxzoonosis in cats the pet health library, Educational Director. Veterinary Panther Com 2008;1-3.
15. Merck Co. Cytauxzoonosis, Hemobartonellosis (Feline infections anemia). The Merck Veterinary Manual 2006; www.merckvetmanual.com/mvm/htm/bc/1040.htm.
16. Lappin M. Felin Ehrlichiosis and Hemobartonellosis WSAVA Contact Information. 2007;2-3.
17. Berent LM, Mnessick JB and cooper SK. Detection of *H. felis* in cats with experimentally induced acute and chronic infections, using apolymerase chain relation assay Am J Vet Rec 1998;59(10):1215-20.
18. Shaw SE. Haemobartonella and Bartonella: Two very different diseases. World small Cats Veterinary Association World Congress Proceeding, 2003.
19. Nash H. Haemobartonellosis (Feline infections Anemia) in cats Pet Education.com.2007.
20. Hendrix CM. Diognostic Veterinary Parasitology 2nd Edition. Mosby Inc, United States of America 1998;265-267.
21. Adam KMG, Paul J and Zaman V. Medical and Veterinary protozoology. Churchill livengston, Edinbugh and London. 1971;126-133.

22. Soulsby E.J.L. Helminths, Arthropods and Protozoa of domesticated cats 7th edition, London, Philadelphia, Toronto 1986;723-728.
23. Ahmed HO Fine needle Aspiration cytology in Breast Lesions J Dohuk Univ 2002, 5(2);72-74.
24. Luna LG. Manual of Histologic staining methods of the Armed forces institute of pathology. 3rd ed. McGraw-Hill Book Company. 1968;32-40.
25. Harvey JW. Atlas of Veterinary Hematology, Blood and Bone Marrow of domestic cats WB Saunders Company Philadelphia, London, New York, St. Louis, Sydney, Toronto 2001;40-44.
26. Thrall MA, Baker DS, Campbell TW, Denicola D, Fettman M, Lassen ED, Rebar A, Weiser G. Veterinary Hematology and Clinical Chemistry Lippincott Williams & Wilkins, United States of America 2004;77.
27. Irwin PJ. Babesiosis in Dogs and Cats. World Small Cats Veterinary Association World Congress Proceeding 2003;1-3.
28. Brown HM, Berghaus RD, Latimer KS, Britt JO, Rakich M and Peterson DS. Genetic variability of *C. felis* from 88 infected domestic cats in Arkansas and Georgia. J Vet Diagn Invest 2009;21(1):59-63.
29. Kjemtrup AM, Kocan AA, Whitworth L, Meinkoth J, Birkeneuer AJ, Cumming J, Boudreaux SL, Stockham L, Irizarry Rovira A, and Conrad PA, There are at least three genetically distinct small piroplasms from dogs. Intern J Parasitol 2000;120:487-493.
30. Criado-Fornelio A, Gonzalez-del-Rio MA, Buling-Sarana A. The expanding universe of piroplasma. Vet Parasitol 2004;119:337-345.
31. Jones TC, Hunt RD, and King NW. Veterinary pathology. Philadelphia Baltimore, New York, London, 8th ed 1997;599-600.
32. Kier AB Cytauxzoonosis, In: Greene CE Clinical Microbiology and Infectious Disease of the Dog and Cat. WB Saunders Company 1984;791-795.
33. McGavin MD, and Zachary JF Pathologic Basis of Veterinary Disease 4th. ed Mosby Elsevier 2007;783-784.
34. Jackson CB, and Fisher T, Fatal Cytauxzoonosis in a Kentucky cat (*Felis domesticus*). Vet Parasitol 2006;139 (1-3):192-195.
35. Catcott EJ. Feline medicine and surgery 2nd. ed, United States of America 1975;69-70.
36. Willi B, Boretti FS, Tasker S, Meli ML, Wengi N, Claudia ER, Lutz H, Hofman-Lehmann R. From Haemobartonella to hemoplasma: Molecular methods provide new insights. Vet Microbiol 2007;125 (3-4):197-209.
37. Evans RJ. Feline Infectious Anemia In: Chandler EA, and Hilbery ADR Feline medicine and therapeutics. Blackwell Scientific Publication 1990;314-317.