

Disorders of the Cerebellum In Children , MRI – Clinical Correlation

Ahlam Mohamad Abdulabbas*, Muna Abdul Ghani Zghair**,
Raad Hifdhi Al-Khayat***

ABSTRACT:

BACKGROUND:

The recognition of cerebellar anomalies, with the advent of neuro-imaging, has greatly improved, it present a wide variety of clinical and radiological Imaging findings.

OBJECTIVE:

1. To describe the spectrum of cerebellar anomalies by MRI .
2. To correlate with clinical presentation.

MATERIALS AND METHODS:

Sixty six patients (22 Females, 44 Males) with the diagnosis of some form of cerebellar malformations, were included in this study, in the Central Teaching Hospital of Pediatrics in Baghdad over 18 months from July 2103 through December 2104. They were arranged for complete clinical and neuro-radiological evaluation. Age ranging from over 1 month --- 15 years.

RESULTS:

Twenty nine patients (43.9 %) had vermian hypoplasia, ranging from mild to moderate , cerebellar hypoplasia (19) patients (28.7 %) , combined anomalies in 16 patients (24.4%) and 2 patients (3 %) with cystic dilatation of the posterior fossa. The bulk of cases fall in the category of 1-- 5 years age group, with the major clinical presentation being motor and speech deficits, 28 (80 %) and 27 (77.1 %) patients respectively.

CONCLUSION:

Magnetic resonance imaging is the basic modality of choice, in the setting of cerebellar malformation, especially in the association of extreme variability of clinical presentation, and lack of easy availability of the required cytogenetic analysis

KEY WORDS: disorder of cerebellum , MRI.

INTRODUCTION:

The embryonic development of the hind brain region starts at about the third week of gestation and continues until 30 months of the post natal life. The cerebellum develops in rostral-caudal manner with the rostral region in the midline giving rise to the vermis and the caudal region giving rise to the cerebellum. Proliferation and organization of the cellular component of the cerebellum continues with completion of the foliation pattern by seven months postnatally, with final migration of cerebellar neurons by thirty weeks.^(1,2) Understanding of posterior fossa malformation, is based upon the embryonic morphology of the growing structures. Malformation of the posterior fossa have been recognized much more frequently during the past

decades, but the more recent classification is delineated by Parisi and Dobyns⁽²⁾, it was based on the embryological derivation of the involved structures. The rapid advance of imaging technologies, has greatly improved the recognition of, even the subtle developmental abnormalities.^(3, 4)

Neuro- imaging and specifically MRI, has a significant role in the detection of structural abnormalities , especially in the presence of wide variety of clinical symptoms, (ranging from mild or even asymptomatic adult individuals to neonatal death) , with the lack of easy availability of the required tests, makes the clinical diagnosis difficult.

MATERIALS AND METHODS:

This is a cross sectional study in which we identified the clinical feature combined with the MRI findings in 66 patients, not previously observed or reported with an abnormal cerebellum, in the Central Teaching Hospital of Pediatrics in Baghdad during a period of 18 months; from July 2013 through December 2014

*Pediatric specialist/ Central Teaching Hospital of Pediatrics/ Neurology Department

** AL-Mustansirya University/ College of Medicine. Assistant Professor

*** Iraqi Board For Medical Association. Assistant Professor.

DISORDERS OF THE CEREBELLUM IN CHILDREN

The children received only one MRI study. We informed the respondents about the study and got their acceptance by verbal consents, we included patients with history of developmental delay, speech delay ,epilepsy , cognitive dysfunction (poor concentration or poor school performance in older children), patients with any form of motor deficit (hypotonia, spasticity, hemiplegia, and ataxia) , but we included another 6 patients found to have abnormal MRI accidentally while they were investigated for other reasons e.g headache or follow up for chemotherapy although there was no previous history of any abnormality. We excluded patients with cerebellar atrophy being part of global brain atrophy related to perinatal asphyxia, patients with chromosomal abnormalities and hereditary disorders and patients who underwent major cerebello neuro-surgery. We also excluded patients with anomalies related to cranio-cervical junction and Chiari malformations. Patients with clinical features suggesting cerebellar anomalies but without abnormal neuro- imaging were excluded as well.

Magnetic resonance imaging was performed on 1.5 Tesla unit MEGNATOM (Siemens, Germany) using head coils. Imaging protocol include T1 weighted sagittal spin echo, axial T2 weighted turbo spine echo, coronal fluid attenuation inversion recovery (FLAIR) and axial fat suppression T2 weighted.

Accurate description of cerebellar and regional sub- arachnoid space malformation was assigned. Sedation with oral chloral hydrate, or ketamine, 50mg/ml in a dose of 1-2 mg/ kg was used in the young who could not tolerate the examination study.

RESULTS:

Sixty six patients were included in the study , we identified cases of cerebellar hypoplasia 19(28.7%), vermian hypoplasia /Jobert syndrome 29(43.9%),cystic dilatation of the posterior fossa 2(3%),and combined anomalies 16(24.4%), as shown in Figure -2- , of these 60 (90.9 %) patients had neurologic deficit, six patients (9.1%) had abnormal neuro- imaging , but clinically normal , their neuro-imaging referral were for other reasons ,e.g Headache , follow up for chemotherapy treatment or cases of pituitary adenomas.

Table 1: Distribution of study sample according to clinical presentation

Type of Anomalies	Epilepsy	Motor deficit	Speech deficit	Cognitive dysfunction	Normal
Cerebellar hypoplasia	13	14	12	15	2
Vermian hypoplasia	17	19	18	16	3
Mixed Anomalies	9	15	11	13	0
Giant Cisterna Magna	0	0	0	0	1

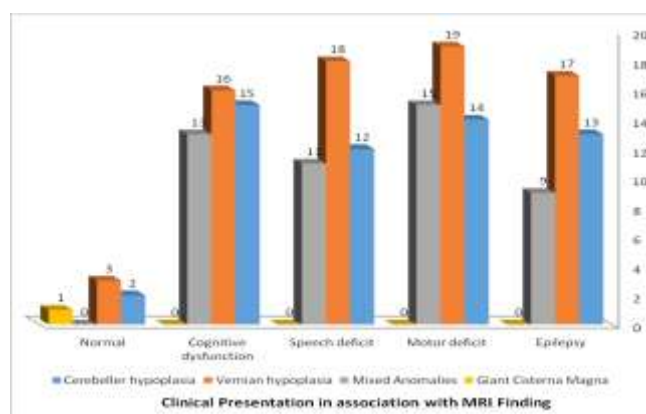


Fig 1: Describe the clinical presentation in association with MRI findings.

DISORDERS OF THE CEREBELLUM IN CHILDREN

The majority of cases presented with motor, speech deficit and epilepsy being 19,18 and 17 patients respectively showing abnormal neuro-imaging, presented as vermian hypoplasia. Six patients with the which we identified wide spectrum of clinical features associated cerebellar malformation so called molar tooth type of midbrain, hindbrain malformations including (Jobert syndrome) showing total aplasia or dysgenesis of the vermis

Eleven patients presented with a combination of vermian hypoplasia and Giant cisterna magna, and 5 patients with cerebellar hypoplasia and Giant cisterna magna. Sex distribution showed 44 patients were males(66.6%) while females were 22(33.4%). In revision of age groups the majority of patients were in second age group from 1 year to five years 35(53%) and the least in forth age group from 10 years to 15 years

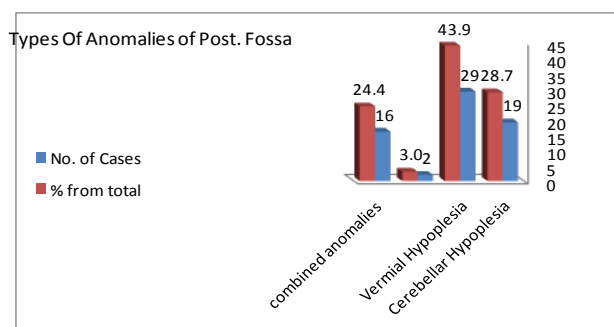


Figure 2 : Showing type of anomalies of the post. Fossa

Table 2: Show clinical presentation according to age groups

Age groups	No. of pts		Clinical presentation				
			Normal	epilepsy	speech deficit	motor deficit	cognitive deficit
more than 1month-1yr	12	1	7	non	5		1
more than 1yr-5yrs	35	4	19	27	28		23
more than 5yrs-10yrs	12	non	5	10	10		10
more than 10-15yrs	7	5	5	5	4		5

More than 1/3 of cases (43.9%) showing features of Vermian hypoplasia, dysplasia or total absent of the vermis

In table (2) show that the major age groups at time of presentation is the group of 1-5 years, and the major clinical presentation of this group is motor in 28(80%), then speech deficit in

27(77.1%) with cognitive dysfunction in 28(80%). Epilepsy in 19(54.3%), while in second age group less than 1 year epilepsy is the major presenting symptom, in third and forth age groups, the mode of presentation is the same as epilepsy, motor, speech and cognitive deficit.

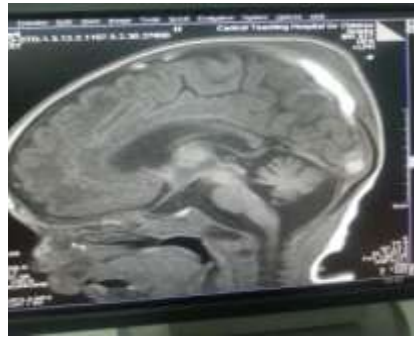

Fig 3: Saggital wt. image showing hypoplastic cerebellum, associated traumatic occipital hematoma in 3 years old male presented with ataxia

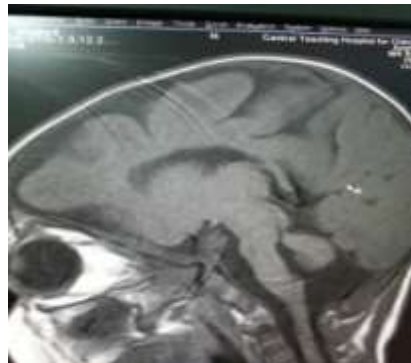

Figure 4: Show saggital spine Echo T1 weight image, of 5 months old boy with cerebellar dysgenesis.

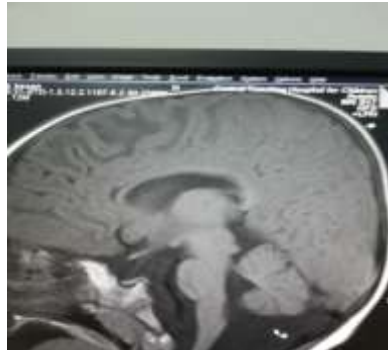

Fig 5: Saggital T1 wt. image showing moderate cystic dilatation of the posterior fossa communicating with the 4th ventricle.

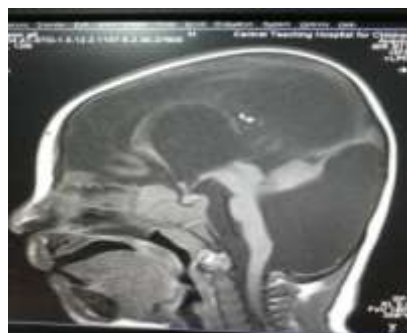

Figure 6: Show Dandy- Walker malformation with cystic dilatation of post. Fossa, hydrocephalus and vermian dysgenesis.

DISCUSSION:

The improved visualization of posterior fossa structures with MR imaging, has greatly increased the frequency recognition of cerebellar malformations. Neuro- imaging can clearly document the size of the cerebellum as well as adjacent regional posterior fossa anomalies.

Many classifications have been presented for cerebellar hemispheric abnormalities, but no one has been widely accepted⁽⁵⁾.

In our study, we included cerebellar hypoplasia, (which include the concept of focal or diffuse hypoplasia as well as cerebellar atrophy ,cerebellar atrophy is considered with shrunken folia and large fissures while cerebellar hypoplasia is an overall small cerebellum but normal size fissure when compared with the folia However ,it is not always possible to confidently differentiate between the two), vermian hypoplasia/dysplasia and Jobert syndrome, Cystic dilatation of the posterior fossa and Combined anomalies (Dandy walker variant)

Only one patient presented with the classical Dandy Walker malformation (a combination of vermian aplasia, cystic dilatation of the 4th ventricle and enlarged posterior fossa).

Cerebellar hypoplasia: is a rare embryonic developmental disorder in which the cerebellum is smaller than usual or not completely developed. The first known case of cerebellar hypoplasia was discovered in the year 1940 at autopsy^(6,7)

Wassmer E etal, describe clinical features of cerebellar hypoplasia as developmental or speech delay, Autistic features, ataxia, hypotonia and ocular signs⁽⁸⁾. But because of the wide variety of clinical entities, we describe, cognitive dysfunction, motor defect, speech defect and epilepsy, in addition we had six patients with abnormal neuro- imaging not suspected clinically.

Vermian hypoplasia/ dysplasia and Jobert syndrome:

The vermis represent the median part of the cerebellum between the two lateral hemispheres⁽³⁾ Jobert syndrome characterized by absent or underdeveloped cerebellar vermis with malformed brain stem, producing the typical molar tooth sign , causing varying degrees of physical, mental and sometimes visual impairment, there is no data available on incidence .The most common features include ataxia, hyperpnoea, sleep apnea and hypotonia.^(9, 10, 11, 12)

Clinical observation in our study describes

motor, speech defect and epilepsy, similar neurological findings described by Francesco B. etal⁽¹³⁾. Which include hypotonia and developmental delay as cardinal signs, in addition to ocular and other extra cranial manifestations, affecting the renal, hepatic and skeletal system in a comprehensive study of Jobert syndrome and related disorders.

Dandy walker variant: include the combination of retro- cerebellar posterior fossa CSF collection, together with cerebellar anomalies (vermian, cerebellar hypoplasia or dysgenesis) without enlargement of the posterior fossa. Sixteen patients showing such MRI radiological observation, with clinical presentation of motor defect, cognitive dysfunction, speech defect and epilepsy. Only one patient in our study fall in the category of the classic dandy walker syndrome, which include an enlarged posterior fossa, with cystic dilatation, severe vermian dysgenesis, and hydrocephalus .Dandy walker malformation is a rare congenital disorder, approximately 80 % of patients have hydrocephalus^(14,15). The later was observed in the literatures, in a retrospective study of 70 patients of a wide range age groups ,from few days to young adult , 10 patients with features of Dandy walker malformation observed, the study, was spanned 15 years⁽⁵⁾ on the other hand we included only the pediatric age group in a prospective study along a period of only 18 months .

Our data included Isolated posterior fossa CSF csf collection in tow patients, these show free communication with the 4th ventricle and categorized as prominent cisterna magna of incidental finding without neurologic deficit, this is possibly attributed to a normal growth adjacent cerebellar hemisphere without mass effect. AJ Barkovich etal,⁽¹⁶⁾ present four cases, of which three being symptomatic posterior fossa cyst with no communication with the 4th ventricle, but show definite size related mass effect.

Controversy remains around wheather mega cisterna magna is a normal anatomical variant or due to volume loss of the cerebellum.⁽¹⁷⁾ Understanding the development of posterior fossa and 4th ventricle is essential for understanding posterior fossa malformation.⁽¹⁸⁾

The overall clinical and radiological evidence in our study indicates that cerebellar anomalies with or without posterior fossa CSF collections are part of an overlapping spectrum that have a related embryologic origin, all being treated conservatively ,unless obstructive hydrocephalus

present in, which CSF catheter diversion being placed .

CONCLUSION:

The spectrum of developmental disorders of the cerebellum, held an apparent variable clinical manifestations . Using MRI Neuro –imaging, is the basic modality of choice provides a key element in characterizing most cerebellar anomalies. It provide an accurate visualization of the cerebellum and associate structures, which in term determine which form of malformation has taken especially with the lack of easy availability of the required cytogenic analysis.

REFERENCES:

1. Coffman,k.a ,Dum , R.P & Stirik, P.L"cerebellar ermis is a target of projection from the motor areas in the cerebal cortex".jProceedings of the National Academy of Science of the United States Of America 2011;108:16068..
2. Mario Ubaldo Manto,: Malformations, classification of cerebellar malformations.,: In, Cerebellar Disorders': Practical Approach to Diagnosis and Manegment,published in Cambridge University Press; 1stedition 2010: 79.
3. Samuel C. Ohaegblam, HishamAfifi. Dandy Walker Syndrome: IncidenceIn a Defined population of Tabuk, Saudi Arabia. Journal Neuro epidemiology 2001; 20:150- 52.
4. Laila A. Selim 1, Maha S., Zaki 2, et al. Developmental abnormalities of mid and hind brain: A study of 23 Egyptian patients. Egypt.J. Med. Hum. Genet. 2008; 9.
5. Sandeep Patella and A. James BarkovichaAnalysis and classification of Cerebellar malformations. American Journal of Neuroradiology.2002.23: 1074-1087 PEDIATRICS.
6. Lemon,R.N.,Edgley, S,A . Life without cerebellum. Oxford Journals, 2010;133: 652-54 .
7. National institute of Neurological disorders and strock: what is cerebellar hypoplasia updated Sep. 2011.
8. Wassmer E, Davies P, White Housewp, Green SH. ,Clinical Spectrum associated with cerebellar hypoplasia.Ped. Neurol. J. 2003;28:347- 51.
9. Merritt L., Recognition of the clinical signs and symptoms of Joubert syndrome; Adv Neonatal Care .2003;3:178 – 86.
10. Saraiva, JM ;Baraitser, M "Joubert syndrome : a review "American Journal of Medical Genetics 1992;43:726-31.
11. Doherty D. ,Jobert Syndrome, insights into brain development, C.Liumbiology,and complex disease.Ped.Neurol. 2009;16:143 - 54.
12. Neurology Liaison Nurse specialist in collaboration with child and familyinformation :www.cofamily.org.uk. ref: 2012fo708 July 2012.
13. Francesco Brancati, Bruno.Dallapiccola and Enza Maria valenti : Joubert Syndrome and related disorders.Urphanet Journal of rare disease 2010;5:20.
14. LutfiIncesu, MD, James G. Smirniotopoulos ,et al.Imaging in Dandy –Walker Malformation.Medscape ,updated May 2013.
15. Aldinger KA, Lehmann UJ.,Hudgin SL, et al FOXCI is required for normal cerebellar development and is a majorcontributor to chromosome 6p25.3 Dandy Walker Malformation , 2009;41:1037 -42 .
16. AJ Barkovich,Bokjos, D Norman et al. revised classification of posterior fossa cyst and cyst like malformations based on the result of multiplannar MRI imaging. American Journal of Roentgen ology . 1989;1531298 -1300.
17. EpelmanM, Daneman A, Blaser SI, Ortiz-neiraC , et al, Differential diagnosis of intracranial cystic lesion at Head U/S : correlation with CT , and MRI imaging .Radiographics; 2006;26: 173- 96. RASNA ,.
18. Shekdar K; Posterior Fossa Malformation; seminars in Ultrasound CT and MRI Journals ; 2011;32: 228-41.

