

Prevalence and pathological study of schistosomiasis in sheep in Akra/Dohuk province, northern Iraq

I.K. Zangana¹ and K.J. Aziz²

¹ Department of Clinical Science, College of Veterinary Medicine, Dohuk University,

² Department of Animal Resources, College of Agriculture, Salahaddin University, Iraq

Abstract

The occurrence of Schistosomiasis was detected by fecal examination (Formalin- ether centrifugalsedimentation technique) and abattoir Survey during a period from October 2006 to March 2007, and histopathological study. *Schistosomabovis* was identified with prevalence rate 11.37% by fecal examination where as 1.6% by abattoir survey. Diseased animals exhibited acute clinical signs, which included emaciation, sunken eye, pale mucus membrane and diarrhea. The Infections was more prevalent in age 1-3 years 15.9%. The histopathological findings reveal characteristic lesions in blood vessels and some tissues including thrombosis in veinules and mesenteric vein and minute granuloma around the eggs in portal area and fatty necrosis in the liver, cystic structure of some mucosal glands of the intestine containing eggs, with infiltration of mononuclear inflammatory cells in different tissues.

Keywords: Schistosomiasis; Sheep; Prevalence.

Available online at <http://www.vetmedmosul.org/ijvs>

نسبة حدوثية ودراسة مرضية لمرض البلهارزيا في الاغنام (قضاء عقرة/ محافظة دهوك) شمال العراق

احسان قادر زنكنة^١ وخالد جبار عزيز^٢

^١ فرع الطب الباطني، كلية الطب البيطري، جامعة دهوك، ^٢ قسم الثروة الحيوانية، كلية الزراعة، جامعة صلاح الدين، اربيل، العراق

الخلاصة

اجريت الدراسة في منطقة عقرة التابعة لمحافظة دهوك للفترة من تشرين الاول ٢٠٠٦ ولغاية اذار ٢٠٠٧. اذ تم فحص براز الحيوانات باستخدام طريقة الترسيب بالايثر- فورمالين للتحري عن البيوض وكذلك اجري التحري عن الديدان البالغة في الحيوانات المذبوحة في المجزرة. اظهرت الاغنام المشكوك باصابتها سريريا علامات سريرية تمثلت بالهزال، والعين الغائرة وشحوب الاغشية المخاطية كما عانت بعض الحيوانات المصابة من الاسهال. تم تحديد نوع واحد من الطفيلي *Schistosoma bovis* والذي شخص اعتمادا على المظهر الخارجي للديدان البالغة وشكل البيوض وكانت نسبة انتشار المرض ١١,٣٧%، وسجلت اعلى نسبة في الاغنام بعمر ١-٣ سنة وبلغت ١٥,٩٧%. لوحظ ان ١٢ (١,٦%) م الاوردة المساريقية للاغنام المذبوحة كانت حاوية على ديدان بالغة. اظهر الفحص النسيجي للاغنام المصابة افات في الاوعية الدموية وبشكل بؤر نخرية حول البيوض في المنطقة البوابية للكبد فضلا عن تنكسات دهنية في الخلايا الكبدية. وظهرت بعض الغدد المخاطية للأمعاء وجود توسعات كيسية حاوية على البيوض مع ارتشاح للخلايا وحيدة النواة مابين تلك الغدد.

Introduction

Schistosomiasis is a common parasitic infection in animal, mainly in cattle in Africa and Asia, its estimated that at least 165 million animals infected (1). Out of 10 species reported to naturally infect cattle only, *Schistosoma mattheei* and *S. bovis* have received particular attention, mainly because of their recognized veterinary significance (2).

Schistosomabovis is a species' whose final hosts are bovines, ovines, caprines and whose secondary hosts are small wild ruminants they are distributed throughout Africa, south west Asia and Mediterranean, Europe. Different studies have demonstrated the analogies existing between *S. bovis* and other *Schistosoma* species which affect humans. The similarities include

morphological, ecological, physiological and genetic aspects (3-5).

In Iraq the infections with *S. bovis* at the first time is recorded by (6) in cattle, sheep, goat and equine. Also a survey was carried out on a parasitic infection among animals indifferent provinces of Iraq by (7). The *S. bovis* was found in cattle, sheep, goats and the intermediate hosts were found to be respectively, *Bulinustruncatus* and *limnaeaephatica*, while (8) recorded two types of Bilharzias in Iraq (*S. bovis*, *Orinthebilharziaturkestanicum*).

There are considerably fewer publications on ovine Schistosomiasis in Iraq and also due to two outbreaks of the disease recently occurred during 2004-2005 among the sheep in one district (Akra) Duhok province North of Iraq. These two reasons encouraged to plan this study.

Materials and methods

Epidemiological Data

The study was conducted in Akra (a district located 90km north east of Mosul province). Sheep (90% Karadi breeds) at this area graze on the natural pasture near the several rainfall pools, drains, rice field and temporary streams which distributed in this area.

Full objective information obtained which was arranged in a sheet of questionnaire form including data of sex, age, flock, size, morbidity and mortality rates.

Sampling

Field samples

A total of 290 fecal samples were taken from 32 flocks of sheep in 16 different villages from October 2006- March 2007. Samples were kept in a clean dry container without contamination for one or more days at refrigeration, until examination.

Abattoir samples

A total of 1130 mesenteric vessel of sheep were examination thoroughly by visual inspection, by holding the mesentery for the detection of adult parasite to the light and were readily recognized black streak of digested blood in their gut of adult worm Fig.1.

The adult worm was collected from mesenteric vein and washed several times by normal saline and preserved in ethanol 70% for morphological description. Also samples from organs (Liver, mesenteric vessels, intestine, Lung and lymph nodes) were taken from those infected animals (In depending on the observation of adult worm in mesenteric veins) and fixed in 10% saline formalin for histopathological study (9) histotechnique was applied for histological examination.

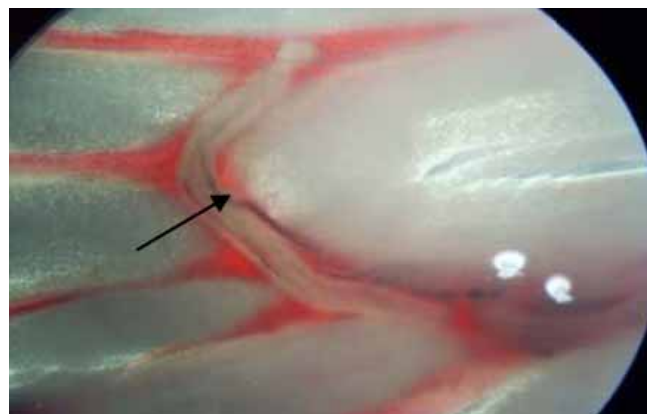


Figure (1): Mesenteric vein contain adult worm of *S. bovis* (↑), black streak of digested blood in their gut.

Coprolological examination

Sedimentation test: (Formalin-ether centrifugal sedimentation) Formalin-ether technique was used for effective concentrating eggs in feces as method described by (10). The shape and size of egg was determined by using ocular micrometer lens applying method of (11).

Results

Clinical findings

Diseased animals show unthriftiness, loss of conditions, anorexia, intermittent diarrhea, mixed with blood, dehydration, sunken eyes, more over severe emaciation and thirst were also encountered. Systemic reactions was mild however pale mucous membrane, polypnea and nasal discharge were also seen.

Parasitological findings

The morphological feature of isolated adult worm was evaluated. The average length of adult male was (16.7 ± 1.3 mm) and it had two suckers (oral and ventral) and distinct gynacophoric canal and 3-6 testicles situated behind the ventral sucker, and in all specimens showed male holding the threadlike female in gynacophoric canal Fig.2. The egg was elongated spindle shaped with large terminal spine. The average size of the eggs was 266 ± 11.6 μ m length and 58 ± 3.7 μ m width Fig.3.

Abattoir findings

Result of abattoir survey show that out of 1130 mesenteric vein examined 12 (1.06%) were appeared infected with adult worms (Table 1). The rate of infection was taken similarity among the periods of survey as shown in table (4). The rate was (0.52%), (1.05%), (1.94%), (1.53%), (1.07) in October, November, December, January and February, respectively, however no worm were detected in March 2007.

Table (1): Prevalence rate of *Schistosomabovis* in sheep.

Type of exam.	Type of sample	No. sample exam.	No. sample positive	Percentage %
Microscopically exam.	Feces	290	33	11.37
Visual inspection.	Mesenteric vessels	1130	12	1.06

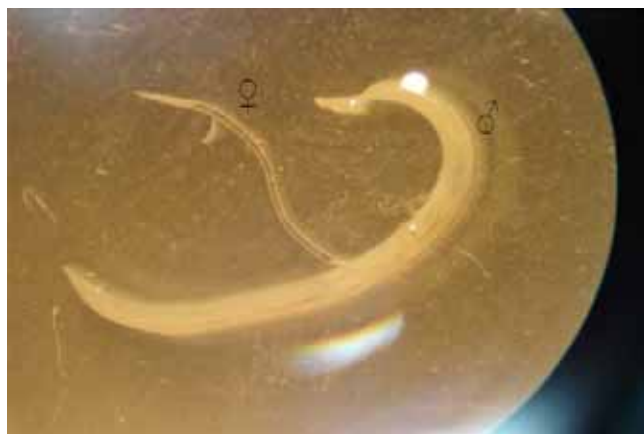

Figure (2): Male (♂) and female (♀) *Schistosomabovis*. 40X dissecting microscope.

Field finding:

Out of 290 fecal samples of suspected sheep 33 (11.37%) were passed feces with typical eggs which were detected microscopically (Table 1). Highest rate (27.45%) was detected on January 2006 where as the lowest (9.75%) in November 2006, moreover no infection rate have been recorded in October 2006 and March 2007 (Table 2). According to the age of animals, results show that animals aged 1-3 year were highly infected (15.97%) whereas animals aged above 3 years have low infection rate (10.75%). Moreover no infection have been recorded in young animals under one year old. (Table 3).

Table (2): Prevalence rate of *Schistosomabovis* from fecal sample in sheep related to different months.

Months	No. of samples	No. of + ve samples	Percentage of positive sample (%)
October 2006	52	0	0
November 2006	41	4	9.75
December 2006	56	6	10.71
January 2007	51	14	27.45
February 2007	48	9	18.75
March 2007	42	0	0
Total	290	33	11.37

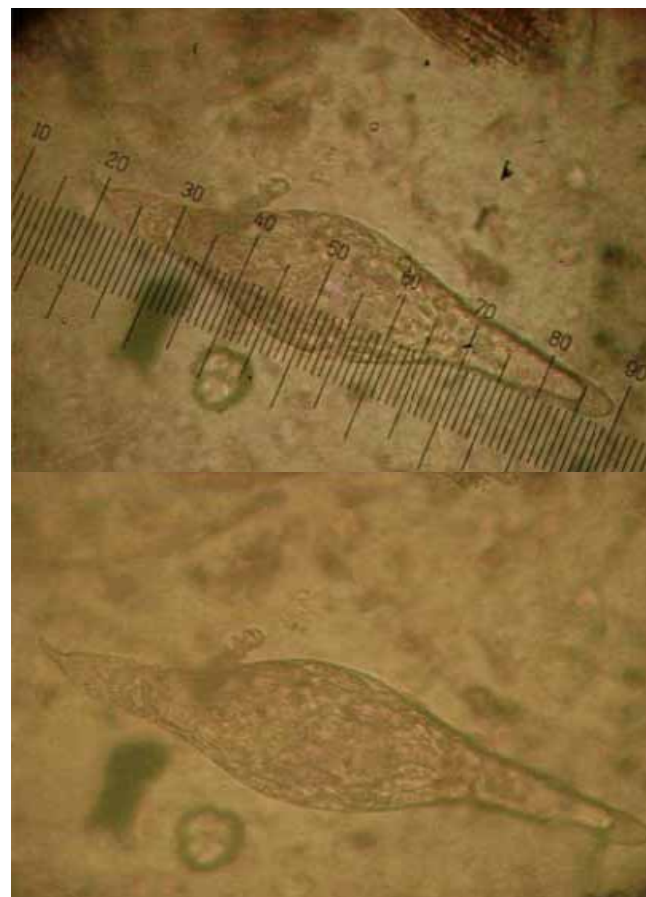


Figure (3): The egg of *S.bovis*; spindle, elongated shape containing fully developed miracidium, and showing long terminal spine.

Table (3): Prevalence of *Schistosomabovis* infection according ages in sheep.

Age Groups	No. of animal examined	No. Infected animal	Infection %
Under 1 Year	53	0	0
1—3	144	23	15.97
Above 3 years	93	10	10.75
Total	290	33	11.37

Table (4):Prevalence rate of *S.bovis* from Akra abattoir in sheep related to different months.

Months	No. of samples	No. of + ve samples	Percentage of positive sample (%)
October 2006	172	1	0.58
November 2006	189	2	1.05
December 2006	206	4	1.94
January 2007	196	3	1.53
February 2007	186	2	1.07
March 2007	181	0	0
Total	1130	12	1.06

Histopathological findings

Liver

Hepatic tissue sections showed fibrosis in portal area and associated with congestion and coagulative necrosis in surrounded portal area, moreover vascular degeneration and fatty change had been seen in hepatocytes. Fig4.

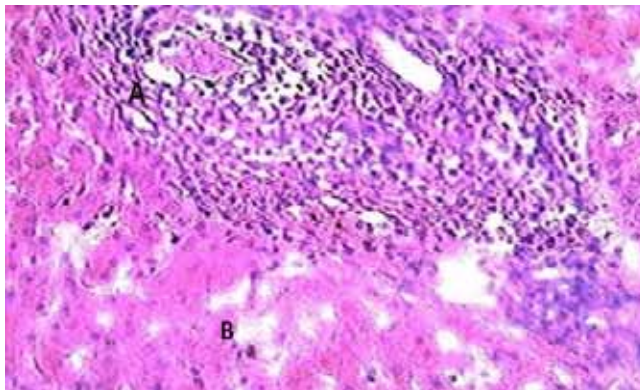


Figure (4): Histological section of liver from infected sheep revealed fibrosis infiltrated with mononuclear inflammatory cells around the egg of *Schistosomabovisin* portal area (A), associated with fatty change (B). H and E 400x.

Intestine

The infected intestine revealed sever necrosis in mucosa and sub mucosa, and degeneration of epithelial villi and hyperplasialining of sub mucosal glands, some of which changed into the compact mass, while others changed into cystic structure containing eggs of parasite. Fig. 5.

Mesentery and mesenteric vein

The histopathological change of mesentery arterioles and veinliols revealed sever congestion and thrombophelbitis and deposition of the eggs with filtration of mononuclear cells and fatty necrosis Fig.6 and 7. However thickening in the wall of arterioles, presence of parasite in lumen of vein, inflammatory cells mixed with

deposition of eggs and cross section of adult parasite in lumen of vein have been also detected. Fig. 8.

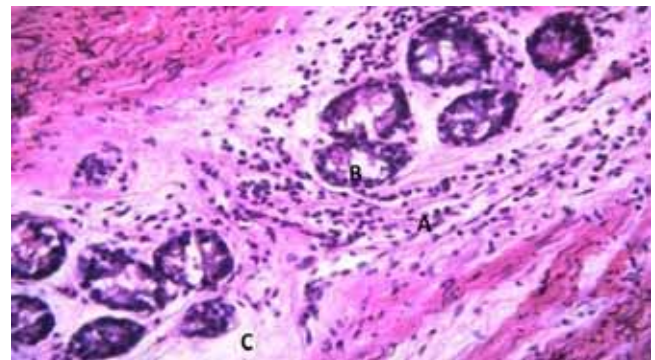


Figure (5): Histological section from intestine of sheep revealed fibrous tissue infiltrated by mononuclear inflammatory cells surrounded mucosal gland (A), hyperplasia in epithelial lining mucosal gland (B), atrophied compact gland (C). H and E 400x.

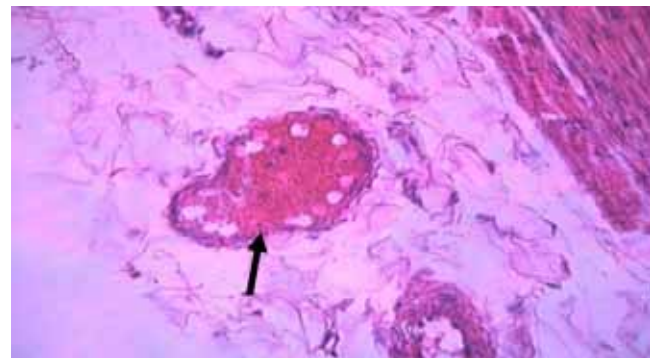


Figure (6): Histological section of mesentery revealed presence of thrombus in veinule (↑). H and E 400x.

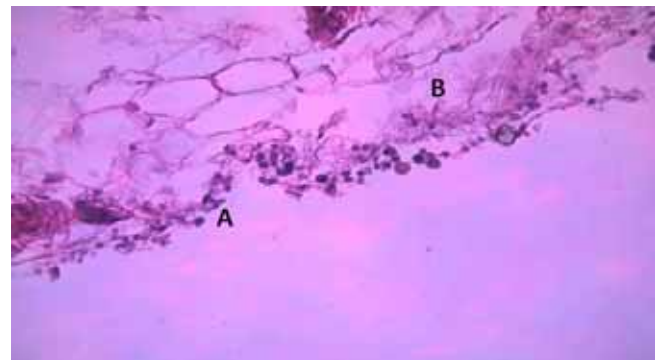


Figure (7):Histological section from mesentery of sheeprevealed presence of*Schistosoma* egg associated with infiltration of mononuclear inflammatory cells (A) and fatty necrosis (B).H and E 400x.

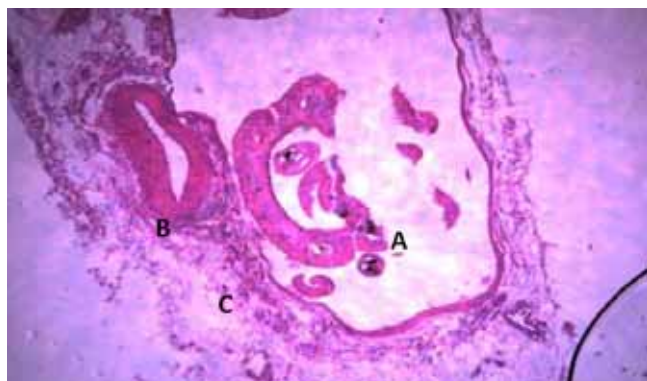


Figure (8): Histological section from mesenteric vein revealed cross section of parasite (A), thickening in wall of arterioles (B), infiltration of inflammatory cells around the wall (phlebitis) (C). H and E 400x.

Lung

There was emphysema with bronchopneumonia, severe congestion in pulmonary arteries and hyperplasia in the epithelial lining of bronchioles. Fig. 9.

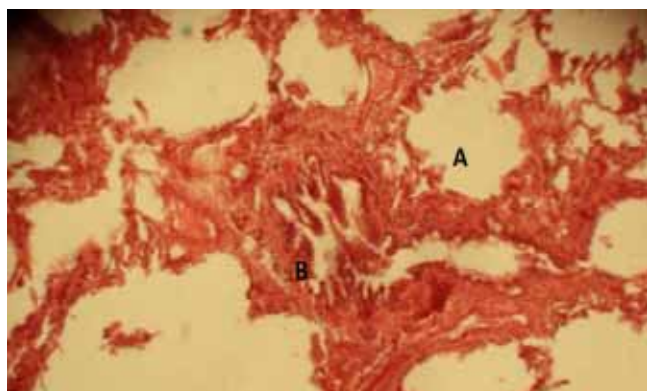


Figure (9): High magnification of above figure revealed some pathological lesions represented by emphysema (A) and severe congestion, in pulmonary arteries and hyperplasia in epithelial lining of bronchioles (B). H and E 400x.

Lymph nodes

There was depletion in some secondary lymph node follicle, periarteritis and infiltration of mononuclear inflammatory cell (monocyte) in medulla of the lymph node. Fig.10.

Discussion

During last two years (2005-2006) outbreaks of Schistosomiasis in sheep occurred in the region of Akra, Duhok province, north of Iraq. At this area the distribution

and ultimatum of aquatic snails had been propagated the different flukes infection among live stock. Studies of Schistosomiasis in Iraqi animals are very scarce and little information have been provided, there for the present study was carried on this disease more epizootically dealt, the study depend on fecal examination, abattoir survey and on basis of morphology of adult parasite and eggs, similar steps were followed by many authors (12-14).

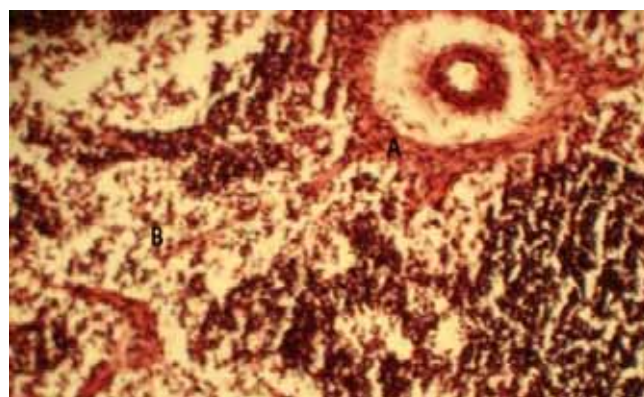


Figure (10): High magnification of above figure revealed periarteritis (A) and infiltration of mononuclear inflammatory cell (monocyte) in medulla (B). H and E 400x.

Accordingly detection of *S.bovis* was proved the cause of Schistosoma infection in this region this species reported by Lepier in 1975 from different province of Iraq. The parasite were also observed by (15) from mesenteric vein of cattle in slaughter house of Dyala province at rate of 0.94%.

Results indicated that the infection rate was high in January and low in November, this variability in rate may be due to amount of rainfall, ambient temperature and drought condition which depended on establishing of water reservoir for propagation of snails which were intermediate hosts.

High infection rate which were detected in animals of 1-3 year old were agreed with (16) whom registered high infection with Schistosomiasis in enzootic area of central Sudan.

Acute Schistosomiasis found in this study, this signs due to high morbidity and mortality and severity of condition depend on the distribution of mature worms and on egg deposited in tissues. Some explanation of acute occurrence of acute infection had been given by (17).

Through the histological finding in different organs proved the acuteness of infection, the basic lesion was phlebitis due to the death of adult parasite, loading in blood vessels in the liver, lung and intestine these changes were recorded by (18), whom mention that severe infection causes consolidation and fibrosis of liver with the presence of

massive thrombosis in the portal vessels and local infiltration of multi nucleated in the liver parenchyma and around the portal veins in addition the large numbers of worms in visceral and portal veins caused phlebitis and the presence of eggs in the intestine causes inflammatory response.

The mesenteric vein revealed thickening in the wall of arteriole and adult parasite in the lumen of vein and infiltration of inflammatory cells mixed with deposition of eggs, these also were mentioned by (19).

References

1. De Bont J, Vercruysse J. The epidemiology and control of cattle schistosomiasis. *Parasitol Today*. 1997; 13:255-262.
2. Taylor M G. Schistosomes of domestic animals: *Schistosomabovis* and other animal forms. In immunology, Immunoprophylaxis and immunotherapy of parasitic infection. Ed Soulsby E.J.L. Boca Raton, Florida: CRC Press. 1987; 2: 49-90.
3. Camacho M, Agnew A. Glucose uptake rate by *Schistosomamansoni*, *S. haematobium* and *S. bovis* adults using a flow in vitro culture system. *J. Parasitol.* 1995;81:637-640.
4. Barber K E, Mkoji G M and Loker E S. PCR-RFLP analysis of the ITS2 region to identify *Schistosomahaematobium* and *S. bovis* from Kenya. *Am. J. Trop. Med. Hyg.* 2000;62:434-440.
5. Hamburger J, He-Na I, Abbasi R M, Ramzy J, Jourane, and Ruppel A. Polymerase chain reaction assay based on a highly repeated sequence of *Schistosomahaematobium*: a potential tool for monitoring schistosome infested water. *Am. J. Trop. Med. Hyg.* 2001; 65:907-911.
6. Machattie C. (1936) The relation between Schistosomiasis (Bilharziasis) in domestic animals and man as observed in Iraq. Ph.D. Thesis submitted to veterinary faculty, university of Zurich. Cited by AL-Biaty (2000).
7. Leiper R T. Report on the IV. Survey of parasites and their control. FAO, (1957); 57/3/1673 :4-23.
8. Al- Barrak N S, Wajdi N and Fadhil S. Observation on Schistosomes parasitic in cattle in Iraq. *Iraq. J. Biol. Sci.*, 1977; 5(1):69-80.
9. Bancroft J D, Stevens A. Theory and practice of Histological Techniques. 4th Ed. Churchill Livingstone. 1999; 127-129.
10. Lynne S G A B, Lawrence R A. Diagnostic parasitology, parasite identification. 2nd Ed. The C.V. Mosby co; Missouri, U.S.A. 1979.
11. Pantin C F A. Notes on Microscopical Techniques for Zoologists. 6th Ed. Cambridge Uni. Press. 1964; Pp: 77.
12. Hamilton J V, Klinkert Mand Doenhoff M J. Diagnosis of Schistosomiasis: anti body detection, with notes on parasitological and antigen detection method. *Parasitol.* 1998; 117(suppl):s41-s45.
13. Allen G P, Adrian C S, Richard O G, Gail M Wand Donald P M. Schistosomiasis. *The New England Journal of Medicine*. 2002; Vol.346, No.16 :1212-1220.
14. Corachan M. Schistosomiasis and international travel. *Clin. infect. Dis.* 2002;35:446-450.
15. AL-Biaty S H. Epidemiological study of *Schistosomahaematobium* in Baladrooze sub province. M.sc. thesis submitted to the council of the college of veterinary medicine at the University of Baghdad, 2000.
16. Majid A A, Hussein M F and Taylor M G. Age specific prevalence and intensity of *Schistosomabovis* infection in Sudanese Desert sheep in the White Nile Province. *Res Vet Sci.* 1983; 35(1):120-1.
17. Dargie J D. The pathogenesis of *S. bovis* infection in Sudanese cattle. *Trans. R. Soc. Trop. Med. Hyg.* 1980;74: 560-562.
18. Lindberg R, Johansen M V, Nitsson C and Nansen P. An immunohistological study of phenotypic characteristics of cells of the inflammatory response in the intestine of *Schistosomabovis* infected. *Parasitol.* 1998;118: 91-99.
19. Jones T C, Hunt R D and King N W. *Veterinary Pathology*. 6th Edition. Lippincott Williams and Wilkins A Wolters Kluwer Company. London. 1997; 664-667.