Tikrit Journal for Agricultural Sciences (2024) 24 (3): 74-84
DOI: https://doi.org/10.25130/tjas.24.3.7

IRAQI Academic Scientific Journals
العراقية المجلات الأكاديمية العلمية

ISSN:1813-1646 (Print); 2664-0597 (Online)
Tikrit Journal for Agricultural Sciences
Journal Homepage: http://www.tjas.org
E-mail: tjas@tu.edu.iq

TJAS

A Therapeutic and Protective Effect of Silymarin against Hepatotoxicity Induced by Cisplatin in Female Rats

Measer A. Ahmed

Department of Biology, College of Pure Science, Tikrit University, Iraq

*Correspondence email: dr.measerahmed@tu.edu.iq

KEY WORDS:
Silymarin, Cisplatin, Hepatotoxicity, Oxidative stress, Antioxidant

Received: 19/01/2024
Revision: 16/05/2024
Proofreading: 22/08/2024
Accepted: 08/07/2024
Available online: **30/09**/2024

© 2024.This is an open access article under the CC by licenses http://creativecommons.org/licenses/by/4.0

ABSTRACT

This study aimed to elucidate the promising potential of silymarin in ameliorating the side effects associated with toxic pharmaceuticals. The study involved thirty female rats obtained, housed and maintained under requisite laboratory conditions in animal house unit in college of veterinary medicine, University of Tikrit. Rats distributed into six groups five rats per group to investigate the effects of Cisplatin and silymarin on various biochemical markers over a 21-day period. The groups included a control group, two induction groups receiving Cisplatin 5mg/kg on first and last days, a silymarin group 150mg/kg orally per day, a therapeutic group included Cisplatin 5mg/kg i.p. and silymarin 150mg/kg, and a protective group treated silymarin 150mg/kg and Cisplatin 5mg/kg administration in last day. This experimental study aimed to evaluating the effect of cisplatin and silymarin administration for 21 days on some physiological and histological parameters in rats included Alanine transaminase ALT, Aspartate aminotransferase AST, Glutathione peroxidase GPx, Glutathione GSH, Superoxide dismutase SOD, Malondialdehyde MDA levels, and histological changes in liver tissue. Results demonstrated the adverse effect of cisplatin on ALT, AST, GPx, GSH, SOD levels and liver tissue also demonstrated the protective and therapeutic potential effect of silymarin against oxidative stress and hepatotoxicity induced by cisplatin due increase GPx, GSH, SOD and decrease MDA, AST levels, also enhanced liver tissue. From the results we conclude the potential protective and therapeutic role of silymarin against hepatotoxicity and oxidative stress induced by cisplatin.

التأثير العلاجي والوقائي للسلمارين ضد السمية الكبدية المستحثة بواسطة السيسبلاتين في اناث الجرذان

ميسر عبدالله احمد
قسم علوم الحياة، كلية التربية للعلوم الصرفة، جامعة تكريت، العراق

الخلاصة

تهدف هذه الدراسة إلى توضيح الإمكانيات الواعدة للسيليمارين في تحسين الآثار الجانبية المرتبطة بالأدوية السامة. شملت الدراسة ثلاثين جرذاً من الإناث تم توزيعها على ست مجموعات لفحص تأثيرات السيسبلاتين والسيليمارين على مؤشرات بيوكيميائية متنوعة على مدى فترة 21 يومًا. تضمنت المجموعات مجموعة السيطرة ومجموعتين استحداث للسمية تم معاملتهم بالسيسبلاتين في اليوم الأول واليوم الأخير، ومجموعة سيليمارين، ومجموعة علاجية تلقت السيسبلاتين والسيليمارين، ومجموعة وقائية تلقت السيليمارين ومن ثم إعطاء السيسبلاتين في اليوم الأخير. تم تقييم تأثير هذه المعاملات على مؤشرات ALT، AST، GPx، الجلوتاثيون، SOD، MDA، والتغييرات النسيجية للكبد. أظهرت النتائج تأثيرات سلبية للسيسبلاتين على بعض المؤشرات، وإمكانية تأثيرات وقائية للسيليمارين، خاصة في التخفيف من الاجهاد التأكسدي الناتج عن السيسبلاتين. قامت الدراسة بفحص تأثير المعاملة بالسيسبلاتين والسيليمارين على المؤشرات البيوكيميائية في الجرذان على مدى 21 يومًا. أدى إعطاء السيسبلاتين إلى ارتفاع في مستوياتALT ، AST، GPx، MDA، وأضرار في نسيج الكبد. أظهر السيليمارين، عند إعطائه بالتزامن مع السيسبلاتين، تخفيفاً لهذه التأثيرات، مما يشير إلى الفعالية الوقائية. من بين النتائج الملحوظة زيادة في مستويات GPx والجلوتاثيون وانخفاض في مستويات MDAوتحسن في نسيج الكبد في المجموعات التي تلقت السيليمارين. تشير هذه النتائج إلى إمكانية الدور الوقائي للسيليمارين ضد الأضرار النسجية الناتجة عن السيسبلاتين والاجهاد التأكسدي.

الكلمات المفتاحية: السيليمارين ، السيسبلاتين ، السمية الكبدية ، الاجهاد التأكسدي ، مضادات الاكسدة

INTRODUCTION

The use of medicinal herbs as adjuvant therapeutic agents to mitigate or prevent drug toxicity has received increasing attention recently (Al-Obaidi,2022). This interest comes from the rich cultural and historical tradition of folk medicine. The reason behind inclusion medicinal herbs into traditional medicine lies in their diverse bioactive components show antioxidants, anti-inflammatory, and cytoprotective properties. (Viktorová *et al*.,2019; Chambers *et al*.,2017). Since pharmaceutical interventions, although effective, may lead to unintended adverse effects and toxicity, silymarin represents a proactive approach to improve therapeutic findings while decreasing adverse effects of drugs (Zaker-Esteghamati, et al.,2020). Silmarin has complex chemical compounds that may work synergistically with drugs, and modulates the cellular response to alleviate oxidative stress and inflammatory pathways caused by drug use. (Gupta *et al*.,2000).

This study explores the use of silymarin as a preventive or therapeutic supplement to prevent drug-induced toxicity. We aimed to elucidate the promising potential of herbal interventions in improving cisplatin-related side effects

The increasing prevalence of cancer has led to increased dependence on chemotherapeutic drugs, with cisplatin emerging as a prominent chemotherapeutic agent. (Choudhari *et al*.,2020). However, its effectiveness is marred by severe side effects, necessitating the exploration of alternative substances such as Silymarin. This study seeks to investigate the multifaceted impact of Silymarin on Cisplatin-induced hepatotoxicity.

METHODS AND MATERIAL

Experimental design

In this investigation, thirty female rats, weighing between 195 - 210 grams and aged between 10 to 12 weeks, were obtained and housed in plastic cages within the animal housing facilities at the Faculty of Veterinary Medicine, University of Tikrit, and maintained under requisite laboratory conditions with a 12 h/12 h light–dark cycle at room temperature (22–25 C) . Animals were given food and water ad libitum for a duration of 21 days. All the experimental procedures were carried out in accordance with international guidelines for care and use of laboratory.

The subjects were distributed into six distinct groups five rats per group, each receiving specific treatments, as following: control group administrated orally with distilled water 1 ml per rat, second and third group (induction group) administrated with a Single intraperitoneal injection of Cisplatin 5mg/kg (Hassan *et al*,2019) at day 1and day 21 respectively, fourth group intervened with silymarin 150 mg/kg per day (Amien *et al*, 2015), fifth group (therapeutic group) administrated with single dose of Cisplatin 5mg/kg at day 1 and silymarin 150 mg/kg per day for 21 days, and sixth group (protective group) administrated with silymarin 150 mg/kg for 21 days and single dose of Cisplatin 5mg/kg at day 21

Serum preparation

At the end of the experimental period, the animals were starved for 24 hours. Subsequently, the animals were anesthetized with chloroform, and blood samples were collected from the jugular vein. The blood was placed in Gel tubes and maintained at room temperature for 30 minutes. Afterward, a centrifuge was utilized at a speed of 3000 rpm for 15 minutes to obtain the serum. Sera then stored in a deep freeze at a temperature of -80 degrees Celsius.

Biochemical tests

In this study, the following biochemical tests were conducted:

Aspartate aminotransferase (AST) and alanine aminotransferase (ALT): The activity of the ALT and AST in serum were measured using the colorimetric method. The colored oxalate derivative was produced as a result of the reaction between oxalates and 2-4 dinitrophenylhydrazine 2-4-Dinitrophenylhydrazine (Guder.,2012).

Glutathione (GSH) estimation: The concentration of glutathione in the serum was determined using the Ellman's reagent method (Ellman.,1959).

Superoxide dismutase (SOD) estimation: Enzyme activity estimated according to Modified photochemical Nitro blue Tetra zolum method (Brown and Godstein.,1983).

Glutathione peroxidase (GPx) estimation: concentration estimation was based on (Baumber and Ball.,2005).

Malondialdehyde (MDA) estimation : concentration estimation based on the reaction of MDA with TBA in a medium influenced by the pH level, resulting in a pink-colored compound absorbance read at a wavelength of 532 nm (Senthilkumar et al.,2021).

Histological study preparation: The liver tissue was promptly fixed in 10% formalin for 24 hours. Subsequently, it underwent a water wash followed by dehydration using a series of alcohol concentrations. The samples were then cleared, infiltrated, and embedded in paraffin. The paraffin-embedded tissue was sectioned to a thickness of 5µm using an electric rotary microtome. The resulting sections were stained with hematoxylin and eosin and examined under a light microscope (Bancroft and Gamble.,2002).

Statistical analysis

Data analyzed using SPSS version 2.0 and Microsoft Excel 2013, with results expressed by means ± SD. Results analyzed by One-way ANOVA and the significant differences among means were estimated using Duncan multiple range tests. Significant value was P≤0.05 (Dawson and Trapp.,2001).

RESULTS AND DISCUSSION

The results showed that there were no significant differences in the group treated with cisplatin on the first and last day in the level of ALT compared to the control, while there was an increase in the level of ALT in the group treated with cisplatin on day 21 with silymarin. Also, an increase in the level of AST was observed in the cisplatin group on day 21 and the group. Cisplatin with silymarin on day 21 compared to control.

Administration with cisplatin on the first day led to a significant decrease in the level of GPx, while no significant differences appeared in the cisplatin group on day 21 compared to the control. Treatment with silymarin and cisplatin in both groups led to a significant increase in the level of GPx compared to the group treated with cisplatin. Administration rats with silymarin and cisplatin on day 21 increased level of GSH compared to group treated with cisplatin on day 21, while other groups showed no significant difference. Cisplatin on day 1 decreased of SOD and increased MDA levels while silymarin administration improved its ability to enhance antioxidant activity via increase SOD level.

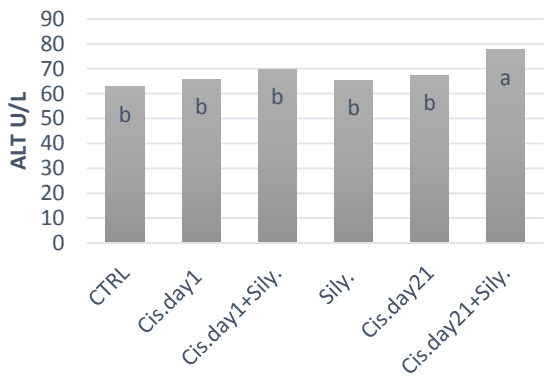

Fig.(1) . Effect of treatments in ALT level.

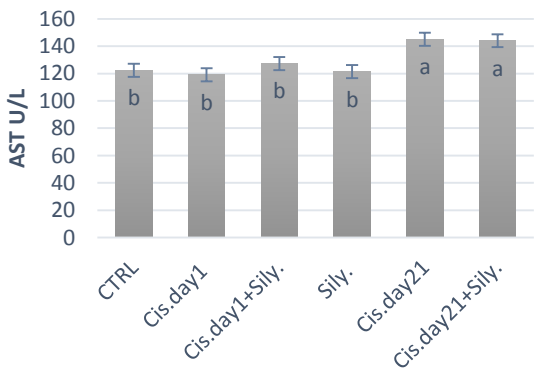

Fig.(2) . Effect of treatments in AST level.

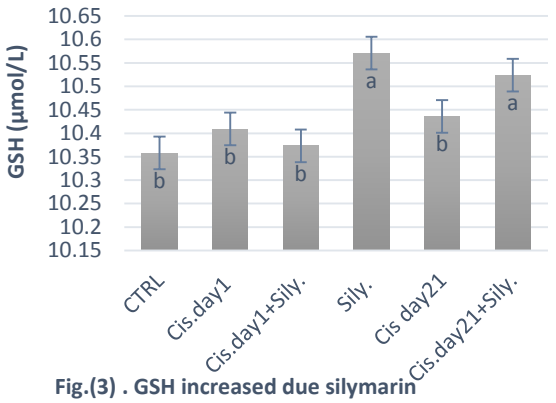

Fig.(3) . GSH increased due silymarin treatment.

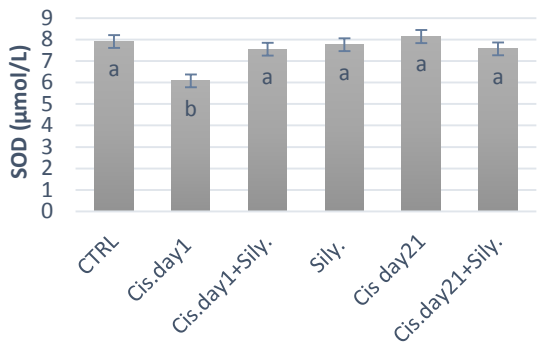

Fig.(4) . SOD activity in serum

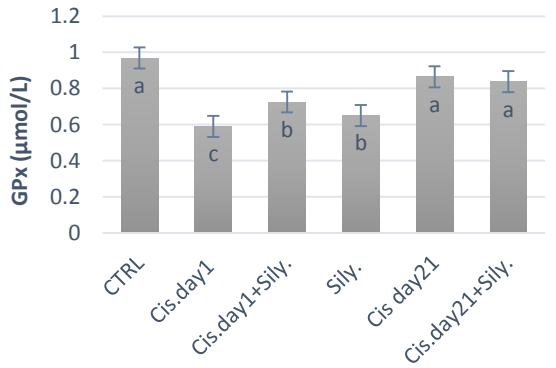

Fig.(5) . Level of GPx affected by cisplatin and silymarin treatments.

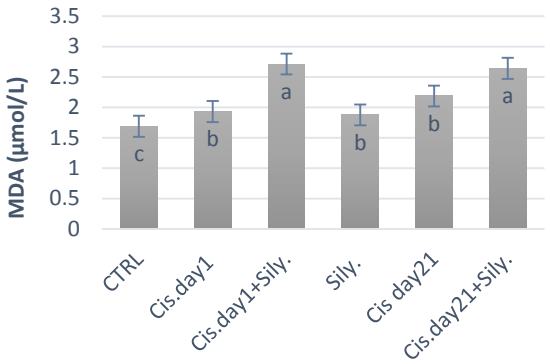

Fig.(6) . Level of MDA during Cisplatin and Silymarin treatments.

Chemotherapeutic agents such as cisplatin is an effective agents and its use limited by its potential for cytotoxicity organs (Ozols *et al*.,2003; Kondagunta *et al*.,2005). Different strategies proposed to mitigate the harmful effects of chemotherapeutic agents on healthy tissues, included Antioxidants compounds and modification of drug delivery system (Ahmed *et al*.,2019, Adejo *et al*.,2016). Cisplatin demonstrated as hepatotoxic agent in histopathological analysis including liver function profile, Oxidative stress and CYP2E1. Cisplatin can induce alter in the structure and function of the cell membrane of liver cell (Hamaya *et al*.,2023). Which makes a significant implications in cellular integrity and function.

Free radicals accumulation in liver cell react with lipids in the cell membrane cause a lipid peroxidation, this process lead to induce damage and alter in membrane structure and function (Very.,2011; d'Ischia *et al*.,2011). Toxicity of cells is associated with imbalance between antioxidant scavenging system and production of reactive oxygen species ROS which reduce of cells to detoxify the free radicals (Yu *et al*.,2018; Sandulache *et al*.,2014). Cisplatin has a high affinity to bind with a thiol group in protein structure like GSH, leads to form a complexes (Florea and Busselberg.,2011). Glutathione is important endogenous antioxidant and consider a key to neutralize ROS and protect the cells from oxidative damage

(Conde *et al*.,2014; Ali & Khalaf and Ali., 2023). Increasing in MDA level (fig. 6) refer to high lipid peroxidation (Gaweł *et al*.,2004). caused by oxidative agents and reduction in defense system (fig.6). The damages in liver cell observed in the experimental groups treated with cisplatin (image 7).

Results observed increasing in antioxidants in groups treated with silymarin and subjected to cisplatin (fig. 3,4,5) which confirm the potential efficacy of silymarin in augmenting antioxidants activity. Silymarin free radical scavenging properties regulating glutathione (Pradhan and Girish.,2006). The regulatory function include stimulation of glutathione transferase activity and promoting the binding of GSH with free radicals to ameliorate their deleterious on cell structure (Vairetti *et al*.,2021).Resistance to cisplatin can develop through diverse molecular and cellular processes. These encompass diminished cisplatin accumulation within cells, achieved through alterations in intracellular drug influx and efflux (Romani.,2022). Additionally, resistance may arise from heightened detoxification mechanisms, such as elevated levels of intracellular thiols mediated by glutathione and metallothionein. Moreover, increased DNA repair activity plays a crucial role in resistance development. Furthermore, resistance may be fortified by the prevention of apoptosis through signaling molecules, among other intricate mechanisms (Forgie.,2022).

However, the observed elevation in the malondialdehyde MDA level in both therapeutic and preventive groups treated with cisplatin and silymarin prompts further scrutiny (Fig.6). This increase is theorized from the formation of complexes within cellular compartments, arising from the intricate interplay between cisplatin and silymarin. The consequential impact on silymarin efficacy is notably confirmed by an augmented level of (ALT) and (AST) enzyme activity in particular at the group exposed to cisplatin at day 21 of the experiment (Fig.1,2) and this is evident tissue damage, as corroborated by histological assessments (Image 9,10). While the therapeutic group and silymarin group showed normal level of liver enzyme function and this is related to the antioxidant properties. This result agreed with (Mohiuddin et al., 2023) who pointed to role of natural compound in protecting liver tissue from damage.

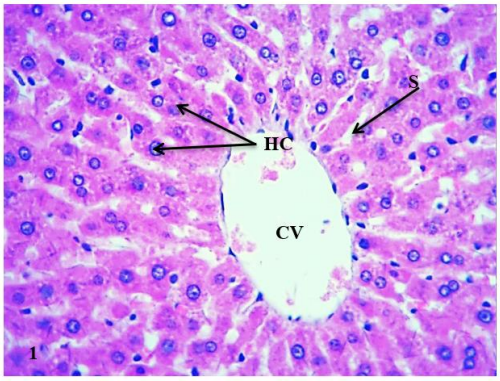

Image (1) of a liver section from the control group illustrating the central vein (CV), hepatocytes (HC), and blood sinusoids (S**).**

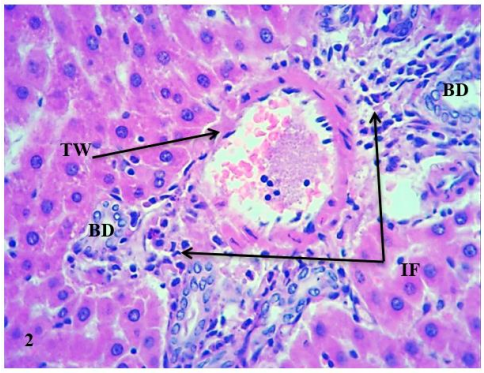

Image (2) of a liver section from the group treated with the cisplatin at day 1 of the experiment, showing thickning of the blood vessel wall (TW) and infiltration of inflammatory cells (IF) around the blood vessel and the bile duct (BD)**.**

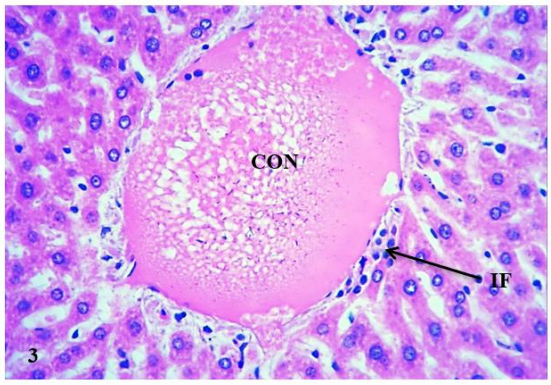

Image (3) section from the group treated with the cisplatin at day 1, illustrating vascular congestion (CON) and infiltration of inflammatory cells (IF)**.**

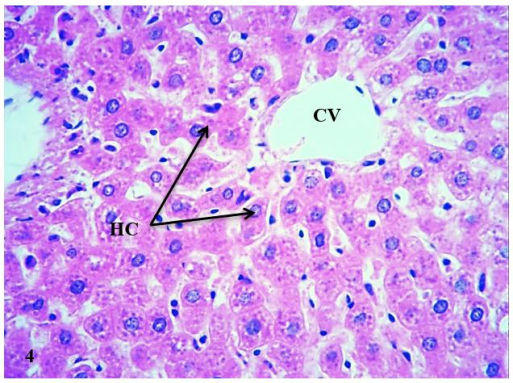

Image (4) of a liver section from the group treated with cisplatin at the beginning of the experiment with silymarin, illustrating a nearly normal appearance of hepatocytes (HC) and the central vein (CV**).**

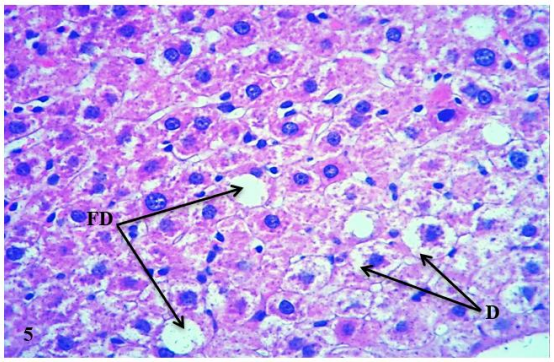

Image (5) of a liver section from the group treated with the drug cisplatin at the beginning of the experiment with silymarin extract, illustrating Degeneration of hypatocyte (D) with the observation of fatty degeneration (FD).

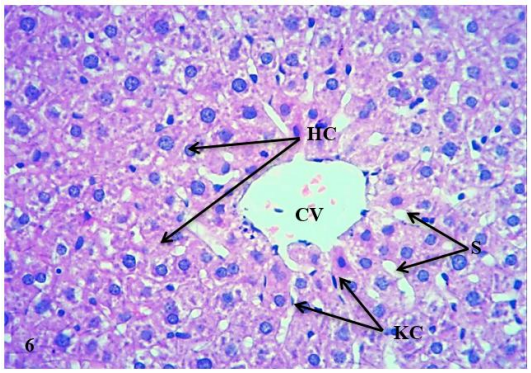

Image (6) of a liver section from the group treated with a silymarin, illustrating the central vein (CV), hepatocytes (HC), blood sinusoids (S**)** and kupffer cell (KC)**.**

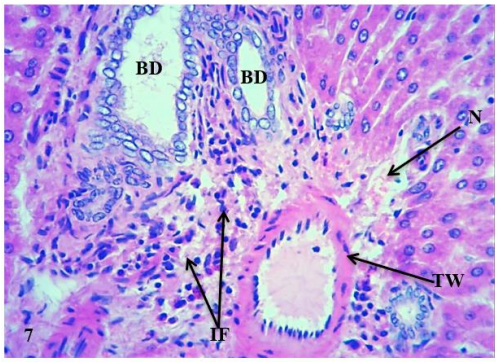

Image (7) of a liver section from the group treated with cisplatin at the end of the experiment, showing thickning of the blood vessel wall (TW) and infiltration of inflammatory cells (IF) around the blood vessel and the bile duct (BD), accompanied by the presence of necrosis (N) within the liver tissue.

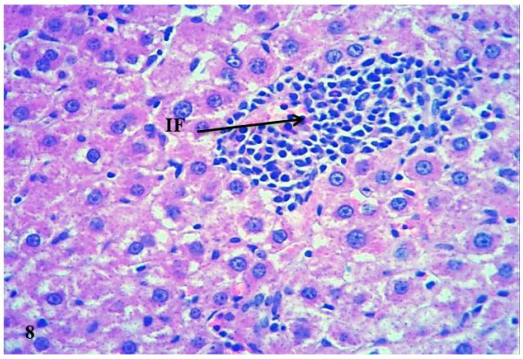

Image (8) of a liver section from the group treated with cisplatin at the end of the experiment, depicting focal infiltration of inflammatory cells (IF).

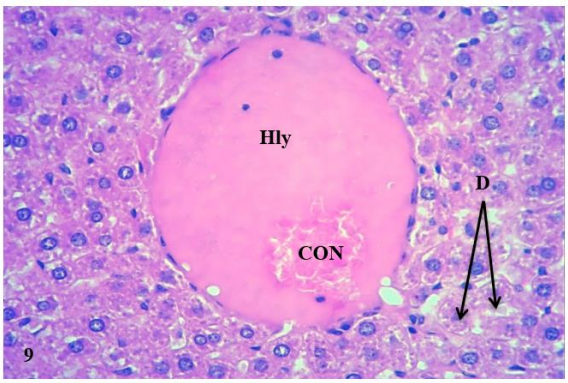

Image (9) of a liver section from the group treated with cisplatin at the end of the experiment with silymarin, showing central vein congestion (CON) with the observation of hemolysis (Hly).

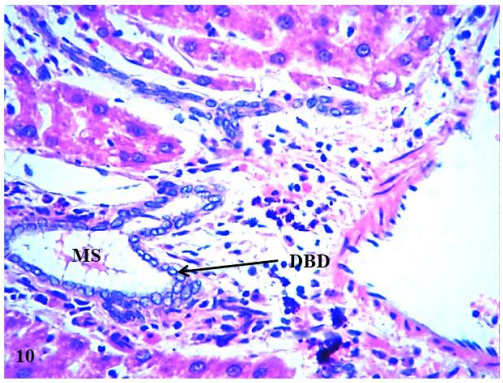

Image (10) from the group treated with cisplatin at the end of the experiment with silymarin, showing bile duct dilation (DBD) with the observation of mucoid substance within the bile duct (MS).

Furthermore, the documented protective role of silymarin in liver tissue is expounded, encompassing the regulation of liver cell membrane permeability, thereby affording protection against the impact of pharmaceutical agents and toxic substances (Image. 4,6). Antioxidants stabilize biological membranes, and increase cell viability (Sonter *et al*.,2021). Silymarin reduces cytosol (NADPH), glutathione depletion and nitric oxide production thereby preventing oxidative stress and liver cell destruction (Khazaei *et al*.,2022). Silymarin also stabilize cell membrane, boosts the activity of SOD and inhibit lipid peroxidation. (El-Kot *et al*.,2023).

CONCLUSION

We concluded the bioactivity of silymarin in attenuate the damage of liver induced by drug toxicity in particular the therapeutic group. Also These findings suggest a nuanced interplay between cisplatin and silymarin, influencing the oxidative stress response and subsequent cellular outcomes. The complexities of drug interactions and their impact on therapeutic efficacy necessitate further investigation to delineate the underlying mechanisms and optimize combinatorial therapeutic strategies for mitigating drug-induced hepatotoxicity and enhancing antioxidant capacity.

ETHICAL APPROVE

Experimental conditions were conducted according to the Helsinki Declaration and the ethical approval was registered at the Ethical Committee of scientific research at University of Tikrit, under number, No.2023.7.

Acknowledgment

The author expresses gratitude to the University of Tikrit in Iraq for granting permission to utilize the scientific laboratories.

Conflict of interest

No conflicts of interest regarding of this manuscript.

REFERENCES

Adejo, G. , Gnimintakpa, J. , Olowoniyi, O. & Matthew, P. (2016) Andrographis peniculata: Capabilities against Free Radicals, Lipid Peroxidation, Hepatotoxicity, and Nephrotoxicity. Open Access Library Journal, 3, 1-9. doi: 10.4236/oalib.1102541.

Ahmed, M. A., Tayawi, H., Ibrahim, M. Protective effect of Silymarin against kidney injury induced by carbon tetrachloride in male rats. Iraqi Journal of Veterinary Sciences, 2019; 33(1): 127-130. doi: 10.33899/ijvs.2019.125529.1051.

Ali, D. S., & Khalaf, D. S. (2023). Chemical composition, radical scavenging, rheological and sensory properties of local Soft cheese (Paneeri Salik) supplemented with some natural anti-oxidant extracts. Tikrit Journal for Agricultural Sciences, 23(4), 43–57. https://doi.org/10.25130/tjas.23.4.5

Al-Obaidi, J.R., Desa S., Adibah A., Azeyanty A., Saidin S. & Nafizah M. (2022). Integration of Medicinal Plants into Comprehensive Supply Chains: The Threats and Opportunities of Environmental Devastation. In: Aftab, T. (eds) Environmental Challenges and Medicinal Plants. Environmental Challenges and Solutions. Springer, Cham. https://doi.org/10.1007/978-3-030-92050-0_21.

Amien, A. I., Fahmy, S. R., Abd-Elgleel, F. M., & Elaskalany, S. M. (2015). Renoprotective effect of Mangifera indica polysaccharides and silymarin against cyclophosphamide toxicity in rats. The Journal of Basic & Applied Zoology, 72, 154–162. doi:10.1016/j.jobaz.2015.09.006.

Bancroft, J. D. & Gamble, M. (2002). Theory and Practice of Histological Techniques. 5th ed. Philadelphia. Churchill-Livingstone, pp.377-694.

Baumber, J. & Ball, B.A. (2005). Determination of glutathione peroxidase and superoxide dismutase-like activities in equine spermatozoa, seminal plasma, and reproductive tissues. Am J Vet Res. 66(8):1415-9. doi: 10.2460/ajvr.2005.66.1415.

Brown, M.S. & Godstein. (1983). Ann Rev.Biochem ,25,223.

Chambers, C.S., Holečková, V., Petrásková, L., Biedermann, D., Valentová, K., Buchta, M. & Křen, V. (2017). The silymarin composition… and why does it matter. Food Res. 339-353. doi: 10.1016/j.foodres.2017.07.017.

Choudhari, A. S., Mandave, P. C., Deshpande, M., Ranjekar, P., & Prakash, O. (2020) Phytochemicals in Cancer Treatment: From Preclinical Studies to Clinical Practice. Frontiers in Pharmacology, 10. doi:10.3389/fphar.01614.

Conde, L., García-Ruiz, C., & Fernández-Checa, J. C. (2014). Glutathione in Mammalian Biology. Systems Biology of Free Radicals and Antioxidants, 617–644. doi:10.1007/978-3-642-30018-9-40.

Dawson, B. & Trapp, R. G. (2001). Basic and Clinical Biostatistics. 3rd ed. New York, Lang Medical Books/McGraw-Hill.

d'Ischia, M., Napolitano, A., Manini, P. & Panzella, L. (2011). Secondary targets of nitrite-derived reactive nitrogen species: nitrosation/nitration pathways, antioxidant defense mechanisms and toxicological implications. Chem Res Toxicol.19;24(12):2071-92. doi: 10.1021/tx2003118.

El-Kot, S.M., Wanas, W., & Hafez, A.M.(2023). Effect of silymarin on the relative gene expressions of some inflammatory cytokines in the liver of CCl_4-intoxicated male rats. *Sci Rep* **13**, 15245. https://doi.org/10.1038/s41598-023-42250-7

Ellman, G.L. (1959).Tissue sulfhydryl groups. *Arch Biochem Biophys.* P: 82:70–77.

Florea, A.M. & Busselberg, D. (2011). Cisplatin as an anti-tumor drug: Cellular mechanisms of activity, drug resistance and induced side effects. Cancers. 2011;3:1351–1371. doi: 10.3390/cancers3011351.

Forgie, B.N., Prakash, R. & Telleria, C.M. (2022) Revisiting the Anti-Cancer Toxicity of Clinically Approved Platinating Derivatives. Int. J. Mol. Sci. 2022;23:15410. doi: 10.3390/ijms232315410.

Gaweł, S., Wardas, M., Niedworok, E. & Wardas, P. (2004). Dialdehyd malonowy (MDA) jako wskaźnik procesów peroksydacji lipidów w organizmie [Malondialdehyde (MDA) as a lipid peroxidation marker]. Wiad Lek. 57(9-10):453-5.

Guder, W.(2012). Die Qualitat diagnostischer Proben. 7th edition.p:20-22.

Senthilkumar, M., Amaresan, N., & Sankaranarayanan, A. (2021). Estimation of Malondialdehyde (MDA) by Thiobarbituric Acid (TBA) Assay. In: Plant-Microbe Interactions. Springer Protocols Handbooks. Humana, New York, NY. https://doi.org/10.1007/978-1-0716-1080-0_25

Gupta, O.P., Sing, S., Bani, S., Sharma, N., Malhotra, S., Gupta, B.D., Banerjee, S.K. & Handa, S.S. (2000). Anti-inflammatory and anti-arthritic activities of silymarin acting through inhibition of 5-lipoxygenase. Phytomedicine.7(1):21-4. doi: 10.1016/S0944-7113(00)80017-3.

Hassan, M. S., Morgan, A. M., Mekawy, M. M., & Zeineb, M. A. (2019). Molecular mechanisms of Cisplatin- induced placental toxicity and teratogenicity in rats and the ameliorating role of N-acetyl-cysteine. The International Journal of Biochemistry & Cell Biology, 105579. doi:10.1016/j.biocel.2019.105579.

Hamaya, S., Oura K., Morishita, A., & Masaki, T. (2023). Cisplatin in Liver Cancer Therapy. Int J Mol Sci. 29;24(13):10858. doi: 10.3390/ijms241310858.

Khazaei, R., Seidavi, A., & Bouyeh, M.(2022). A review on the mechanisms of the effect of silymarin in milk thistle (Silybum marianum) on some laboratory animals. Veterinary Medicine and Science, 8, 289–301. https://doi.org/10.1002/vms3.641

Kondagunta, G.V., Bacik, J., Donadio, A., Bajorin, D., Marion, S., Sheinfeld, J., Bosl, G.J, & Motzer R.J. (2005). Combination of paclitaxel, ifosfamide, and cisplatin is an effective second-line therapy for patients with relapsed testicular germ cell tumors. J Clin Oncol. 20;23(27):6549-55.

Mohiuddin, A. S., Mohammed, M. J., & Jassim, M. A. (2023). Physiological effects of manganese nanoparticles on Alloxan-Induced Diabetes Mellitus in Adult Male

Rats: Physiological effects of manganese nanoparticles on Alloxan-Induced Diabetes Mellitus in Adult Male Rats. Tikrit Journal for Agricultural Sciences, 23(4), 136–146. https://doi.org/10.25130/tjas.23.4.12

Ozols, R.F., Bundy, B.N., Greer, B.E., Fowler, J.M., Clarke-Pearson, D., Burger RA, Mannel RS, DeGeest K, Hartenbach EM & Baergen R. (2003). Gynecologic Oncology Group. Phase III trial of carboplatin and paclitaxel compared with cisplatin and paclitaxel in patients with optimally resected stage III ovarian cancer: a Gynecologic Oncology Group study. J. Clin. Oncol. 01;21(17):3194-200.

Pradhan, S.C., Girish, C. (2006). Hepatoprotective herbal drug, silymarin from experimental pharmacology to clinical medicine. Indian J Med Res.124(5):491-504.

Romani, A.M.P. (2022). Cisplatin in cancer treatment. Biochem. Pharm. 206:115323. doi: 10.1016/j.bcp.2022.115323.

Sandulache, V. C. (2014). Evaluation of hyperpolarized [1-(1)(3)C]-pyruvate by magnetic resonance to detect ionizing radiation effects in real time. 9, e87031, doi.org/10.1371/journal.pone.0087031PONE-D-13-34053.

Sonter, S., Mishra, S., & Dwivedi, M.K. (2021). Chemical profiling, in vitro antioxidant, membrane stabilizing and antimicrobial properties of wild growing *Murraya paniculata* from Amarkantak (M.P.). *Sci Rep* **11**, 9691 (2021). https://doi.org/10.1038/s41598-021-87404-7

Vairetti, M., Di Pasqua, L.G., Cagna, M., Richelmi, P., Ferrigno, A., & Berardo, C. (2021). Changes in Glutathione Content in Liver Diseases: An Update. Antioxidants. 10(3):364. https://doi.org/10.3390/antiox10030364.

Very, S.V. (2011). Molecular targets of oxidative stress. Biochem J. 1;434(2):201-10. doi: 10.1042/BJ20101695.

Viktorová, J., Dobiasová, S., Řehořová, K., Biedermann, D., Káňová, K., Šeborová, K., & Macek, T. (2019). Antioxidant, Anti-Inflammatory, and Multidrug Resistance Modulation Activity of Silychristin Derivatives. Antioxidants,8(8), 303. doi:10.3390/antiox8080303.

Yu, W., Chen, Y., Dubrulle, J., Stossi, F., Putluri, V., Sreekumar, A., & Sandulache, V. C. (2018). Cisplatin generates oxidative stress which is accompanied by rapid shifts in central carbon metabolism. Scientific Reports, 8(1). doi:10.1038/s41598-018-22640-y.

Zaker-Esteghamati, H., Seidavi, A. R., & Bouyeh, M. (2020). A review on the effect of Silybum marianum and its derivatives on broilers under healthy and aflatoxicosis conditions: part 1: Performance, carcass and meat characteristics, and intestinal microflora. World's Poultry Science Journal, 76(2), 318–327.