

Evaluation of the Efficacy of Pumpkin Seed Extract Against Gentamicin-Induced Hepatotoxicity in Laboratory Rats

Maryam Saber Matar and Loay H. Ali

Department of Biology, College of Education for Pure Sciences, University of Anbar,

Corresponding author: mar23u1013@uoanbar.edu.iq

Abstract :

This experiment was designed to demonstrate the therapeutic and preventive efficacy of pumpkin seed extract against gentamicin-induced hepatotoxicity. A total of 40 adult male Sprague-Dawley albino rats were used in the study, which were divided into five groups, each containing 8 rats: Group 1 (Control Group), Group 2 (Gentamicin Group), Group 3 (Pumpkin Group), Group 4 (Therapeutic Group), and Group 5 (Preventive Group). The results showed an increase in liver enzymes AST and ALT, Malondialdehyde as a marker of lipid peroxidation, and tumor necrosis factor-alpha, along with a decrease in the antioxidant glutathione in the gentamicin group. In contrast, the groups treated with the alcoholic extract of pumpkin seeds exhibited improvements in these parameters, returning to normal levels. This indicates that pumpkin seed extract plays a positive role in improving the histological structure of the liver and has a protective and therapeutic role in mitigating the toxic effects of gentamicin on liver cells in laboratory animals.

Keywords: *Hepatotoxicity, Gentamicin, Antioxidants, Liver Enzymes.*

تقييم فعالية مستخلص بذور اليقطين ضد السمية الكبدية الناجمة عن علاج الجرذان المختبرية بالجنتاميسين.

مريم صابر مطر ، لؤي حاتم علي

مستخلص:

صُممت هذه التجربة لإثبات التأثيرات العلاجية والوقائية لمستخلص بذور اليقطين ضد السمية الكبدية الناتجة عن الجنتاميسين. استعملت في الدراسة 40 حيواناً بالغاً من ذكور الجرذان البيض Males Albino Rats نوع Sprague Dawley، تم تقسيم الحيوانات الى خمس مجاميع تضم كل مجموعة 8 جرذان، المجموعة الاولى (مجموعة السيطرة) المجموعة الثانية (مجموعة الجنتاميسين Gentamicin) المجموعة الثالثة (مجموعة اليقطين)، المجموعة الرابعة (العلاجية)، المجموعة الخامسة (الوقائية)، حيث اظهرت النتائج حصول ارتفاع معنوي في انزيمات الكبد AST,ALT ومؤشر بير وكسدة الدهون المالموندالديهايد Malondialdehyde وعامل النخر الورمي نوع الفا Tumor Necrosis Factor Alpha وانخفاض في مضاد الاكسدة Glutathione في مجموعة الجنتاميسين بينما اظهرت النتائج في المجاميع المجرعة بالمستخلص الكحولي لبذور اليقطين حصول تحسن في هذه المعايير وعودتها لمستوياتها الطبيعية اذ لعب مستخلص بذور اليقطين دوراً إيجابياً في تحسين البنية النسيجية للكبد وان له دور وقائي وعلاجي في تثبيط الآثار السامة للجنتاميسين في أنسجة الكبد لدى حيوانات المختبر. الكلمات المفتاحية: سمية كبدية، جنتاميسين، مضادات اكسدة، انزيمات كبد.

Introduction

Gentamicin (GNT) stands out as a pivotal member of the aminoglycoside class, widely utilized in clinical settings to combat life-threatening Gram-negative bacterial infections. However, despite its therapeutic advantages, there is mounting evidence highlighting GNT's hepatotoxicity, which poses a significant concern for its continued clinical application. Research indicates that oxidative stress and inflammation are the primary contributors to liver toxicity associated with GNT treatment (Ali *et al.*, 2020).

Scientists are increasingly recognizing the significance of medicinal plants and the consumption of natural foods in the management and control of various health disorders. Numerous natural compounds exhibit antioxidant properties, functioning effectively as free radical scavengers. In comparison to synthetic antioxidants like butylated hydroxytoluene and butylated hydroxyanisole, natural source compounds demonstrate lower toxicity and reduced side effects (Gulcin *et al.*, 2020). Notably, pumpkin, a member of

the gourd family, is acknowledged as a valuable natural source of proteins, fiber, tocopherols, and phytoosterols, along with essential minerals such as zinc, selenium, magnesium, potassium, and phosphorus.

Due to their rich antioxidant properties, pumpkin seeds present significant potential as both functional food and medicinal applications. The secondary metabolites they contain, including essential fatty acids (omega 3, 6, and 9) unsaturated fatty acids, phytoosterols, carotenoids, and vitamins E and A, are present in high concentrations within these seeds and are instrumental in disease prevention.

The antioxidant properties of pumpkin seeds have demonstrated significant efficacy in lowering blood pressure, enhancing fertility, and mitigating the risk of atherosclerosis, alongside their primary function in fat metabolism within organs such as the liver. The underlying mechanisms for these beneficial effects are attributed to the antioxidant activity of pumpkin seeds and their capacity to neutralize free radicals (Ahmed *et al.*, 2019). Our current study aims to assess the effectiveness

of pumpkin seed extract in countering gentamicin-induced hepatotoxicity in laboratory animals.

Materials and Methods

Animals and Experimental Protocol:

This study utilized male Wistar rats, with weights ranging from 260 to 310 grams and aged between 10 to 12 weeks. The subjects were maintained on a standard diet and had access to water. The experimental protocol received approval from both the animal house of the Department of Biology at the College of Education for Pure Sciences and the Animal Ethics Committee at Al-Anbar University. The rats were randomly assigned to five distinct groups: the first group served as the control group, receiving distilled water (5 ml/kg); the second group was administered pumpkin seed extract (500 mg/kg) (Alazragi *et al.*, 2019); the third group received intraperitoneal injections of gentamicin (80 mg/kg) (Althobaiti *et al.*, 2024); the fourth group was treated with gentamicin (80 mg/kg) for 12 days alongside pumpkin seed (500 mg/kg) extract, thus classified as the

treatment group; and the fifth group was given both pumpkin seed (500 mg/kg) extract and gentamicin (80 mg/kg), designated as the preventive group. The duration of the experiment spanned 12 weeks.

Blood Collection

The research team executed the collection of blood samples from all rats through cardiac puncture utilizing single-use syringes. Following the acquisition of the blood samples in test tubes devoid of anticoagulants, the samples were permitted to clot prior to the initiation of biochemical testing. Serum extraction from the clotted blood samples was efficiently performed within a 10-minute timeframe using a centrifuge set at 3,000 RPM. The biochemical markers were subsequently analyzed using the serum, which had been preserved at a frozen temperature of -20 degrees Celsius.

Biochemical Analysis

Measurement of ALT and AST Enzyme Levels: Serum levels of ALT and AST enzymes were quantified utilizing commercially available test kits from the Spanish firm Linear, adhering to the methodology established by Reit-

man and Frankel (1957).

Measurement of Lipid Peroxide in Serum (MDA): MDA levels were assessed as a biomarker for lipid peroxides through the Thiobarbituric Acid (TBA) assay, as described by Ohkawa *et al.* (1979). Spectrophotometric analysis was performed at a wavelength of 532 nanometers to accurately measure absorbance.

Measurement of Glutathione (GSH) Enzyme in Serum: The evaluation of GSH activities in serum was conducted in accordance with the methodology established by Drug (2002).

Assessment of Pro-inflammatory Cytokines Tumor Necrosis Factor Alpha (TNF- α): Serum samples obtained from rats were utilized to measure the levels of pro-inflammatory cytokines, specifically Tumor Necrosis Factor Alpha (TNF- α). This assessment was performed using specialized ELISA kits (BTLAB, China), which included pre-coated microplates with specific antibodies. All reagents, samples, and calibration standards were meticulously prepared following the standard operating procedures outlined by the manufacturers.

	Test kit name	The company	Origin
1	Enzyme estimation kit Alanine Aminotransaminase (ALT)	Linear	Spain
2	Enzyme estimation kit Aspartate Aminotransferase (AST)	Linear	Spain
3	Glutathione (GSH)	BT LAB	China
4	Malondialdehyde Assay Kit (MDA)	BT LAB	China
5	Tumor necrosis factor TNF-a	BT LAB	China

Pathological Tissue Examinations

Liver tissue samples from the rats were preserved in a 10% formalin solution. Following preservation, the samples underwent a series of fluid concentration steps, were subsequently cleaned with xylene and paraffin, and

were then sectioned to a thickness of 5 μ m. The researchers meticulously prepared the tissue samples by cutting them to 5 μ m and staining them with hematoxylin prior to microscopic examination (Bancroft *et al.*, 2013).

Statistical Analysis

Data were presented as mean \pm standard error of the mean (SEM) utilizing the Statistical Package for the Social Sciences (SPSS, version 20). A one-way analysis of variance (ANOVA) was conducted, complemented by Tukey's test for further analysis. A statistical significance threshold of $P \leq 0.05$ was established to identify differences between groups.

Results

The data presented figure 1 and 2 demonstrate a notable elevation in

liver enzyme levels among animals administered gentamicin. Specifically, the concentration of AST reached (54.05 ± 3.912) IU/L, while ALT levels were recorded at (3.098 ± 61.14) IU/L. Conversely, a reduction in these enzyme concentrations was noted in the fourth and fifth treatment groups. The fourth group exhibited AST levels of (2.982 ± 33.52) IU/L and ALT levels of (50.82 ± 2.558) IU/L, whereas the fifth group showed AST at (3.066 ± 29.42) IU/L and ALT at (36.47 ± 3.571) IU/L, both in comparison to the gentamicin group.

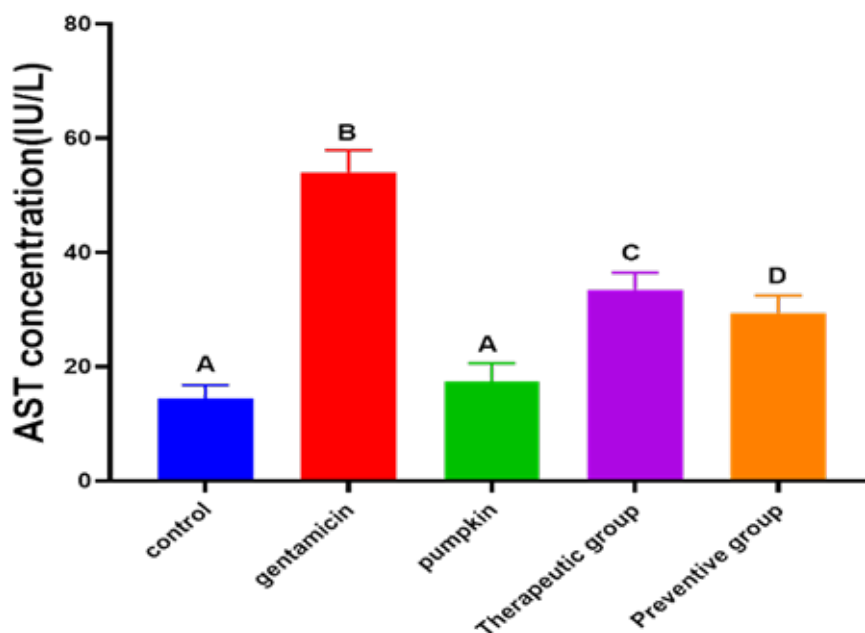


Figure (1) Effect of pumpkin seeds (500 mg/kg) extract on the concentration of AST enzyme in the blood serum of male albino rats treated with gentamicin (80 mg/kg).

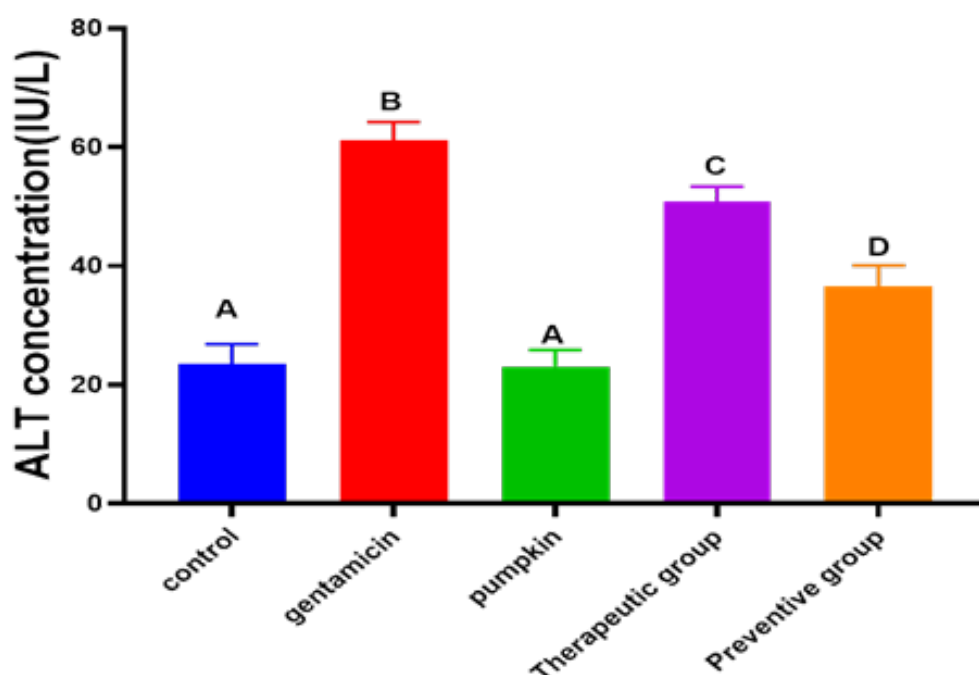


Figure (2) Effect of pumpkin seeds(500 mg/kg) extract on the concentration of ALT enzyme in the blood serum of male albino rats treated with Gentamicin(80 mg/kg).

- The number of experimental animals was 8.
- Different letters indicate a significant difference at a significance level of ($P \leq 0.05$) between groups.
- Same letters indicate no significant difference at a significance level of ($P \leq 0.05$) between groups.

Furthermore, a significant decline in GSH levels was observed, measuring ($\pm 2.857 \pm 23.21$) mg/L, alongside a marked increase in MDA levels, which were recorded at (11.96 ± 0.925) nmol/ml relative to the control group.

In the fourth and fifth groups, the administration of pumpkin seed ex-

tract alongside gentamicin resulted in the normalization of lipid peroxidation levels (MDA) and glutathione (GSH) when compared to the gentamicin-only treatment group (figure 3 and 4).

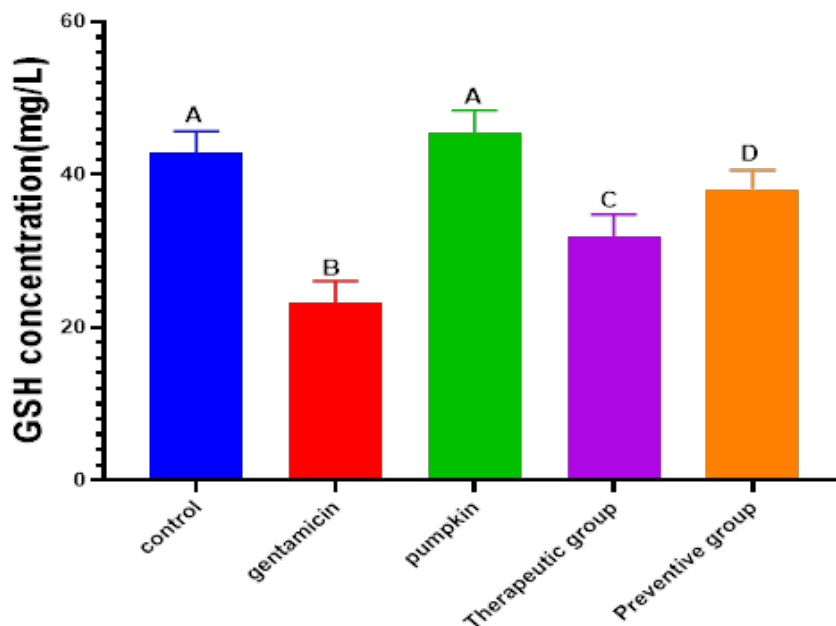


Figure (3) The effect of pumpkin seeds(500 mg/kg) on the concentration of glutathione (GSH) in the blood serum of male albino rats treated with gentamicin(80 mg/kg).

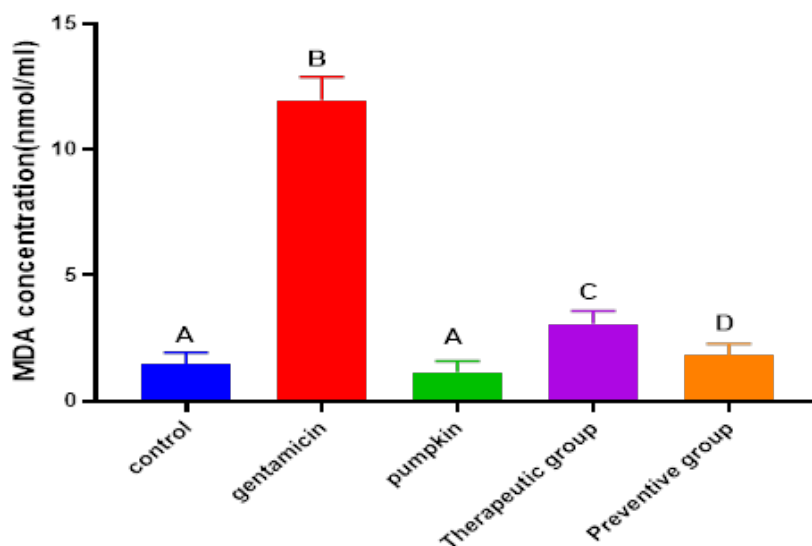


Figure (4) Effect of pumpkin seeds (500 mg/kg)extract on the concentration of Malondi-aldehyde (MDA) in the blood serum of male albino rats treated with gentamicin(80 mg/kg).

- The number of experimental animals was 8.
- Different letters indicate a significant difference at a significance level of ($P \leq 0.05$) between groups.
- Same letters indicate no significant difference at a significance level of ($P \leq 0.05$) between groups.

Figure 5 showed noteworthy increase in TNF- α levels, recorded at (2.018 ± 31.07) ng/ml. Conversely, both the preventive and therapeutic

groups demonstrated a statistically significant reduction in TNF- α levels, achieving a probability level of $(P \leq 0.05)$.

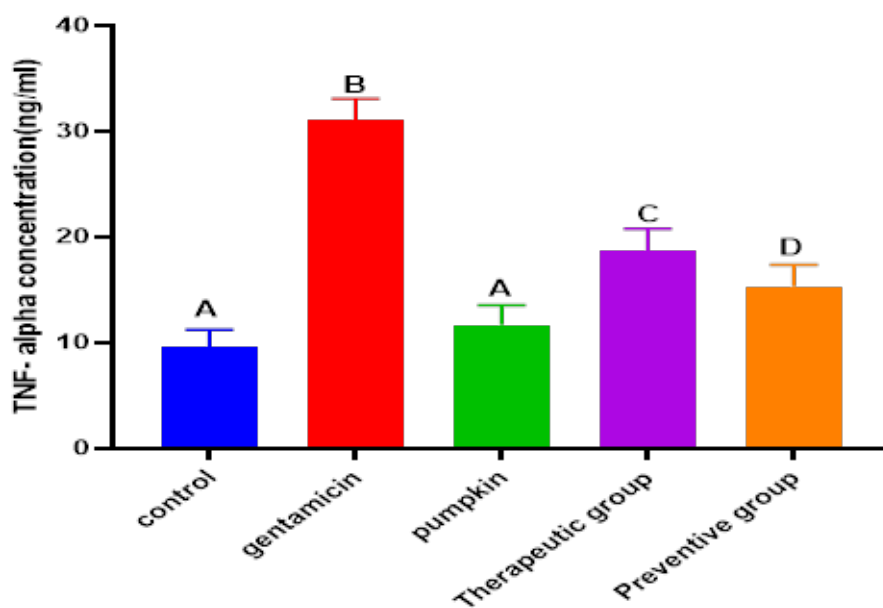


Figure (5) Effect of pumpkin seeds (500 mg/kg) extract on TNF- α concentration in the blood serum of male albino rats treated with gentamicin(80 mg/kg).

- The number of experimental animals was 8.
- Different letters indicate a significant difference at a significance level of $(P \leq 0.05)$ between groups.
- Same letters indicate no significant difference at a significance level of $(P \leq 0.05)$ between groups.

Histological Changes in the Liver

Normal liver tissue was observed in the histological Figure (6), which showed hepatocytes arranged radially around the central vein (CV), a branch of the hepatic portal vein. The normal geometric structure of hepatocytes (HC) was observed, as they appeared in a hexagonal radial arrangement

around the central vein and contained clear centrally located nuclei with the presence of blood sinuses (S) between the hepatocytes, in which Kupffer cells (KC) were present. As for the group treated with the alcoholic extract of pumpkin seeds, it did not show any histological changes compared to the control group, Figure(7).

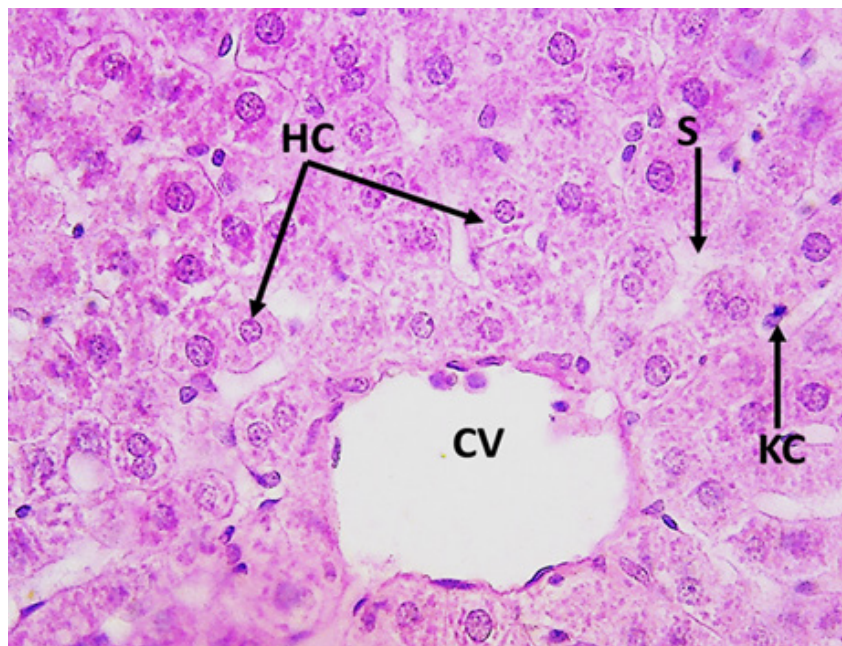


Figure (6) A cross-section of a Normal liver tissue,, highlighting the central vein (C.V.) encircled by strips of hepatocytes (HC) and sinusoids (S). Notably, Kupffer cells (KC) are observed within the sinusoids, stained using hematoxylin and eosin, with a magnification power of 400X.

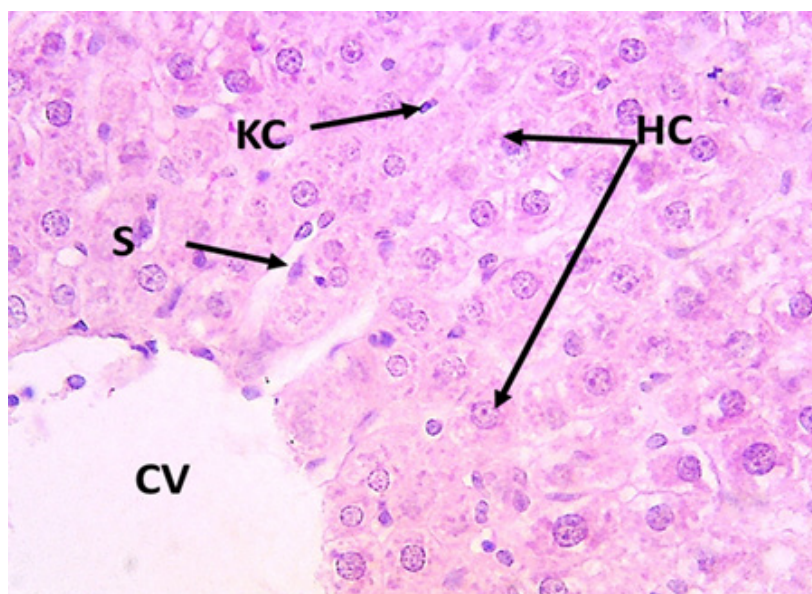


Figure (7) A cross-section of the liver from the group treated with pumpkin seed extract. Notably, the central vein (C.V.) is prominently featured, surrounded by organized strips of hepatocytes (H.C.) and sinusoids (S). Within these structures, Kupffer cells (K.C.) are observed. This analysis utilizes hematoxylin and eosin staining, with a magnification power of 400X.

While the results of microscopic examination of the rat liver treated with gentamicin showed the occurrence of clear and strong histological changes represented by the occurrence of severe congestion (CON) in the central vein with the occurrence of necrosis (N) in the hepatic cells as well as hy-

aline degeneration (D) in some cells, expansion of the hepatic sinusoids with infiltration of inflammatory cells (IL), deposition of cellular debris, and the appearance of vacuolated hepatic cells (V) and the occurrence of hemorrhage (H) in the hepatic tissue, as shown in Figure 8 and 9.

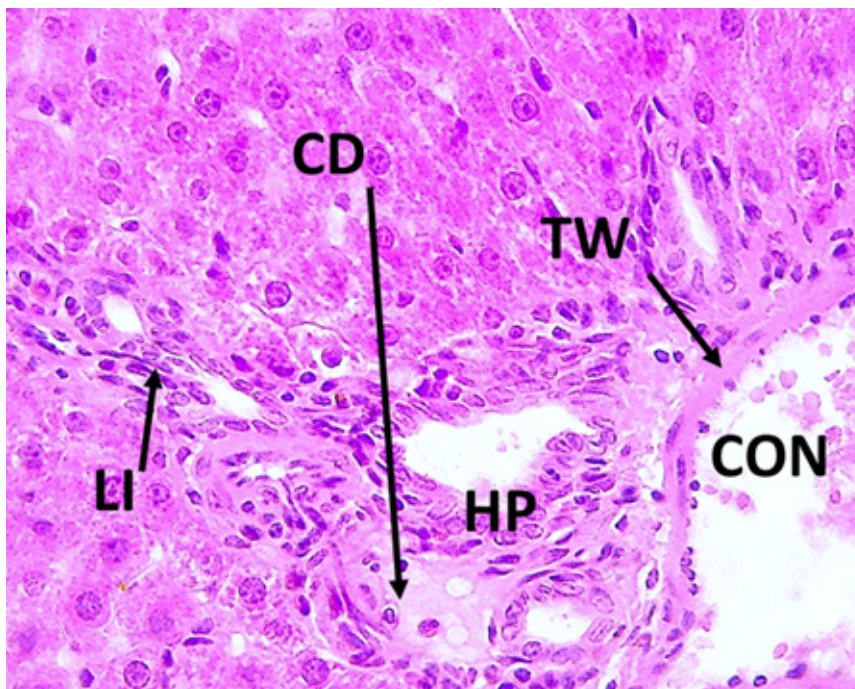
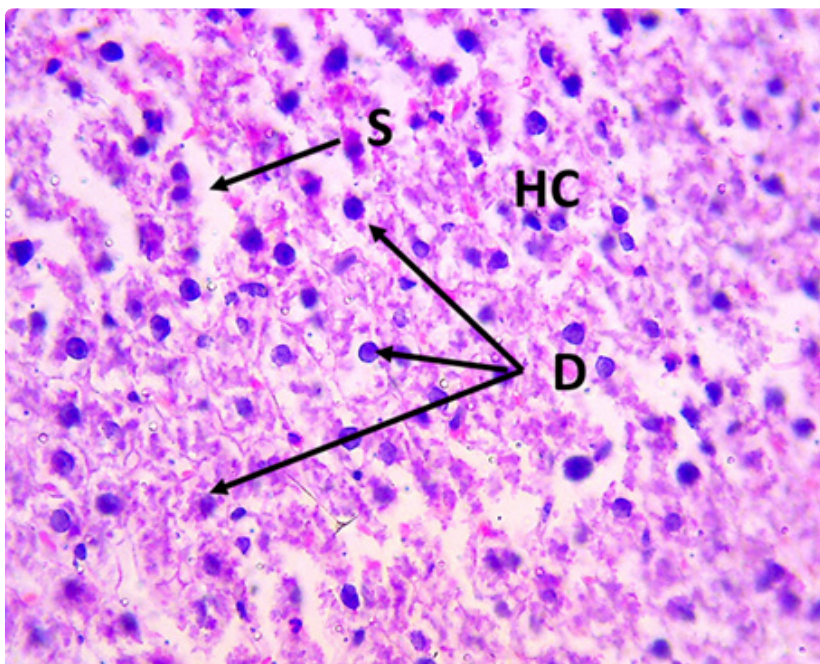


Figure (8) A cross-section of the liver from the group treated with gentamicin. The findings indicate notable blood congestion (CON) within the central vein, vascular wall thickening (TW), hyperplasia (HP), accumulation of cellular debris (CD), and evidence of inflammatory infiltration (LI). This analysis was conducted using hematoxylin and eosin staining at a magnification of 400X.

Figure (9)

A cross-section of the liver of the gentamicin group showing irregular hepatocytes HC with severe degeneration D of the cells, with dilated blood sinusoids S (hematoxylin and eosin stain. Magnification power 400X).

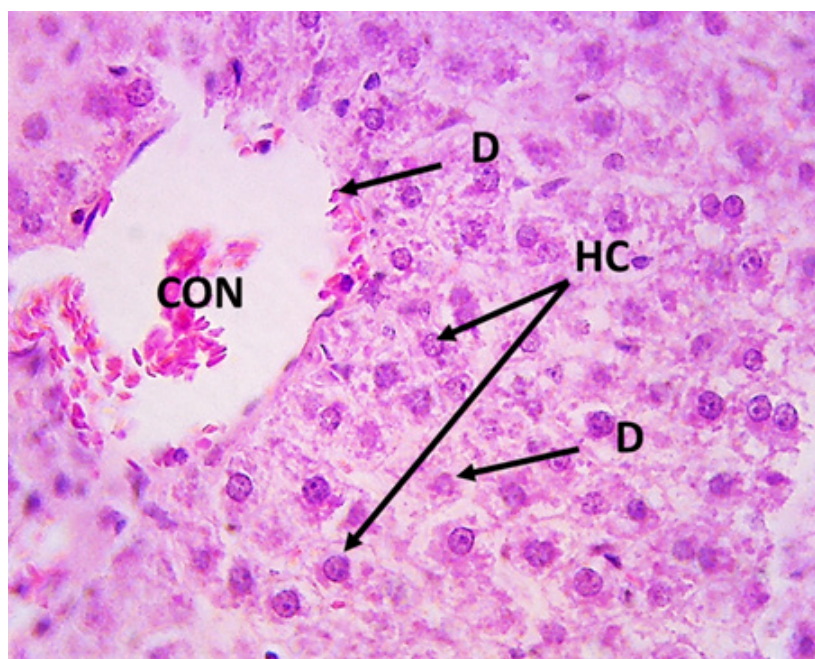


When treated with the alcoholic extract of pumpkin seeds and then with gentamicin (the preventive group), the normal geometric structure of the liver was observed in some tissue sections, as the hepatocytes appeared arranged

radially around the central vein with a slight expansion in the liver sinusoids. Cytoplasmic vacuolization (V) was also observed for a number of cells, as shown in Figure (10).

Figure (10)

A cross-section of the liver of the preventive group, pumpkin seed extract + gentamicin, showing the regularity of the hepatocytes HC in the form of cords around the central vein CV, degeneration of some D cells, and slight congestion CON (hematoxylin and eosin stain. Magnification power 400 (X).



When treated with gentamicin and then with the alcoholic extract of pumpkin seeds (therapeutic group), we observed slight necrosis of some hepatocytes (N) with slight hemorrhage and the presence of the normal radial arrangement around the central vein and a slight expansion in the sinusoids, in addition to the presence of scattered

inflammatory cells in the liver tissue. While in other sections, the return of the normal tissue arrangement was shown and the presence of degeneration (D) for a small number of hepatocytes, with the presence of slight congestion and an increase in mitosis for some hepatocytes, as shown in Figure (11).

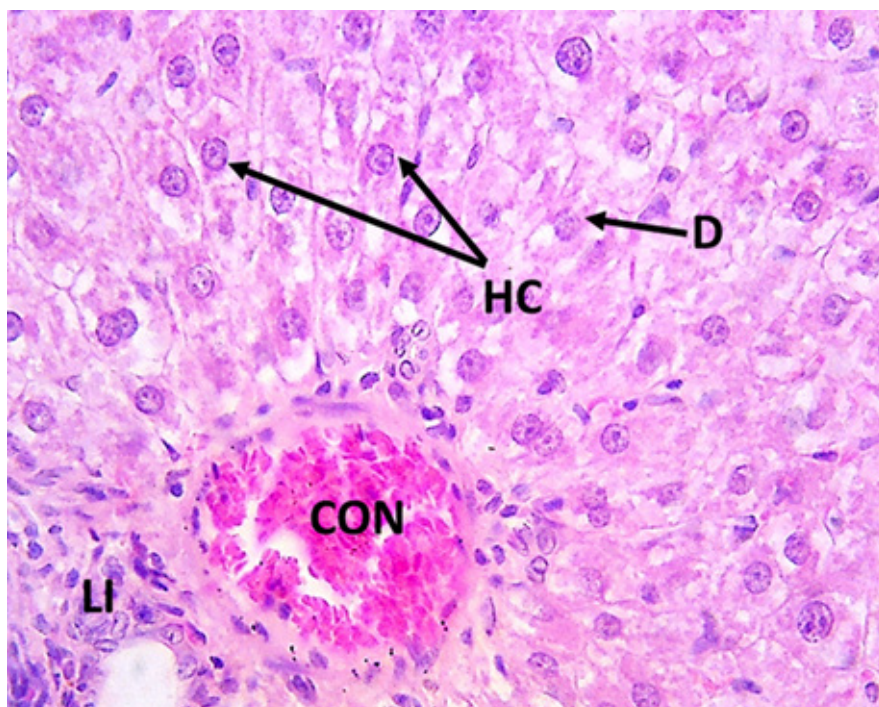


Figure (11) A cross-section of the liver of the gentamicin + pumpkin seed extract treatment group, showing the organization of hepatocytes (HC) in the form of cords around the central vein (CV), degeneration of some D cells, severe congestion (CON), and inflammatory infiltration (LI) (hematoxylin and eosin stain. Magnification power 400X).

Discussion

Certain medications are known to induce oxidative stress through the generation of reactive radicals, which compromise antioxidant defenses and engage directly with biomolecules. Additionally, some of these medications have been associated with hepatic toxicity (Ramachandran *et al.*, 2021). Research indicates that these drugs may disrupt critical signaling pathways and enhance cell permeability by altering membrane phospholipids. In a study involving rats, administration of gentamicin at a daily dosage of 80 mg/kg over a 12-day period resulted in hepatic toxicity, evidenced by damage to liver cells due to cell membrane breakdown, which subsequently led to the release of vital liver enzymes into the bloodstream. The findings revealed a notable increase in serum levels of AST and ALT. The markers identified are indicative of liver injury (Rusyn *et al.*, 2021). Administration of gentamicin has been shown to elevate the production of free radicals within the mitochondria, which subsequently compromise the integrity of liver cell

membranes, resulting in cellular damage and necrosis. This process facilitates the release of specific enzymes into the bloodstream, causing their levels to rise above the normal physiological range (Talaat *et al.*, 2025). The heightened oxidative stress, stemming from the accumulation of free radicals that target both cell and mitochondrial membranes, leads to the formation of lipid peroxides within these membranes, further exacerbating liver cell degradation. Consequently, this impairs venous flow in the hepatic vein or inferior vena cava, which can result in the exacerbation of sinus inflammation and the development of inflammatory regions (Engwa *et al.*, 2022). The findings of this study are consistent with previous research involving a rat model of gentamicin-induced hepatotoxicity over a 7-day period. This earlier study demonstrated a significant increase in serum levels of AST and ALT, alongside indicators of membrane lipid peroxidation, mitochondrial dysfunction, and damage. Additionally, it highlighted an escalation in oxidative and nitrosative stress, ultimately leading to the destruction of liver cells via pro-

grammed cell death or necrosis (Bulboaca *et al.*, 2022).

The fourth therapeutic group and the fifth preventive group that received the alcoholic extract of pumpkin seeds demonstrated significant reductions in AST and ALT levels. These findings align with the research conducted by Al Malki *et al.* (2025). Furthermore, the results revealed a decrease in glutathione levels, a crucial endogenous antioxidant that plays a vital role in neutralizing oxidants, including pharmaceuticals and carcinogenic agents. A reduction in glutathione levels within the body can result in heightened vulnerability of tissues to oxidative stress, as noted by Jiang *et al.* (2023).

The administration of gentamicin has been shown to induce oxidative stress, which subsequently decreases antioxidant activity while increasing levels of hydrogen peroxide and superoxide anions within biological systems. This process facilitates the formation of free hydroxyl radicals, thereby promoting lipid peroxidation and the accumulation of Malondialdehyde (MDA) across various bodily fluids and tissues. These findings align with

the research conducted by Talaat *et al.* (2025). Notably, the heightened MDA levels observed in gentamicin-treated subjects contribute to the depletion of antioxidant defense mechanisms, resulting in tissue damage and further exacerbating lipid peroxidation, which poses significant risks to cellular membrane integrity (Lee *et al.*, 2024).

The observed elevation of tumor necrosis factor (TNF- α) in the second group administered gentamicin suggests that this antibiotic has effectively stimulated the immune response. This interaction may facilitate the secretion of interleukins from inflammatory and immune cells, alongside the activation of nuclear factor kappa B (NF- κ B) and the subsequent release of pro-inflammatory cytokines. These interleukins are crucial in modulating cellular inflammation, enhancing cellular stimulation, and orchestrating the immune response (Karimi *et al.*, 2020).

The observed increase in levels may suggest the presence of inflammation within the body as a result of toxicity. Notable tissue alterations were identified in the cohort of animals administered gentamicin, characterized by

hepatocyte hypertrophy and the emergence of cells in advanced stages of programmed cell death, alongside the detachment of certain endothelial cells. Additionally, there was a significant inflammatory infiltration of white blood cells surrounding the central vein, as well as cytoplasmic vacuolation in several hepatocytes. These findings align with a study indicating that an intraperitoneal injection of 100 mg/kg resulted in hepatic toxicity and elevated serum interleukin levels (Abo-Elmaaty *et al.*, 2023).

An enhancement was noted in the fourth and fifth groups administered pumpkin seed extract. The findings suggest that pumpkin seeds may serve as a significant dietary component that could aid in the prevention of inflammation associated with conditions stemming from excessive oxidative stress, including liver toxicity. This beneficial effect is attributed to the presence of unsaturated fatty acids, such as oleic and linoleic acids, along with essential minerals, polyphenols, tocopherols, carotenoids, and squalene found in pumpkin seeds.

The findings indicate a confirmed

association with overall health benefits, particularly in enhancing antioxidant levels and mitigating oxidative stress (Hussain *et al.*, 2022). Histological analysis revealed that the majority of tissue cells exhibited normal morphology, characterized by large spherical nuclei. Notably, slight hyperplasia was observed in the covering cells of the blood sinusoids, alongside mild congestion in the central vein, which was surrounded by multiple cells. The significant improvement in liver tissue is attributed to the therapeutic effects of pumpkin seed extract, owing to its rich content of active compounds with antioxidant properties.

The findings presented are in alignment with a recent study that substantiates the presence of phenolic compounds, flavonoids, and potent antioxidants in pumpkin seeds. Notably, the administration of pumpkin seed oil in conjunction with sodium nitrate resulted in a significant reduction of liver damage, while effectively maintaining blood parameters, biochemical markers, and oxidative stress levels within physiological ranges in rat models (Rouag *et al.*, 2020). Further-

more, these outcomes are corroborated by an additional study indicating that pumpkin seed oil positively influences specific biochemical and histopathological alterations induced by carbon tetrachloride (Atasever *et al.*, 2020).

Conclusion

This study underscores the therapeutic and preventive properties of pumpkin seeds in mitigating liver toxicity induced by gentamicin, showcasing their potential as effective antioxidant and anti-inflammatory agents. The findings add to the expanding body of evidence regarding the health benefits of pumpkin seeds in the management of liver disorders linked to oxidative stress and inflammation. Continued investigation into the clinical applications of pumpkin seeds may facilitate their integration into therapeutic strategies aimed at addressing chemical toxicity and associated health conditions.

References

- Abo-Elmaaty, A. M., Al-Shahat, D. S., Mohamed, S. A., & Kamel, M. A.** (2023). Prevention of Hepato-renal Toxicity with *Moringa oleifera* in Gentamicin-treated Rats. *Journal of Advanced Veterinary Research*, 13(7), 1338-1346.
- Ahmed, H. S., Elkomy, A. A., & Farag, E. A.** (2019). Evaluating the protective impact of pumpkin seeds oil against ciprofloxacin induced hepatore-renal toxicity in the male albino rats. *Int J Pharmacol Toxicol*, 7, 1-9.
- Al Malki, A., Elnaggar, M., & Zari, T.** (2025). Protective Effect of Pumpkin Seed Oil Extract Against Hepatore-renal Toxicity of Thioacetamide in Male Rats. *Egyptian Academic Journal of Biological Sciences, B. Zoology*, 17(1), 45-54.
- Alazragi, R.** (2019). Protective effect of pumpkin seed oil against hepatotoxicity and nephrotoxicity in rats administered high doses of aspartame. *Med. Sci*, 23, 799-809.
- Ali, F. E., Hassanein, E. H., Bakr, A. G., El-Shoura, E. A., El-Gamal, D. A., Mahmoud, A. R., & Abd-El-**

- hamid, T. H.** (2020). Ursodeoxycholic acid abrogates gentamicin-induced hepatotoxicity in rats: Role of NF- κ B-p65/TNF- α , Bax/Bcl-x1/Caspase-3, and eNOS/iNOS pathways. *Life sciences*, 254, 117760.
- Al-Saeed, O. A., Althwab, S. A., Ahmed, W. E., Al Zunaidy, N. A., Alshalaly, S. S., Almujaaydil, M. S., ... & Mousa, H. M.** (2024). Metabolic Effects of Ajwa Date Extract against Gentamicin-Induced Hepatotoxicity and Nephrotoxicity in Male Rats. *International Journal of Chemical and Biochemical Sciences (IJCBS)*, 26(20), 296-302.
- Althobaiti, S. A., Qahl, S. H., Toufig, H., Almalki, D. A., Nasir, O., & Soliman, M. M.** (2024). Protective impacts of *Artemisia annua* against hepatic toxicity induced by gentamicin. *Toxicology Research*, 13(1), tfad121.
- Atasever, A., Senturk, M., Ekebas, G., Gram, D. Y., & Eren, M.** (2020). The effects of pumpkin seed oil on carbon tetrachloride induced chronic hepatic damage in rats. *The Thai Journal of Veterinary Medicine*, 50(3), 345-351.
- Bancroft, J. D.** (2013). Histochemical techniques: Butterworth-Heinemann.
- Bulboacă, A. E., Porfire, A. S., Rus, V., Nicula, C. A., Bulboacă, C. A., & Bolboacă, S. D.** (2022). Protective effect of liposomal epigallocatechin-gallate in experimental gentamicin-induced hepatotoxicity. *Antioxidants*, 11(2), 412.
- Dröge, W. J. P. r.** (2002). Free radicals in the physiological control of cell function.
- Engwa, G. A., Nweke, F. N., & Nkeh-Chungag, B. N.** (2022). Free radicals, oxidative stress-related diseases and antioxidant supplementation. *Alternative Therapies in Health & Medicine*, 28(1).
- Gulcin, İ.** (2020). Antioxidants and antioxidant methods: An updated overview. *Archives of toxicology*, 94(3), 651-715.
- Hussain, A., Kausar, T., Sehar, S., Sarwar, A., Ashraf, A. H., Jamil, M. A., ... & Majeed, M. A.** (2022). A Comprehensive review of functional ingredients, especially bioactive compounds present in pumpkin peel, flesh and seeds, and their health benefits. *Food Chemistry Advances*, 1,

100067.

Jiang, H., Zuo, J., Li, B., Chen, R., Luo, K., Xiang, X., ... & Gao, F. (2023). Drug-induced oxidative stress in cancer treatments: Angel or devil?. *Redox biology*, 63, 102754.

Karimi, Z., Pakfetrat, Z., Roozbeh, J., & Janfeshan, S. (2020). Toll-like receptor-2 mediates systemic inflammation in gentamicin-induced rat nephrotoxicity. *Clinical and Experimental Pharmacology and Physiology*, 47(9), 1584-1590.

Lee, O. Y. A., Wong, A. N. N., Ho, C. Y., Tse, K. W., Chan, A. Z., Leung, G. P. H., ... & Yeung, M. H. Y. (2024). Potentials of natural antioxidants in reducing inflammation and oxidative stress in chronic kidney disease. *Antioxidants*, 13(6), 751.

Ohkawa, H., Ohishi, N. and Yagi, K. J. A. b. (1979). Assay for lipid peroxides in animal tissues by thiobarbituric acid reaction, 95, 351-358.

Ramachandran, A., & Jaeschke, H. (2021). Oxidant stress and acetaminophen hepatotoxicity: mechanism-based drug development. *Antioxidants & redox signaling*, 35(9), 718-733.

Rouag, M., Berrouague, S., Djaber, N., Khaldi, T., Boumendjel, M., Taibi, F., ... & Messarah, M. (2020). Pumpkin seed oil alleviates oxidative stress and liver damage induced by sodium nitrate in adult rats: biochemical and histological approach. *African Health Sciences*, 20(1), 413-425.

Reitman S, Frankel S. A colorimetric method for the determination of serum glutamic oxalacetic and glutamic pyruvic transaminases.

Am J Clin Pathol 1957;28:56-63.

Rusyn, I., Arzuaga, X., Cattley, R. C., Corton, J. C., Ferguson, S. S., Godoy, P., ... & Smith, M. T. (2021). Key characteristics of human hepatotoxicants as a basis for identification and characterization of the causes of liver toxicity. *Hepatology*, 74(6), 3486-3496.

Talaat, A., Badr, N. S., Ghoneim, A. Z., & El-Saidy, S. A. (2025). Antioxidant efficiency of Sarcophyton crude extract against gentamicin toxicity in male albino rats. *Scientific Reports*, 15(1), 7468.