

The toxicity of alcohol and the role of vitamin C with this toxicity

E. H.Al-Taae
Coll.of Vet.Med./Unive.of Baghdad

R.N.Al-Saadi S. S.Al- Rubbeei
Institute of technical medicine/ Baghdad

Abstract

In order to study or evaluate the toxic effect of alcohol in mice and the role of vitamin C as a protective factor in this toxicity, a group of mice was given alcohol alone .Another second group was given alcohol with vitamin C for 90 days, and the third group represent the control group.Histopathological changes were showed hydropic degeneration and vacuolation with enlargement of the hepatocyte and then progress to fatty change.in addition there is necrotizing changes which being widely shown with the time of treatment,over a wide area at 90 days.These changes accompanied with inflammation which started after 2 weeks of experiment which characterized by a slight infiltration and then progress of lymphoid follicles in the parenchyma of the liver and cuffing of congested blood vessels. Also there is infiltration of fibroblast with increase activity of hepatocyte division.The second group of alcohol with vitamin C showed less severity changes than the first group which treated with alcohol only.

Introduction

People who drink large quantities of alcohol over along period of time are generally at greatest risk of developing alcohol liver disease (1, 2). Alcohol is metabolized in a multi_step process in to various metabolites which have unique biochemical effects of their own .The first step in this process is the conversion of alcohol to acetaldehyde. Since acetaldehyde is approximately 30 times more toxic than alcohol, acetaldehyde is a major cause of alcohol associated side effects (3).The liver break down alcohol to eliminated it from the body, If consume more alcohol than the liver can process, the resulting imbalance can injure the liver by interfering with its normal breakdown of protein, fats, and carbohydrates. There are

three kinds of liver disease related to alcohol consumption: fatty liver, Alcoholic hepatitis, and alcoholic cirrhosis (4, 5, and 6).the world Health Organization (WHO) estimates that alcohol cause 1.8million deaths world wide each year. Alcohol was estimated to cause liver disease, mouth, pharynx, larynx, and esophageal cancer (7, 8).Vitamin C can inhibit the toxic effect of alcohol by enhancing the antioxidant capacity, while the large intake of alcohol can depress the concentration of ascorbic acid in the plasma and increase urinary excretion of vitamin C (3).This work was aimed to follow the pathological changes which are produced from the toxicity of alcohol and the role of vitamin C against this toxicity in the liver of mice.

Material and Method

Thirty six mice were used in this experiment, animals separated in to (3) groups, each group (12) animals. first group was given alcohol (ethanol) in concentration 30% via water .the second group was given alcohol in concentration 30% with vitamin c in concentration 60mg/kg b.w., and third group represented the control. The experimental period lasting for 12 weeks. (2) Animals were

killed every (2) weeks of this period.Tissue specimens from the liver were sent for histological examination using 10% neutral buffered formalin as fixation.Tissue specimens were processed for histology and paraffin blocks were cut at 4-6um.thickness. Tissue section stained with routine hariss haematoxyllin and eosin stain.

Results

Gross pathology: sequential killing of the first group of mice revealed obvious changes in the liver at the 2nd weeks of the experiment; the liver was congested and enlarged, at the last week of the experiment the liver appeared yellowish, greasy form. The second group of the experiment showed congestion and enlarged liver at the 6th weeks of the experiment.

Histopathology: first group

Microscopic pathological alteration seen in the 2nd weeks of the experiment. The liver showed enlargement of the hepatocyte and dilatation of the sinusoid, with congested central vein with slight infiltration of the lymphoid cells in the parenchyma figure(1). At the 4th weeks the liver suffered from degeneration of the hepatic cell (hydropic degeneration), with congestion of the central vein Figure (2). There is wide infiltration of inflammatory cells with necrosis of the hepatic cells detected at the 6th weeks. The microscopic picture at the

8th weeks showed loss of the cell structure leading to fatty change with congestion in the central vein Figure (3). At the 10 weeks there is cuffing of the congested blood vessels, with infiltration of the fibroblast with increase of the hepatocyte activity for division. The last two weeks shown wide area of fatty change with focal necrosis Figure (4).

Second group:(alcohol 30%+vitamin c 60mg/gm/b.w.)

There is no pathological changes seen at the 2nd weeks of the experiment. There is a slight histopathological change at the 4th weeks characterized by dilatation of the sinusoids, hepatic cell enlargement with central vein congestion Figure (5). The 6th and 8th week's there's a slight infiltration of lymphoid cells in the liver parenchyma. The hepatic cells suffer from hydropic degeneration with small areas of fatty change at the 10th and 12 weeks of the experimental period Figure (6).

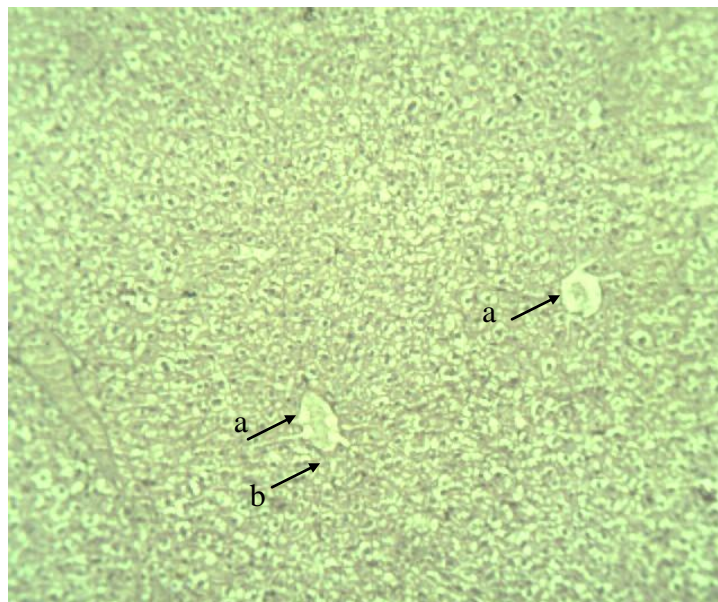


Fig. (1) alcohol group at 2nd weeks of the experiment section of the liver showed congested central vein(a) with dilatation of the sinusoids (b)

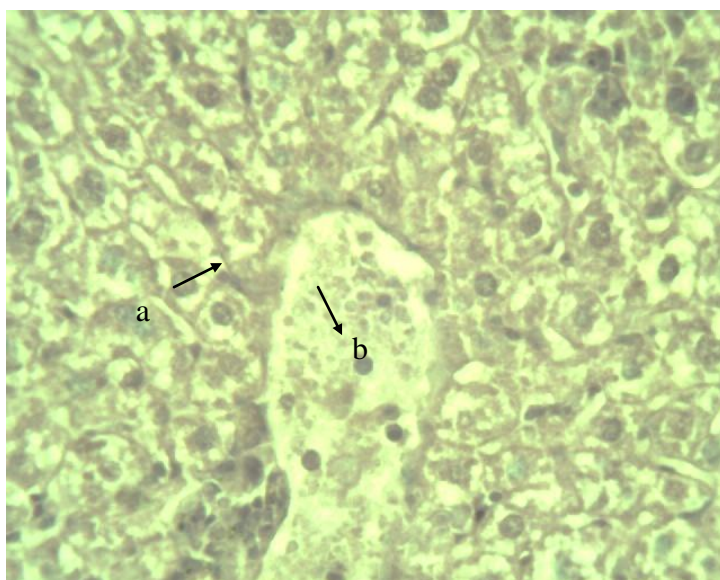


Fig. (2) alcohol group at 4th weeks of the experiment, section of the liver showed hydropic degeneration of the hepatocyte (a) with congested central vein (b)

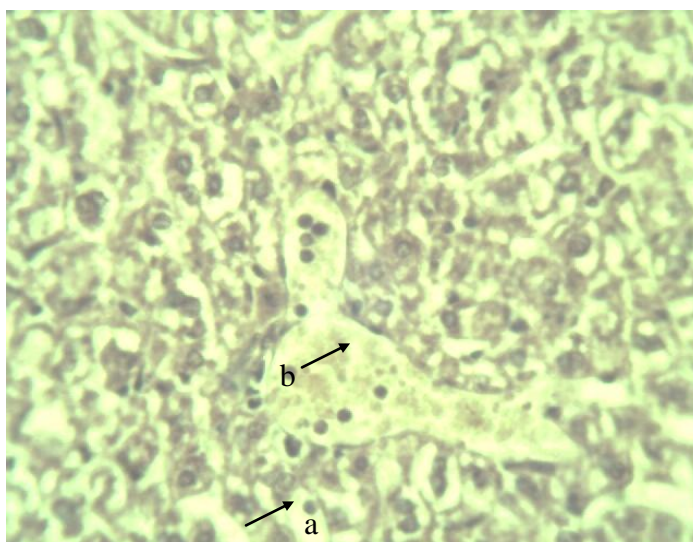


Fig.(3) alcohol group at 8th weeks of the experiment, section of the liver showed fatty change (a) with congested central vein (b)

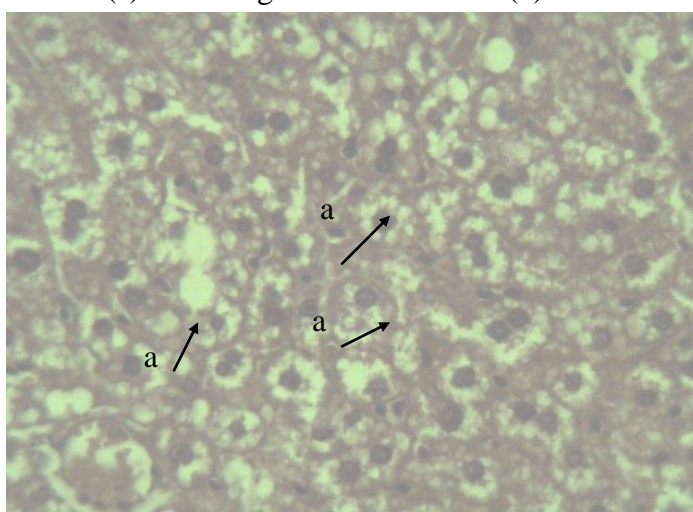


Fig. (4) alcohol group at 12 weeks of the experiment, section of the liver showed wide area of fatty change (a)

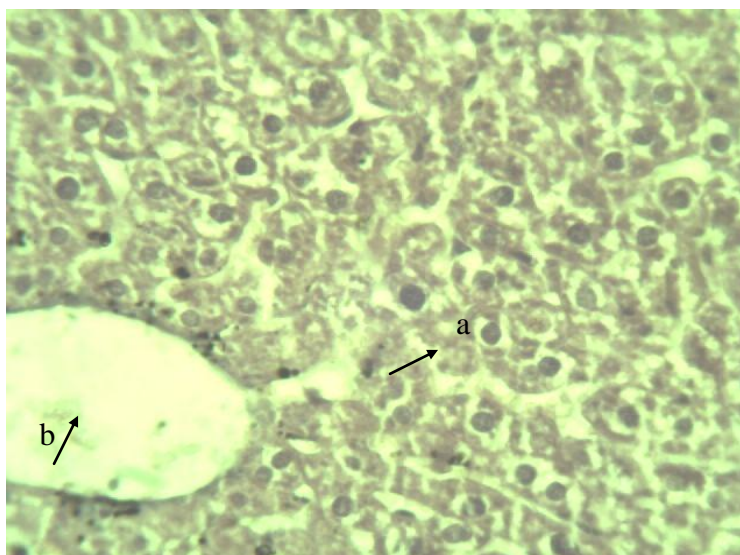


Fig. (5) alcohol +vitamin c at 4th weeks of the experiment, section of the liver showed dilatation of the sinusoids (a) , hepatic cell enlargement with central vein congestion (b)

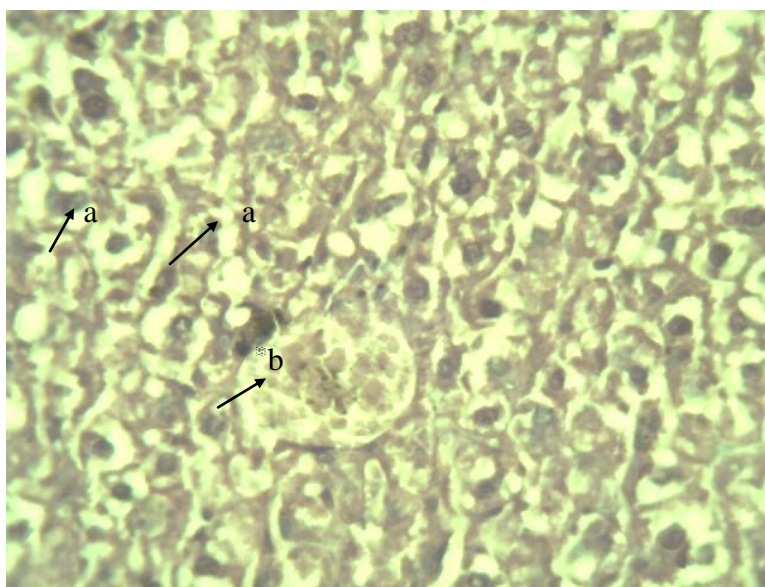


Fig. (6) alcohol +vitamin c at 12 weeks of experiment section of the liver showed fatty change (a) of the hepatocyte with congested central vein (b)

Discussion

Alcohol is absorbed from the small intestine, and the blood carries it directly in to the liver, where it becomes the preferred energy source. In the liver, alcohol converts to toxic chemicals, acetaldehyde (AcH), which trigger the production of powerful immune factors called cytokines. These molecules in large amounts can cause inflammation and tissue injury and are proving to be major culprits in

destructive process in the liver(6). AcH is particularly being researched because it plays a role in most actions of alcohol, including damaging effect on the liver that may lead to cirrhosis (9). The injured liver eventually is unable to breakdown fatty acids, compounds that makeup fat. Over time, then fat accumulates, further impairing the liver ability to absorb oxygen and increasing it susceptibility to injury

(6).This explain the pathological changes which seen in the first group which are given alcohol only. Recent studies suggest that mega dose of ascorbic acid in guinea pigs helps in the prevention of alcohol induced oxidative stress by enhancing the antioxidant capacity and also reducing lipid per oxidation products (10).Other study suggests that prior daily oral supplementation with ascorbic acid (50mg/kg/ b.w.) To benzanthrone administered guinea pigs resulted in marked improvement of histopathology and biochemical changes observed in liver of benzanthorn_ exposed animals. That ascorbic acid could attenuate the toxic manifestation of benzanthrone (11).Other study shown that the effect of a

combination of vitamin C 250mg/ kg, vitamin E 250 mg/kg and selenium 0.5 mg/kg, have a protective effect on the liver,because of their antioxidant activity against ethanol damage (12).Protection against acetaldehyde toxicity (anesthesia and lethality) was studied in rats by oral intubations of ascorbic acid showed moderate protection against anesthesia and marked protection against lethality (13).These studies supporting our finding that ascorbic acid could play important roles as protection against the chronic body insult of acetaldehyde arising from heavy drinking of alcohol that the second group (alcohol +vitamin c) show less pathological changes.

References

- 1.Palmer, M.D. (2004). Alcohol and Liver Disease /Hepatitis. Penguin Putnan. Amazon.com.
- 2.University Of Pittsburgh School of the Health Sciences.(2007).Alcohol and the Liver. American Liver Foundation New York, NY10038, 1-800-Go-Liver.
- 3.Fowkes, S.W.M. (1997). Living with Alcohol. Issue Of Drug News [v5n5].
- 4.Adam Healthcare Center. (2004). Cirrhosis. About.Com.
- 5.Buddy, T. (2007). Alcoholism and substance abuse. National Institute on Alcohol Abuse and Alcoholism.
- 6.American Liver Foundation. (2007). Alcohol Induced Liver Disease.
- 7.Kiefer, D. (2007).Alittle-Known fact: Alcohol is a carcinogen. Life Extension Foundation.
- 8.Charles,S.L. (2007). Relationships between nutrition, alcohol use and liver disease .Alcohol Research and Health High Beam Research ,Inc.
- 9.Deitrich,R.A.;Bludeau,P.;Baker,R.C.(2007).Brain ascorbic acid levels: Mice and Rats selected for differences in acute reactions to Ethanol. Oxford University Press. On Line ISSN1464-3502.
10. Suresh,M.V.;Sreeranjit,K.C.V.;Lalji,I. M. (1999).Impact of massive ascorbic acid supplementation on Alcohol induced oxidative stress in guinea pigs. Toxicalllett.22; 104(3):221-9.
11. Das,M.;Garg,K.;Singh,G.B.;AndKhanna,S.K. (2007). Attenuation of Benzanthrone toxicity by ascorbic acid in guinea pigs.On line ISSN 1096-0929.Society of Toxicology. Oxford University Press.
12. Ozdil, S.; Bolkent, S.; Yanardag,R. And Pirincci,P.A. (2007). Protective effects of ascorbic acid ,DL-a-tocopherol acetate ,and Sodium selenate on ethanol – induced liver damage of rats.Biochemical and Life Sciences. ISSN 0163- 4984. Springer link.
13. Sprince, H.;Parker,C.M.;Smith,G.G. and Gonzales,L.J. (2007). Protective action of ascorbic acid and sulfur compounds against acetaldehyde toxicity: Implication in alcoholism and smoking. Research Support ,U.S.Govt, NON-P.H.S.PMID:1171591.

سمية الكحول و دور فيتامين C مع سميته

رغد ناظم السعدي
سلوى صبر الربيعي
المعهد الطبي التقني/بغداد

إيمان هاشم الطائي
كلية الطب البيطري/جامعة بغداد

الخلاصة

لأجل دراسة تأثير سمية الكحول في الفئران و دور فيتامين C في هذه السمية، تم إعطاء المجموعة الأولى من الفئران الكحول فقط و المجموعة الثانية أعطيت الكحول مع فيتامين C لمدة ٩٠ يوما و المجموعة الثالثة تمثل مجموعة السيطرة. التغيرات النسيجية المرضية التي درست تمثلت بحدوث التنكس المائي وكبر حجم الخلايا الكبدية و التي اتجهت نحو التنكس الدهني. بالإضافة إلى تموت واسع في الخلايا الكبدية مع استمرار التجربة لمدة ٩٠ يوم. هذه التغيرات صاحبها حدوث الالتهاب و الذي بدأ منذ الأسبوع الثاني من التجربة و الذي تمثل بارتشاح بسيط للخلايا اللمفية اتبعه ارتشاح كبير لها في متن الكبد مكونة مناطق بؤرية و تكف الأوعية الدموية و كذلك انتشار الخلايا الليفية و زيادة قابلية الخلايا الكبدية على الانقسام. المجموعة الثانية أظهرت تغيرات مرضية أقل من المجموعة الأولى.