

Vitreous Floaters and Photopsia as Predictors of Vitreoretinal Pathology

Dr Ahmed Majeed Rasheed

Clinical Tutor - AlNahrain Medical College

Abstract

Background: Floaters and photopsia are common eye symptoms. This prospective study aims to detect the relative importance of floaters, photopsia, or both as predictors of vitreo-retinal pathology.

Material: 202 patients attending the outpatient clinic in Alkadhimya teaching hospital between 2008–2010 complaining of floaters, photopsia, or both were interrogated .starting with inquiry about the mode of presentation, then slit lamp examination of the anterior segment, and dilatation of the pupil by mydriacyl drops 0.5% and phenylphrine drops 10%, followed by 3 mirror examination of the vitreous and peripheral retina.

Results: 98 patients were male while 104 patients were female. 104 patients (51.49%) presented with floaters; 24 patients (11.88%) presented with photopsia; and 74 patients (36.63%) presented with both floaters and photopsia. 102 patients (50.50%) had posterior vitreous detachment (PVD) while 52 patients (25.74%) had synchysis, and 48 patients (23.76%) had normal vitreous. The highest percentage of PVD was in the age group 60 – 69 years and was 40 patients (39.21%). Regarding the mode of presentation, the highest percentage of PVD was in the group of patients presenting with both floaters and photopsia and was 46 patients (62.16%). The total number of retinal tear cases detected was 14; 8 of them were present in patients having PVD and presenting with floaters and photopsia, while 4 cases of retinal tears were detected in patients having PVD and presenting with floaters, and finally 2 retinal tear cases were detected in patients having PVD and presenting with photopsia. 12 eyes (85.71%) who had retinal tears had vitreous pigment granules, while 2 eyes with retinal tears (14.29%) did not have vitreous pigment granules.

Conclusion: the symptoms of floaters, photopsia, or both are an important predictors of vitreo- retinal pathology. A significant number of patients had PVD, and this was associated with retinal tears in a number of patients. Vitreous pigment granules in these patients were closely correlated with the presence of retinal tears. Careful examination of patients including 3 mirror contact lens examinations is mandatory.

Keywords: posterior vitreous detachment; synchysis (liquefied vitreous).

Introduction

Floaters and photopsia are common eye symptoms. Floaters represent the patient's awareness of the shadow of mobile vitreous opacity cast upon the retina, while photopsia is a common symptom of an abnormal relationship between the retina and vitreous. The light represent the cerebral awareness of the inertial physical traction on and excitation of the sensory retina by an abnormal vitreous which is usually collapsed or detached [1].

Floaters are extremely common in myopic patients and in people with syneresis(vitreous degeneration) , however, they are also commonly caused by small hemorrhages into the vitreous due to retinal tears or hemorrhagic diseases such as diabetic retinopathy, hypertensive retinopathy, leukemia, retinal vein occlusion, and other diseases [1]. One important cause of floaters is posterior vitreous detachment (PVD) which can exert traction on the posterior aspect of the vitreous base and predispose to retinal breaks at this location [2]. When patients

experience an acute PVD, they often note the onset of floaters. Up to half of patients who experience an acute PVD note the onset of photopsia in addition to the floaters [3,4,5].

The incidence of retinal tears after a symptomatic PVD (floaters and or photopsia) is approximately 15% [5,6,7,8,9]. Some authors have estimated that 1 in 70 eyes with retinal breaks goes on to develop rhegmatogenous retinal detachment [10,11]. The detection of retinal breaks is obviously very important in that prophylactic treatment in indicated cases can prevent rhegmatogenous retinal detachment.

Patients and methods

This prospective study was conducted from 2008 – 2010 in Alkadhimya teaching hospital on patients

Table 1. Distribution of patients according to gender, mode of presentation and vitreous changes.

	Frequency	Percentage	P value
Gender type			
Male	98	48.51%	0.673
Female	104	51.49%	
Total	202	100.00%	
Mode of presentation			
Floaters	104	51.49%	≤0.001
Photopsia	24	11.88%	
Both	74	36.63%	
Total	202	100.00%	
Vitreous changes			
PVD	102	50.50%	≤0.001
Synchysis	52	25.74%	
Normal	48	23.76%	
Total	202	100.00%	

attending the outpatient clinic. 202 patients complaining of floaters or photopsia or both were examined. Different age groups were included in the study and of both sexes. Patients were asked if they had migraine, epilepsy, recent brain concussion, or clomid tablet intake in case of females due to the fact that all these can cause photopsia. Patients with ocular trauma, previous intra ocular surgery, except uncomplicated cataract extraction with intra ocular lens implantation, uveitis, and diabetes with proliferative retinopathy were excluded from the study. Each eye was examined starting with visual acuity, refraction, anterior segment examination by the slit lamp , then pupil dilation with mydriacyl drops 1% and phenylphrine drops 10% followed by examination with indirect ophthalmoscopy and 3 mirror contact lens.

Results

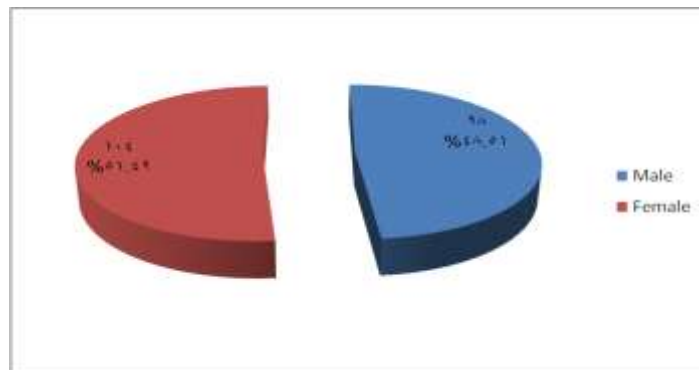


Figure 1. Distribution of patients according to gender

Table 1 shows the distribution of patients according to gender where 48.51% are males and 51.49% are females. It also shows that the most frequent mode of presentation is floaters (51.49%), while photopsia was the least (11.88%) .

Vitreous changes is also demonstrated in this table where 50.50% of patients had PVD while synchysis comprised 25.74% and the rest of the patients had normal vitreous. This is also demonstrated in figures 1,2, and 3.

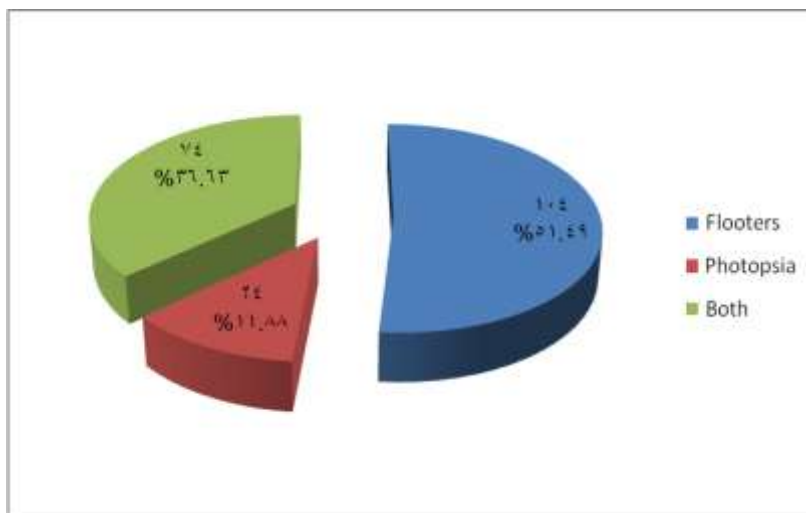


Figure 2. Distribution of patients according to modes of presentation

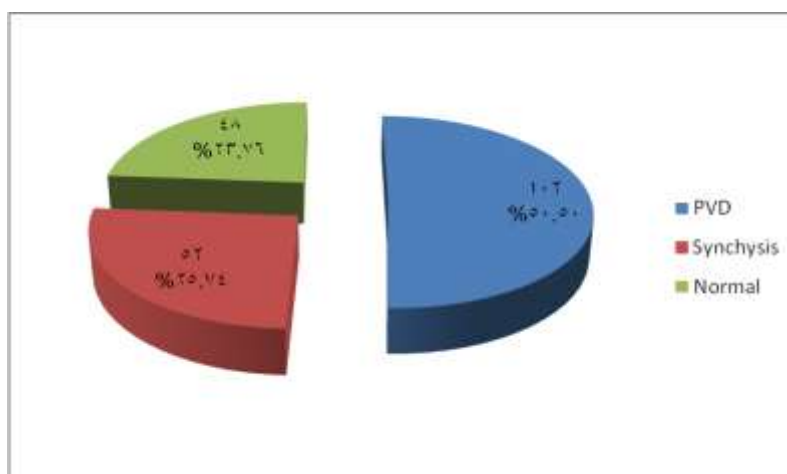


Figure 3. Classification of patients according to vitreous changes

Table 2. Distribution of PVD according to age group and gender

Age group	Gender type		
	Male	Female	Total
20-29 years	4	2	6
30-39 years	4	4	8
40-49 years	6	12	18
50-59 years	6	24	30
60-69 years	18	22	40
Total	38	64	102

P value =0.101

Table 2 shows that PVD tends to increase with age and that there is a statistically higher incidence of PVD in females as compared to male patients.

Table 3. Percentage of PVD according to modes of presentation

Mode of presentation	Total	Count	Percentage
Floater	104	42	40.38%
Photopsia	24	14	58.33%
Both	74	46	62.16%
Total	202	102	50.50%

P value =0.012

Table 3 shows that the highest percentage of PVD was in those presenting with both floaters and photopsia(62.16%) , while the

lowest percentage was among those patients presenting with floaters only (40.38%).

Table 4. Percentage of tears in patients with PVD according to their modes of presentation

Mode of presentation	No. of patients	No. of tear cases	Percentage
Floater + PVD	42	4	9.52%
Photopsia + PVD	14	2	14.29%
Floater + Photopsia + PVD	46	8	17.39%
Total	102	14	13.73%

P value = 0.562

Table 4 classifies patients with PVD into three groups according to mode of presentation and shows the percentage of retinal tears in each group. The highest percentage of tears was in the group of patients who presented with both floaters and photopsia (17.39%), while the lowest percentage was in the group of patients who presented with floaters alone (9.52%). Table 5 shows the incidence of vitreous hemorrhage and retinal tears in cases with PVD. 5.88% of patients had vitreous

hemorrhage while 94.12% had no hemorrhage. 4 eyes with vitreous hemorrhage had retinal tears (66%) while 10 eyes without vitreous hemorrhage had retinal tears (10.42%).

Table 6 and figure 4 show the percentage of vitreous pigment granules in patients with PVD and retinal tears. 12 eyes had vitreous pigment granules (85.71%), while only 2 eyes (14.29%) had no vitreous pigment granules.

Table 5 Incidence of vitreous hemorrhage and retinal tears in PVD cases

PVD cases		Retinal tear		
		With	Without	Total
Vitreous hemorrhage	With	4 (66%)	2 (34%)	6(5.88%)
	Without	10 (10.42%)	86 (89.58%)	96(94.12%)
	Total	14	88	102(100%)

P value ≤ 0.001 .

Table 6. Incidence of vitreous pigment granules in patients with PVD and retinal tears

No. of cases with PVD and retinal tears	Frequency	Percentage
With vitreous pigment granules	12	85.71%
Without vitreous pigment granules	2	14.29%
Total	14	100.00%

P <0.003

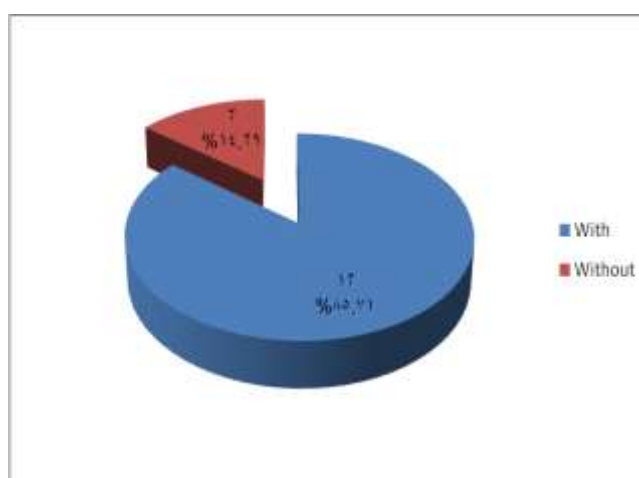


Figure 4. Incidence of vitreous pigment granules in patients with PVD and retinal tears

Discussion

In 1935, Moore described that light flashes are sometime a complaint resulting from PVD[17]. Wise has noted that the light flashes occurred in 50% of cases at the time of PVD and were usually vertical and temporally located. These are generally thought to result from vitreoretinal traction and thus are considered by most to signify a higher risk of retinal tears [18]. However, Voerhoeff suggested that the light flashes are actually due to the detached vitreous cortex impacting on the retina during eye movement [19].

In this study, the percentage of patients having PVD was 50.49% as compared to

the study conducted by Hikichi and Trempe in which it was 62.3% [9].

The incidence of PVD is shown to increase with age, the increment being more prominent in female patients. This is consistent with the result obtained by Wilkinson [2].

Our study shows that the highest prevalence of PVD was among patients presenting with both floaters and light flashes (62.1%), then comes patients presenting with light flashes alone(58.3%) , and finally those presenting with floaters alone(40.38%), a finding similar to that obtained by Hikichi and Trempe [9].

We have found that the highest prevalence of retinal tears as a complication of PVD occurs in the group of patients presenting with both floaters and light flashes (17.39%) and to a lesser

extent in the group of patients presenting with light flashes alone(14.28%), while the lowest prevalence of retinal tears was found in patients presenting as floaters alone(9.52%). This coincides with many other studies [13,14,15].

The risk of retinal tears in patients with acute symptomatic PVD without vitreous hemorrhage is 10.42% in our study as compared to other studies in which the figure is ranging from 8%- 46%[13] . This figure increases to 66% when there is vitreous hemorrhage as compared to other studies in which the figure ranges from 30% - 70% [13]. Therefore, PVD with vitreous hemorrhage serve as an important predictive sign for the presence of a retinal tear and therefore a careful search for this should be conducted.

It would be helpful to have a clinical sign or symptom to identify those patients with an acute PVD at high risk for retinal tear formation. It is found that pigment granules in the vitreous cavity is a useful clinical sign in identifying patients at high risk for retinal tears. In our study, 14 cases of retinal tears were found and in all but two cases there were vitreous pigment granules while no case without tear had vitreous pigment granules. Therefore, the sensitivity of this sign is 85.7% while its specificity is 100%. this is similar to the result obtained by Lightman and Brod[13].

Conclusion

1-The prompt vitreo-retinal examination of each patient who experience vitreous floaters or photopsia should be undertaken without delay using the 3 mirror contact lens.

2-Patients presenting with both floaters and light flashes have a higher risk to develop PVD and retinal tears , and the risk increases if there is vitreous hemorrhage or vitreous pigment granules.

References

1. Daniel Vaughan. General Ophthalmology 1989 : 153-159.
2. Wilkinson CP,Rice TA. Retinal detachment. St Louis, Mosby 1997;1163.
3. Byer NE. Natural history of posterior vitreous detachment with early management as the premier line of defense against retinal detachment. Ophthalmology 1994;101 : 1503.
4. Morse PH, Scheie HG, Aminlari A. light flashes as a clue to retinal disease. Arch Ophthalmol 1974; 91 : 179.
5. Tasman Ws. Posterior vitreous detachment and peripheral retinal breaks. Trans Am Acad Ophthalmol Otolaryngol 1968; 72: 217.
6. Murakami K, Jalkh AE, Avila MP et al. Vitreous floaters. Ophthalmology 1983;90:1271.
7. Tabotabo MD, Karp LA, Benson WE. Posterior vitreous detachment. Ann Ophthalmol 1980;12:59.
8. Jaffe N. complications of acute posterior vitreous detachment. Arch Ophthalmol 1968;79:568.
9. Hikichi T, Trempe CL. Relationship between floaters, light flashes, or both, and complications of posterior vitreous detachment. Amj Ophthalmol 1994;117: 593.
10. Byer NE . prognosis of asymptomatic retinal breaks . Arch Ophthalmol 1974;92 : 204.
11. Machemer R . the importance of fluid absorption , traction , intraocular currents , and chorioretinal scars in the therapy of rhegmatogenous retinal detachment . Am J Ophthalmol 1984;98 : 681.
12. Charles P Wilkinson. Michels retinal detachment. 1990 : 9-33 .
13. Lightman DA, Brod RD. Relationship between floaters, light flashes or both and complications of posterior vitreous detachment. Am J Ophthalmol 1994; 118(5): 683-4.
14. Boldrey EE. Relationship between floaters, light flashes or both and complications of posterior vitreous

-
- detachment . Am J Ophthalmol 1994; 118(5) : 682-3.
15. Boldrey EE . Risk of retinal tears in patients with vitreous floaters . Am J Ophthalmol 1983 ; 96 : 783-7.
16. Dayan MR . Flashes and floaters as predictors of vitreo-retinal pathology, is follow up necessary for PVD . Eye 1996; 10(4) : 456-8.
17. Moore RF . subjective lightning streak. Br J Ophthalmology 1983;90 : 1271.
18. Wise GN . Relationship of idiopathic preretinal macular fibrosis to posterior vitreous detachment. Amj Ophthalmology 1975;79 : 358.
19. Voerhoeff FH . are Moore s lightning streaks of serious importance ? Amj Ophthalmol 1956;41 : 837.